




Institute of
Medicinal Plants

Journal of Medicinal Plants

Journal homepage: www.jmp.ir



Research Article

A study on the hypocholesterolemic and potential hepatoprotective effects of ethanol extract of *Citrus aurantifolia* peel in rats fed a high-fat diet

Roma Sitio¹, Erlangga Galih Zulva Nugroho¹, Nur Balqis Maulydia^{2,*}

¹Department of Nursing, Polytechnic of Health Ministry of Health, Aceh Besar-23231, (Aceh) Indonesia

²Department of Pharmacy, Faculty of Mathematics and Natural Sciences, Universitas Syiah Kuala, Banda Aceh, Indonesia

ARTICLE INFO

Keywords:

C. aurantifolia
Lime peel
Cholesterol
Hypercholesterolemia
Cardiac and liver
function

ABSTRACT

Background: Current pharmacological therapies for hypercholesterolemia remain limited, particularly among individuals who exhibit intolerance to statins. *Citrus aurantifolia* (lime) has been proposed as a natural alternative with lipid-lowering properties that could help prevent cardiovascular complications. **Objective:** This study aimed to evaluate the effects of ethanol extract of lime peel (*Citrus aurantifolia*) on body weight, serum lipid profile, and histological changes in the liver and aorta of rats fed a high-fat diet. **Methods:** Lime peels were extracted by maceration using 96 % ethanol and administered to male Wistar rats (*Rattus norvegicus*) that had previously received a high-fat diet for 42 days. The experimental groups included a normal control, a high-fat diet control, a simvastatin-treated group, and three lime peel extract groups (50, 75, and 100 mg/kg body weight). The parameters observed included body weight, total cholesterol (TC), triglycerides (TG), low-density lipoprotein (LDL), high-density lipoprotein (HDL), and histological features of the liver and aorta. **Results:** High-fat feeding significantly increased body weight compared with the standard diet ($P < 0.001$). Treatment with lime peel extract and simvastatin significantly reduced body weight ($P < 0.05$), lowered TC and TG, and increased HDL relative to the untreated high-fat group. Simvastatin was more effective than the extract in reducing LDL ($P < 0.05$), while neither treatment significantly altered aortic morphology ($P > 0.05$). Histological analysis showed a higher proportion of normal hepatocytes in the lime peel-treated groups, particularly at 100 mg/kg ($P = 0.001$). **Conclusion:** Ethanol extract of *C. aurantifolia* peel demonstrated hypocholesterolemic effects and partial improvement in liver histology in rats fed a high-fat diet, suggesting its potential as a supportive natural therapy for hypercholesterolemia.

1. Introduction

Increasing trends of fast food, bad sanitation, and other kinds of fat-rich diet consumption

have been identified for the increasing risk of non-communicable diseases such as obesity and cardiovascular diseases [1, 2]. A worldwide

Abbreviations: TC, Total Cholesterol; LDL, Low-Density Lipoprotein; HDL, High-Density Lipoprotein; TG, Triglycerides; HFD, High-Fat Diet; *C. aurantifolia*, *Citrus aurantifolia*

*Corresponding author: nurbalqis.maulydia@usk.ac.id

doi: [10.66224/jmp.24.96.83](https://doi.org/10.66224/jmp.24.96.83)

Received 21 June 2025; Received in revised form 10 October 2025; Accepted 19 November 2025

© 2023. Open access. This article is distributed under the terms of the Creative Commons Attribution-NonCommercial 4.0 International License (<https://creativecommons.org/licenses/by-nc/4.0/>)

study revealed a significant association between dietary fat intakes with higher risk of coronary heart disease, particularly those with higher compositions of trans fats and saturated fats [3]. Consumption of these fats could promote fat deposition within the artery, particularly in the form of cholesterol-rich substances like low-density lipoprotein (LDL) [4]. Thereafter, changes on the accumulated LDL molecules could occur through oxidation and glycation, which further mediates their phagocytosis by macrophages. This cascade of events leads to the formation of atherosclerotic plaque, a hardened and narrowed lesion within the arterial intima-media consisting of cholesterol, cellular debris, calcium deposits, and inflammatory cells [5]. The presence of atherosclerosis has been suggested as the primary cause of myocardial infarction. Moreover, elevated plasma cholesterol levels (hypercholesterolemia), especially triglyceride (TG) and LDL, have been found to increase the risk of non-communicable diseases such as cancer, diabetes mellitus, and obesity [6].

Statin therapy is most widely prescribed to treat hypercholesterolemia, particularly to reduce the risks of atherosclerosis and cardiovascular diseases [7, 8]. However, the therapy is challenging in some individuals with low statin tolerance, resulting in suboptimal reduction of LDL cholesterol, thereby posing them to recurrent atherosclerotic cardiovascular disease (ASCVD) [9-11]. Moreover, adverse effects of statins include myopathy and rhabdomyolysis [12]. In cases when the efficacy is suboptimal, including that deriving from resistance development, increasing the intake dose of statin is necessary [13, 14]. To provide efficacious and safe treatment, looking for other alternatives, especially from natural products, is crucial [15].

Plant-based natural products are gaining traction in research due to their promising efficacy and safety [16, 17]. Natural products have been reported to possess a wide range of biological activities with distinct chemical structure, yet similar characteristics of those synthetic [18, 19]. The strong anti-proliferative effects of tamarind leaf on cancer cells are due to the apigenin compound [20]. Among the investigated herbal medicines, lime (*Citrus aurantifolia*) stands out as the promising source of bioactive phytochemicals [21, 22]. In previous research, lime peel (LP) extract is found to be a potent analgesic and anti-inflammatory agent [23]. Pharmacological activities of LP are thought to be derived from its secondary metabolites, such as alkaloids, terpenes, phenolics, and flavonoids. Specifically, plants of this genus are major sources for coumarins, limonoids, and carotenoids that have been witnessed to exert a variety of biological functions [24].

Herein, lime peel extract was investigated for its efficacy in reducing cholesterol levels using an animal model. Previous studies have reported that the ethanolic extract of *Citrus aurantifolia* exhibits potential antihypercholesterolemic activity based on in silico analysis [25]. In addition, orange peel (*Citrus × sinensis*) has been shown to exert protective and therapeutic effects on the liver by inhibiting the release of inflammatory cytokines and improving gut microbiota composition in rat models [26], while citrus peel from *Citrus medica* was reported to reduce free fatty acid levels and increase fecal triglyceride excretion [27]. Plants belonging to the same genus are known to share similar phytochemical profiles, including flavonoids, phenolic compounds, saponins, tannins, and terpenoids, which are associated with lipid-modulating activity [28]. Therefore,

the purpose of the present study was to evaluate the effects of ethanolic extract of *C. aurantifolia* peel on plasma lipid levels, body weight, and histological changes in the liver and aorta in a rat model of hypercholesterolemia.

2. Materials and methods

2.1. Plant Specimen

Plant specimens were collected from Aceh Besar Regency, Aceh, Indonesia. Taxonomical identification was carried out at the National Research and Innovation Agency-Jakarta (B-2035/II.6.2/IR.01.02/8/2023). The specimen was identified as *C. aurantifolia* (Christm.) Swingle.

2.2. Preparation of lime peel extract

Peels of *C. aurantifolia* were extracted by means of maceration with ethanol 96 % as the solvent. Initially, the peels were crushed into fine powder and air-dried at room temperature. The powder was submerged in a sealed glass container containing ethanol 96 % for three days, where daily periodical stirring was performed. Thereafter, the macerate was collected using Whatman No. 1 filter paper for filtration. The remaining pulp was re-macerated two more times using a similar protocol. The macerate was evaporated using a rotary evaporator until an extract paste was formed [29].

2.3. Animal and randomization

Thirty healthy male Wistar rats (*Rattus norvegicus*) were obtained from the Faculty of Veterinary Medicine, Universitas Syiah Kuala. The animals were 1.5–2 months old and weighed between 90 and 105 g at the start of the study. All rats were acclimatized for seven days under standard laboratory conditions with a natural light–dark cycle and free access to food and water. After acclimatization, the rats were

randomly assigned into six groups (n = 5 per group) using web-based randomization software (<https://www.randomizer.org/>). This research has received ethical approval from the Health Research Ethics Commission of the Faculty of Veterinary Medicine, Universitas Syiah Kuala, Number 216/KEPH/V/2023.

2.4. Intervention

The experimental design of this study is illustrated in Figure 1. Except for the healthy control group, all rats were fed high-fat diet ad libitum for the first 42 days to induce hypercholesterolemia. Thereafter, the high-fat diet group continued with standard feed without treatment, while the remaining groups received either simvastatin or lime peel (LP) extract for 28 days. Rats in the simvastatin group were administered simvastatin at a dose of 0.18 mg per 200 g body weight (equivalent to 9 mg/kg), which was selected based on previous studies demonstrating effective lipid-lowering activity in rats without causing hepatic stress. Rats assigned to the LP50, LP75, and LP100 groups received ethanol extract of *C. aurantifolia* peel at doses of 50, 75, and 100 mg/kg body weight, respectively. These doses were chosen with reference to earlier reports on citrus peel extracts showing biological efficacy within this range and to explore a potential dose–response relationship. Simvastatin and LP extract were administered once daily via an oral gavage (nasogastric) tube for 28 days following the high-fat feeding period. The control group received standard feed and distilled water only throughout the experiment. On day 71, all rats were anesthetized with ketamine (100 mg/kg) and xylazine (20 mg/kg) prior to euthanasia. Blood samples (2 ml) were collected directly from the heart for biochemical analysis, and internal organs were subsequently harvested for histological examination.

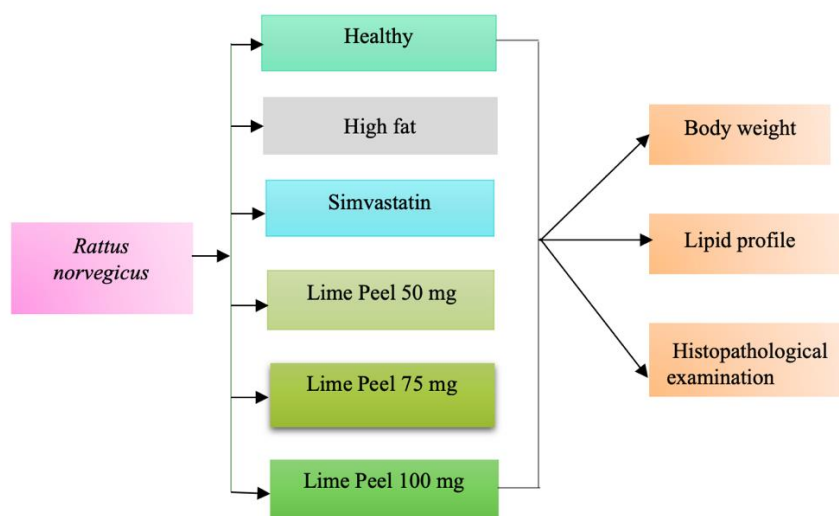


Fig. 1. Research design of this study

2.5. Body weight and lipid profile

Body weights were measured both before and after the treatment phase (day 43 and day 71, respectively). Serum total cholesterol (TC), triglyceride (TG), high-density lipoprotein cholesterol (HDL-c), and low-density lipoprotein cholesterol (LDL-c) were determined using Selectra Pro S (Indonesia) following the guideline from the manufacturer.

2.6. Histopathological examination

Rat hearts and aortas were preserved for 24 hours in a 10 % formalin-neutral buffer solution. The tissues were then rinsed with xylol solution and dried with alcohol solutions of various concentrations before being embedded in paraffin blocks. Thereafter, tissues were sliced to 4- μ m thickness using a rotary microtome, placed on a glass slide, and stained with eosin and haematoxylin, as suggested previously [23]. The microscopic observations were carried out under 400x magnification.

2.7. Data analysis

Data following a Gaussian distribution were expressed as mean \pm standard deviation,

whereas non-normally distributed data were presented as median (interquartile range). Normality of data distribution was evaluated using the Shapiro–Wilk test. Changes in body weight between day 43 and day 71 within the same group were analyzed using a paired Student’s t-test, while comparisons among different groups were performed using one-way ANOVA followed by Duncan’s post hoc test. Statistical analyses were conducted using IBM SPSS Statistics version 26.0 (IBM Corp., Armonk, NY, USA). Statistical significance was defined as $P < 0.05$.

3. Results

3.1. Effect on body weight

High-fat feeding led to a significant increase in body weight compared with standard feeding by day 43 ($P < 0.001$, Figure 2). Rats receiving a standard diet had a median body weight of 188 g (168 – 191 g), whereas those fed a high-fat diet reached 265 g (245 – 284 g). Following treatment, both simvastatin and lime peel (LP) extract significantly reduced body weight compared with the untreated high-fat diet group ($P < 0.05$). Among the treated groups, the effect

of simvastatin was comparable to that of the highest dose of LP extract, with both showing greater reductions than lower LP doses.

However, body weights in all treatment groups remained significantly higher than in the standard-diet control group ($P < 0.05$, Figure 3).

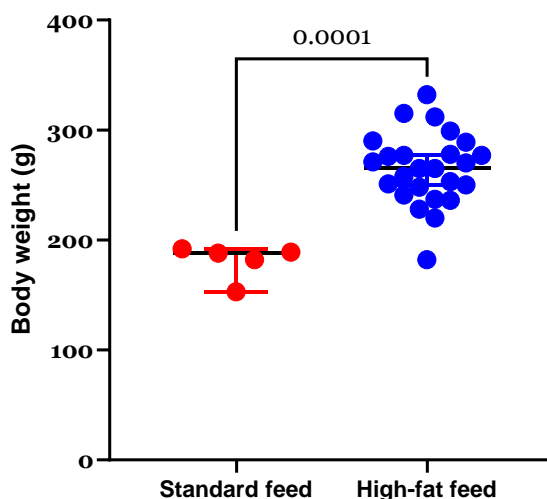


Fig. 2. Effect of high-fat feeding on the rats' body weight. Statistical significance $P < 0.01$

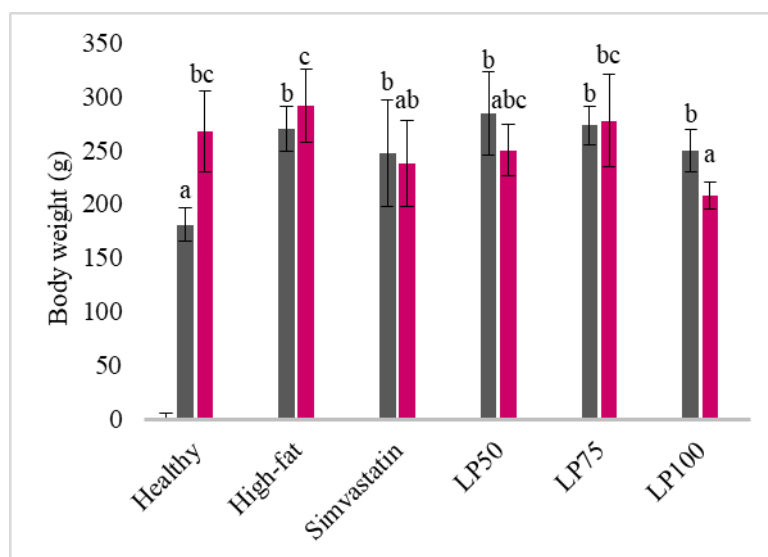


Fig. 3. Effect of standard diet, high-fat diet, simvastatin, and lime peel (LP) extract (50, 75, and 100 mg/l) on rat body weight. Data are presented as mean \pm SD. Bars with different letters (a, b, c) indicate statistically significant differences between groups at $P < 0.05$ according to one-way ANOVA followed by Duncan's post hoc test. Groups sharing at least one common letter are not significantly different.

3.2. Effect on lipid profile

Serum TC, TG, LDL, and HDL levels after treatment are presented in Figure 4. Both lime peel ethanol extract and simvastatin significantly reduced TC and TG levels

compared with the untreated high-fat diet group ($P < 0.05$). Administration of simvastatin also markedly reduced LDL and increased HDL levels, consistent with its known pharmacological effects ($P < 0.05$). In contrast,

treatment with lime peel extract lowered TC and TG levels but did not significantly alter LDL compared with the high-fat control group ($P > 0.05$). Interestingly, serum HDL levels decreased in a dose-dependent manner

following LP extract administration, with mean values of 95 ± 29 , 89 ± 26 , and 71 ± 25 mg/dl observed at 50, 75, and 100 mg/l doses, respectively.

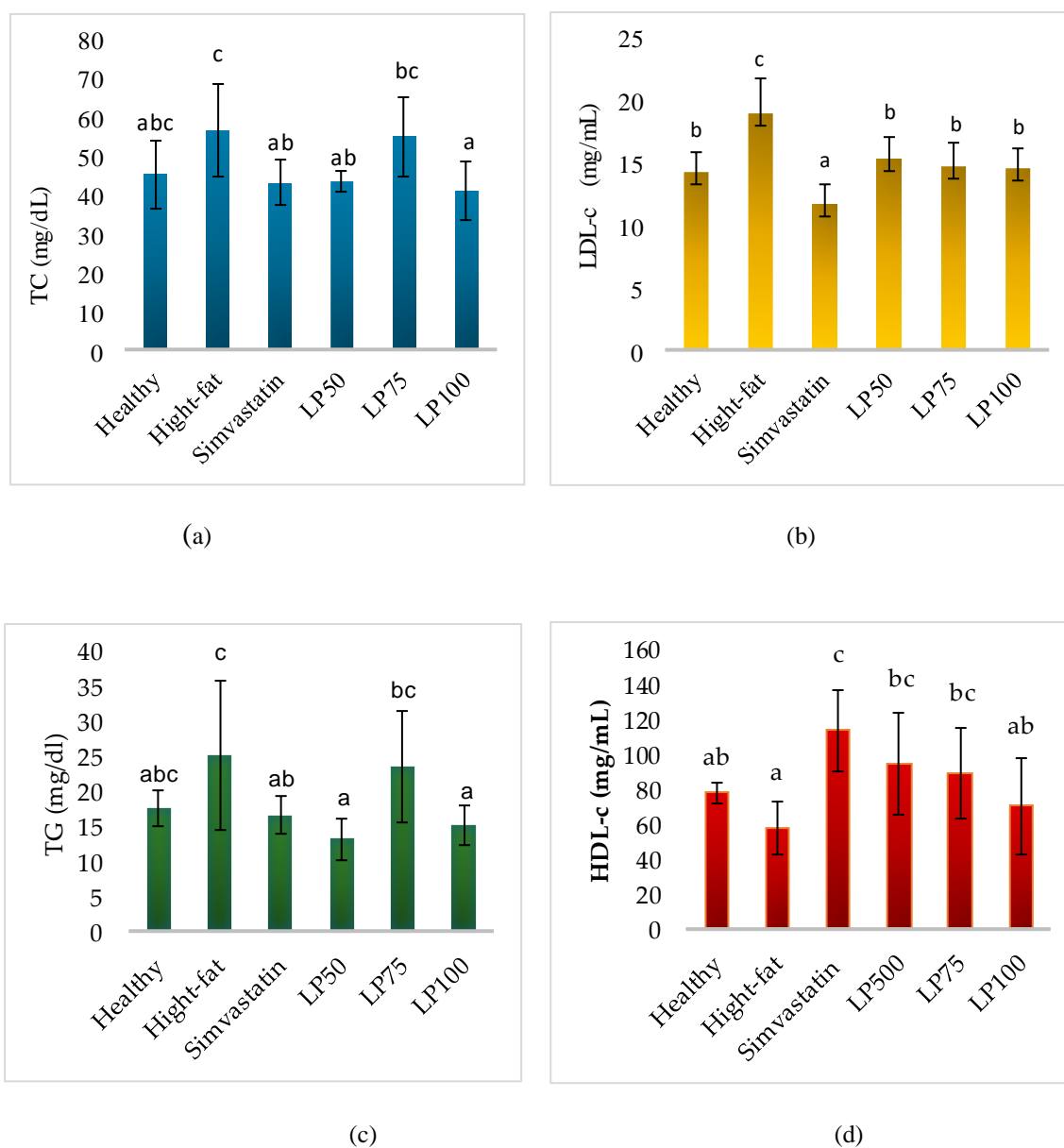


Fig. 4. Effect of LP extract on total cholesterol (TC) (a), low-density lipoprotein (LDL) (b), triglycerides (TG) (c), and high-density lipoprotein (HDL) (d). Data are presented as mean \pm SD. Different letters indicate statistically significant differences among groups ($P < 0.05$)

3.3. Effect on histological characteristics of aorta

Effects of treatment on aortic wall thickness and lumen diameter are summarized in Figure 5. The thickness of the aortic wall, encompassing both the intima and media layers, ranged from $95 \pm 15 \mu\text{m}$ in the high-fat group to $115 \pm 15 \mu\text{m}$ in the simvastatin group. Corresponding histological images are shown in Figure 6. Lumen diameter values ranged from $1355 \mu\text{m}$ ($1083 - 1618 \mu\text{m}$) in the LP75 group to $1676 \mu\text{m}$ ($1541 - 1694 \mu\text{m}$) in the high-fat group. However, statistical analysis indicated no significant differences in either aortic wall thickness or lumen diameter among the groups ($P > 0.05$). Although not statistically significant, histological examination suggested that high-fat feeding increased aortic wall thickness relative to the healthy control. Simvastatin treatment appeared to reduce this thickening, while LP extract showed a dose-related tendency toward improvement. Among the extract-treated groups, LP100 demonstrated the greatest reduction in wall thickness, approximating the

effect seen with simvastatin. Nevertheless, none of the treatments fully restored aortic wall morphology to the level observed in the healthy control.

3.4. Effect on histological characteristics of hepatocytes

Numbers of normal and necrotic hepatocytes post-treatment are presented in Figure 7. The histological images for the rats' liver with a focus on hepatocytes are presented in Figure 8. A significantly higher number of normal hepatocytes was obtained in group LP100 as compared to healthy ($P = 0.002$) and high-fat controls ($P = 0.002$). The increase in normal hepatocytes among groups receiving LP extract was dose dependent, where the cell numbers were 15 ± 1.2 , 17 ± 1.7 , and 19 ± 2.5 for groups LP50, LP75, and LP100, respectively. Numbers of necrotic hepatocytes ranged from 24 ± 2.5 to 29 ± 1.6 in groups LP100 and LP50, respectively. No significant difference was observed among all groups for the number of necrotic hepatocytes ($P > 0.05$).

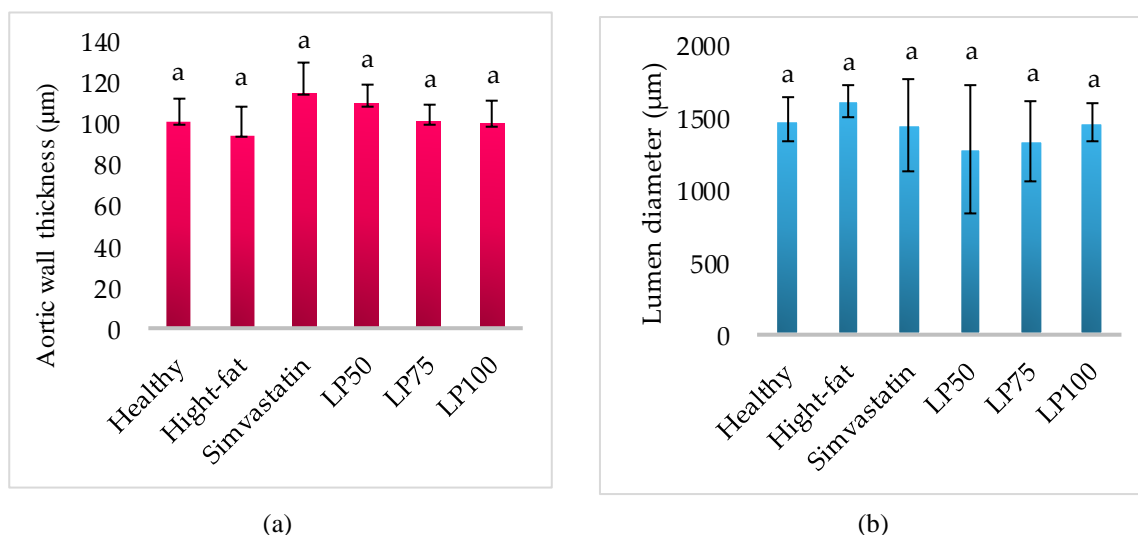


Fig. 5. Effect of PL extract on aortic wall thickness (a) and lumen diameter (b). The same letter indicates non-significant value ($P > 0.05$).

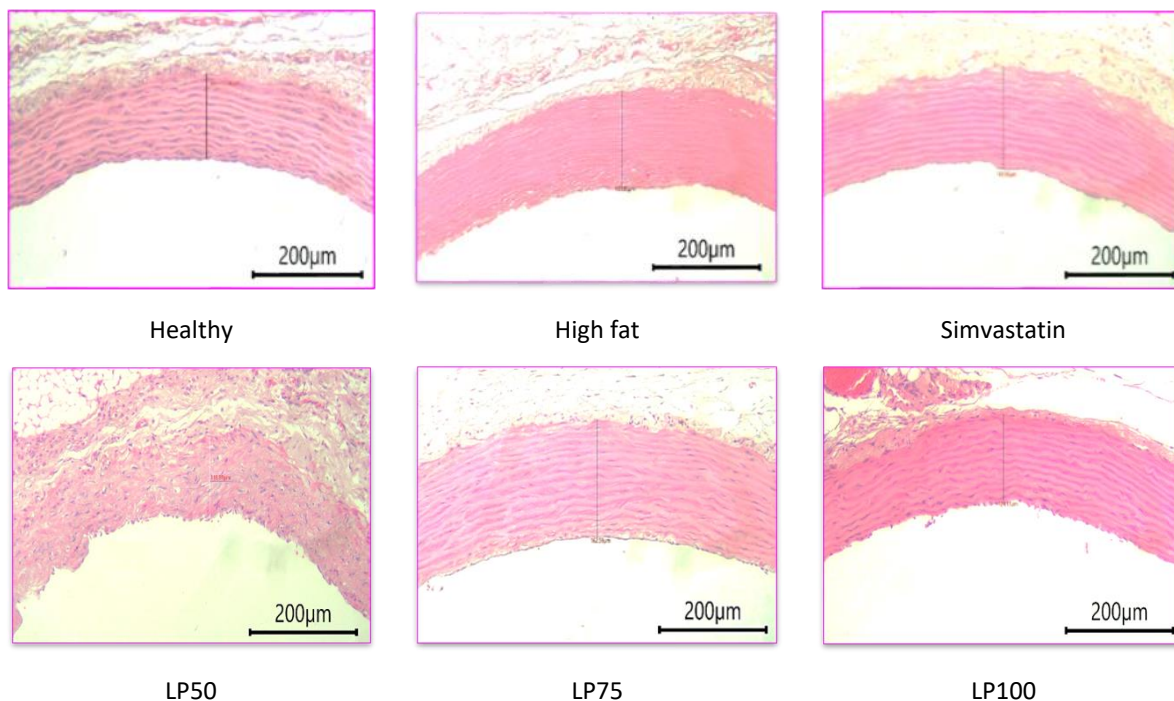


Fig. 6. Histological images of the aortic wall in rats from each group (H&E staining, 200 µm scale). The high-fat diet group shows thicker aortic walls compared with the healthy control. Simvastatin and lime peel (LP) extract treatments (50, 75, and 100 mg/l) showed variable wall thickness, with LP100 and simvastatin groups demonstrating thinner walls relative to the high-fat group. Vertical lines indicate the measured aortic wall thickness.

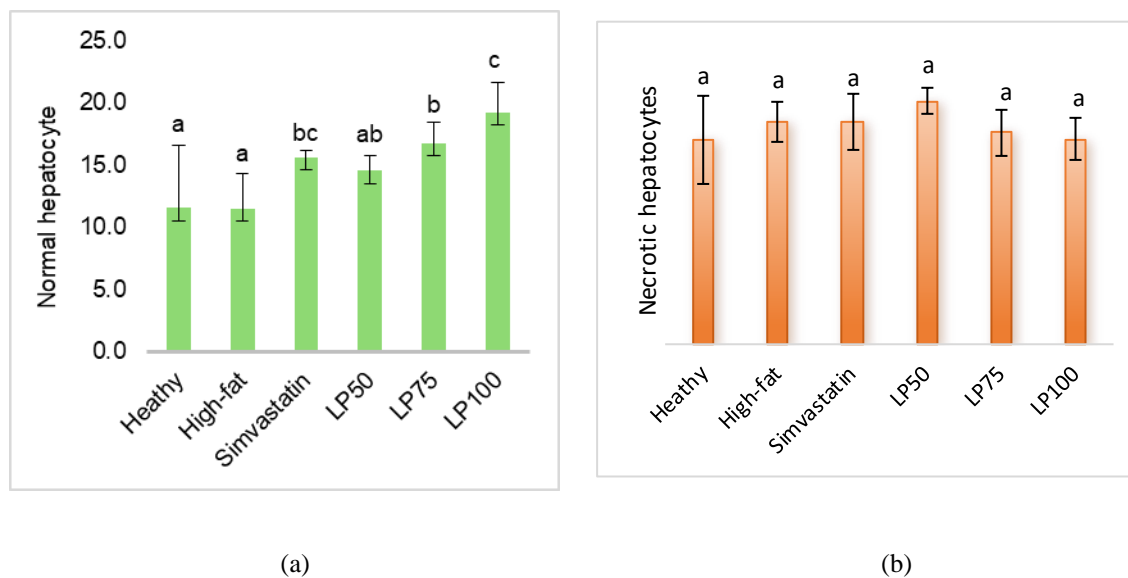


Fig. 7. Effect of LP extract on the number of normal hepatocytes (a) and the number of necrotic hepatocytes (b). The same letter indicates non-significant value ($P > 0.05$).

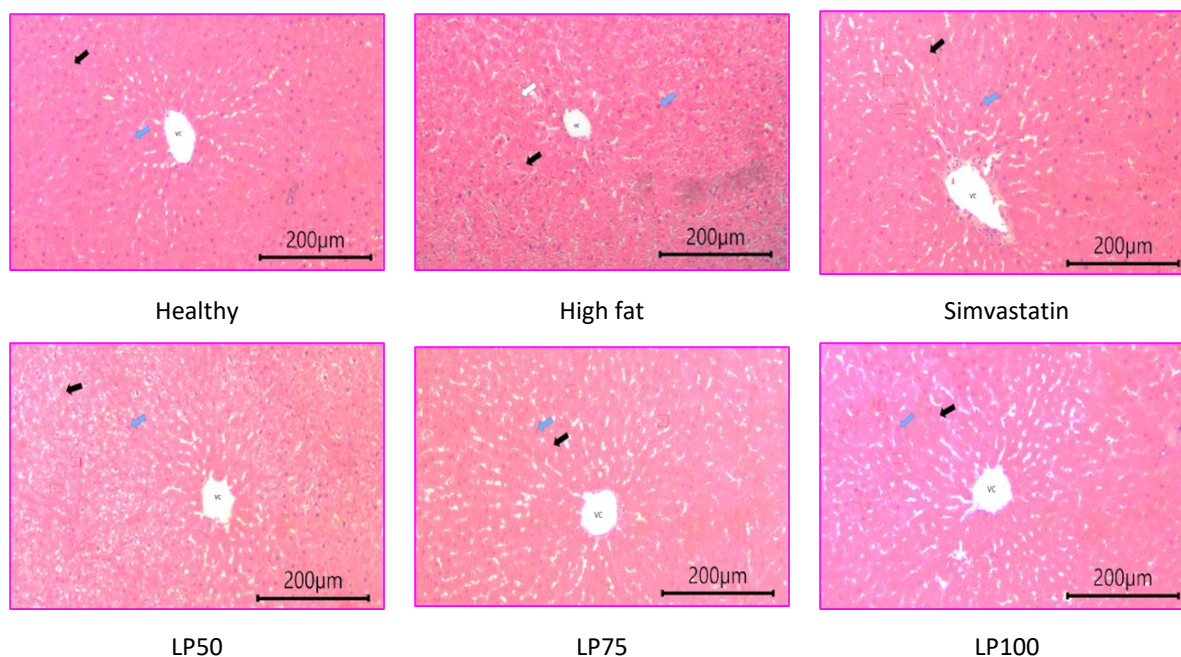


Fig. 8. Histological images depicting rats' normal (blue arrow) and necrotic hepatocytes (black arrow).

4. Discussion

In the present study, rats receiving high-fat diets experienced a significant increase of body weight as compared to their standard-feed counterpart. Obesity and overweight have been shown to be associated with cardiovascular diseases such as arteriosclerosis, stroke, and myocardial infarction, which are closely related to lipoprotein metabolism [30]. Body weight of rats significantly increased after being fed a high-cholesterol diet for 8 weeks [31]. Weight gain can also increase total cholesterol levels, LDL, TG, and reduce HDL [32].

Secondary metabolites in plants can inhibit carbohydrate- and lipid metabolizing enzymes such as α -glucosidase, α -amylase, and various lipases present in the gastrointestinal tract. Amylase and glucosidase are the main enzymes responsible for digesting carbohydrates and resulting in the release of glucose through glucose transporters [33]. Synthesis of lipids and fatty acids from glucose and esterification of lipids into TG are then stored in adipose

tissue, leading to obesity [34]. The group of rats that received the extract experienced the same weight loss or was not different from the group of rats that received simvastatin therapy. This proves that phenolic compounds, flavonoids, tannins, saponins, and terpenoids contained in lime peel extract have the potential to reduce fat in the body and contribute to the weight loss of rats [25].

Our findings suggested that high-fat diets improved the LDL-c. These results are in contrast to the results of a previous study in which rats fed a high-fat diet showed a significant increase in total cholesterol, alanine aminotransferase (ALT), TG, aspartate aminotransferase (AST), and lipid peroxidation [35]. The aqueous extract of palm fruit can damage kidney function, affect the lipid profile, and alter serum electrolyte concentrations [36]. Simvastatin intake can reduce LDL-c levels. HMG-CoA reductase inhibitors (statins) are lipid-lowering drugs used in the primary and secondary prevention of coronary heart disease

[37]. Simvastatin works by inhibiting hydroxymethylglutaryl-coenzyme A reductase, which subsequently lowers cholesterol and triglycerides while increasing high-density lipoprotein [38, 39].

From the histopathological analysis in the present study, aortic wall thickness and lumen diameter (atherosclerosis indicators) were similar across all groups. Administration of LP extract was associated with an increase in the number of normal hepatocytes, although the number of necrotic hepatocytes remained unchanged. This finding may suggest a potential protective influence on liver histology, but it does not provide sufficient evidence to confirm hepatoprotective activity. In a previous study, hesperidin isolated from citrus extract was regarded as a hepatoprotective agent by promoting nuclear factor-like 2 and heme oxygenase 1 [40]. The reduction of cholesterol in the liver is known to stimulate HMG-CoA reductase enzymatic activity, thereby enhancing endogenous cholesterol synthesis [41].

The amount of bile acids in the enterohepatic system will decrease as a result of this enhanced bile acid excretion through the stool. By drawing more cholesterol into the blood, the liver will create bile acids, which will cause the blood's cholesterol levels to drop [42]. The liver is essential for survival and plays a role in almost every metabolic function of the body. Therefore, it is highly susceptible to residual metabolites, toxic substances, and injuries caused by circulatory disorders [43].

In a different study citrus extract was found to prevent hepatocellular injury attributed to its antioxidant properties [44]. Polyphenols hold a key role in managing obesity and lipid disorder as the disease often induce hepatocellular injury through oxidative stress which eventually lead to the formation of tumor [45]. Aqueous garlic

extract, vitamin C, and vitamin E-Se may be useful substances for lessening the hepatotoxicity caused by lead acetate [46]. Previously, *C. aurantifolia*-derived products were suggested as potential anti-cholesterol agent [21, 22]. Challenges in preparing in vivo dyslipidemia model have been recognized in previous studies [47, 48]. It is imperative that future research should be performed using better animal model, either by expanding the study period or using an inducing agent such as D-galactose [49].

5. Conclusion

A high-cholesterol diet significantly increased body weight in rats, confirming the successful induction of hypercholesterolemia. Administration of ethanol extract of *Citrus aurantifolia* peel effectively reduced body weight and improved serum lipid profiles, showing comparable efficacy to simvastatin in lowering total cholesterol and triglycerides and elevating HDL levels. Simvastatin, however, remained more effective in reducing LDL concentrations. Neither lime peel extract nor simvastatin produced significant changes in aortic wall thickness, lumen diameter, or necrotic hepatocyte counts. Nevertheless, both treatments increased the number of normal hepatocytes, suggesting a potential protective influence on liver histology. Overall, the findings indicate that lime peel extract, a natural product from Aceh Province, exhibits promising hypocholesterolemic activity and may serve as a supportive natural remedy for managing hypercholesterolemia. Further studies incorporating biochemical assays and longer observation periods are warranted to confirm its hepatoprotective potential and elucidate the underlying mechanisms.

Author contributions

RS: Supervision, Conceptualization, Resources; Project administration, Methodology, Formal analysis, Original writing; EGZN: Data curation, Formal analysis, Writing – review & revision; NBM: Data curation, Formal analysis, Software, Writing – review & revision.

Conflicts of interest

No conflicts of interest in this research.

References

1. Tareq AM, Mahmud MH, Billah MM, Hasan MN, Jahan S, Hossain MM, Chy FJ, Uddin MG, Emran TB and Sayeed MA. Fast-food and obesity: Status among the young adult population in Bangladesh. *Narra J.* 2022; 2(3): 1-7. doi: 10.52225/narra.v2i3.86.
2. Sidiq R, Ritawati, Sitio R and Hajar S. The risk of pneumonia among toddlers in Lambatee, Aceh. *Kesmas.* 2016; 11(2): 69-73. doi: 10.21109/kesmas.v11i2.1044.
3. Wang Q, Afshin A, Yakoob MY, Singh GM, Rehm CD, Khatibzadeh S, Micha R, Shi P and Mozaffarian D. Impact of nonoptimal intakes of saturated, polyunsaturated, and trans fat on global burdens of coronary heart disease. *J. Am. Heart Assoc.* 2016; 5(1): 1-23. doi: 10.1161/JAHA.115.002891.
4. Malekmohammad K, Bezsonov EE and Rafieian-Kopaei M. Role of lipid accumulation and inflammation in atherosclerosis: Focus on molecular and cellular mechanisms. *Front. Cardiovasc. Med.* 2021; 8(September): 1-16. doi: 10.3389/fcvm.2021.707529.
5. Yao Y, Liu F, Wang Y and Liu Z. Lipid levels and risk of new-onset atrial fibrillation: A systematic review and dose-response meta-analysis. *Clin. Cardiol.* 2020; 43(9): 935-43. doi: 10.1002/clc.23430.

Acknowledgments

The authors would like to thank the Faculty of Mathematics and Natural Sciences and the Faculty of Veterinary Medicine, Universitas Syiah Kuala, for providing the laboratory to conduct this research.

Ethical committee approval

This research has received ethical approval from the Health Research Ethics Commission of the Faculty of Veterinary Medicine, Universitas Syiah Kuala, Number 216/KEPH/V/2023.

6. Schwingshackl L, Heseker H, Kiesswetter E and Koletzko B. Reprint of: Dietary fat and fatty foods in the prevention of non-communicable diseases: A review of the evidence. *Trends Food Sci. Technol.* 2022; 130: 20-31. doi: 10.1016/j.tifs.2022.10.011.
7. Reston JT, Buel A, Donahue MP, Neubauer B, Vagichev E and McShea K. Interventions to improve statin tolerance and adherence in patients at risk for cardiovascular disease: A systematic review for the 2020 U.S. department of veterans affairs and U.S. department of defense guidelines for management of dyslipidemia. *Ann. Intern. Med.* 2020; 173(10): 806-812. doi: 10.7326/M20-4680.
8. Virani SS, Smith SC, Stone NJ and Grundy SM. Secondary prevention for Atherosclerotic cardiovascular disease: Comparing recent US and European guidelines on Dyslipidemia. *Circulation.* 2020; 141(14): doi: 1121-3. 10.1161/CIRCULATIONAHA.119.044282.
9. Rea F, Biffi A, Ronco R, Franchi M, Cammarota S, Citarella A, Conti V, Filippelli A, Sellitto C and Corrao G. Cardiovascular outcomes and mortality associated with discontinuing statins in older patients receiving polypharmacy. *JAMA Network Open.* 2021;

- 4(6): 1-13. doi: 10.1001/ jamanetworkopen. 2021.13186.
- 10.** Laurent C, Prieto-González S, Belnou P, Carrat F, Fain O, Dellal A, Cid MC, Hernández-Rodríguez J and Mekinian A. Prevalence of cardiovascular risk factors, the use of statins and of aspirin in Takayasu Arteritis. *Scientific Reports*. 2021; 11(1): 14404. doi: 10.1038/s41598-021-93416-0.
- 11.** Meza-Contreras A, Wenczenovicz C, Ruiz-Arellanos K, Vesely EAKK, Mogollon R and Montori VM. Statin intolerance management: A systematic review. *Endocrine*. 2023; 79(3): 430-436. doi: 10.1007/s12020-022-03263-w.
- 12.** Montastruc JL. Rhabdomyolysis and statins: A pharmacovigilance comparative study between statins. *Br. J. Clin. Pharmacol*. 2023; 89(8): 2636-8. doi: 10.1111/bcp.15757.
- 13.** García-Fernández-Bravo I, Torres-Do-Rego A, López-Farré A, Galeano-Valle F, Demelo-Rodríguez P and Alvarez-Sala-Walther LA. Undertreatment or overtreatment with Statins: Where are we? *Front. Cardiovasc. Med*. 2022; 9: 80871. doi: 10.3389/fcvm.2022.808712.
- 14.** Sun L, Wolska A, Amar M, Zubirán R and Remaley AT. Approach to the patient with a suboptimal Statin response: Causes and algorithm for clinical management. *J. Clin. Endocrinol. Metab*. 2023; 108(9): 2424-34. doi: 10.1210/clinem/dgad153.
- 15.** Maulydia NB, Khairan K, Tallei TE and Idroes R. Metabolomic profiling and anti-inflammatory activity of *Blumea balsamifera*: Insights from in silico and in vitro studies. *Pharmacia*. 2025; 72: 1-15. doi: 10.3897/pharmacia.72.e146995.
- 16.** Hassanein MMM, Abdel-Razek AG, Al-Amrousi EF and Badr AN. Application of lime peel oil composite nanoemulsion to prevent toxigenic fungi in nuts. *Heliyon*. 2023; 9(8): e18620. doi: 10.1016/j.heliyon.2023.e18620.
- 17.** Khutami C, Sumiwi SA, Khairul Ikram NK and Muchtaridi M. The Effects of antioxidants from natural products on Obesity, Dyslipidemia, Diabetes and their molecular Signaling mechanism. *Int. J. Mol. Sci*. 2022; 23(4): 1-23. doi: 10.3390/ijms23042056.
- 18.** Chopra B and Dhingra AK. Natural products: A lead for drug discovery and development. *Phytother. Res*. 2021; 35(9): 4660-702. doi: 10.1002/ptr.7099.
- 19.** Maulydia NB, Khairan K, Tallei T.E., Fauzi FM and Idroes R. Analysis of geothermal impact on metabolite compounds of heat-tolerant plant species using clustering and similarity cliff. *Global Journal of Environmental Science and Management*. 2024; 10(4): 1-16.
- 20.** Shirisha Rao, Nadumane VK. Anti ovarian and cervical cancer potential of Tamarindus Indica Leaf ethanol crude extract and its bioactive fraction, Apigenin. *JJBS*. 2024; 17(3): 453-62. doi: 10.54319/jjbs/170307.
- 21.** Ramya S, Narayanan V, Ponnerulan B, Saminathan E and Veeranan U. Potential of peel extracts of *Punica granatum* and *Citrus aurantifolia* on alloxan-induced diabetic rats. *Beni-Suef Univer. J. Basic Appl. Sci*. 2020; 9(1): 1-11. doi: 10.1186/s43088-020-00049-9.
- 22.** Izah SC and Odubo TC. Effects of *Citrus aurantifolia* fruit juice on selected Pathogens of public health importance. *ES Food and Agroforestry*. 2023; 11(829): 1-14. doi: 10.30919/esfaf829.
- 23.** Roko G, Dougnon VT, Hounkpatin A, Klotoé JR and Baba-Moussa L. Anti-inflammatory, analgesic and antipyretic properties of ethanolic extracts of three plants of Beninese's pharmacopoeia: *Euphorbia hirta*, *Citrus aurantifolia* and *Heterotis rotundifolia*. *Asian J. Biol*. 2020; 1-8. doi: 10.9734/AJOB/2019/v8i430069.

- 24.** Jain S, Arora P and Popli H. A comprehensive review on *Citrus aurantifolia* essential oil: Its phytochemistry and pharmacological aspects. *Brazil. J. Natur. Sci.* 2020; 3(2): 354-64. doi: 10.31415/bjns.v3i2.101.
- 25.** Sitio R, Akmal M, Marlina M and Gholib G. Investigating ethanolic extract from acehnese lime (*Citrus aurantifolia*) peel as potential Anti-Hypercholesterolemia agent. *J. Human. Earth. Future.* 2024; 5(3): 348-65. doi: 10.28991/HEF-2024-05-03-04.
- 26.** Wang M, Zhao H, Wen X, Ho CT and Li Sh. Citrus flavonoids and the intestinal barrier: Interactions and effects. *Compr. Rev. Food Sci. Food Saf.* 2021; 20(1): 225-51. doi: 10.1111/1541-4337.12652.
- 27.** Al-Snafi AE. Blood lipids lowering effect of medicinal plants. *GSCBPS.* 2022; 19(3): 15-43. doi: 10.30574/gscbps.2022.19.3.0213.
- 28.** Tavallali H, Bahmanzadegan A, Rowshan H and Tavallali V. Essential oil composition, antioxidant activity, phenolic compounds, total phenolic and flavonoid contents from pomace of *Citrus aurantifolia*. *JMPB.* 2021; 10(Special issue): 103-16. doi: 10.22092/jmpb.2020.341476.1175.
- 29.** Sitio R, Akmal M, Marlina and Gholib. Phytochemical screening of ethanolic extract of local Aceh lime (*Citrus aurantifolia* (Christm.) Swingle) peels. IOP Conference Series: Earth and Environmental Science. 2024; 1356: 12080. doi: 10.1088/1755-1315/1356/1/012080.
- 30.** Lee YS, Kim WS, Kim KH, Yoon MJ, Cho HJ, Shen Y, Ye J-M, Lee ChH, Oh WK, Kim ChT, Hohnen-Behrens C, Gosby A, Kraegen EW, James DE and Kim JB. Berberine, a natural plant product, activates AMP-activated protein kinase with beneficial metabolic effects in diabetic and insulin-resistant states. *Diabetes.* 2006; 55(8): 2256-64. doi: 10.2337/db06-0006.
- 31.** Ibrahim A, Shafie NH, Esa NM, Shafie SR, Bahari H and Abdullah MA. *Mikania micrantha* extract inhibits HMG-CoA Reductase and ACAT2 and ameliorates Hypercholesterolemia and Lipid Peroxidation in high cholesterol-fed rats. *Nutrients.* 2020; 12(10): 3077. doi: 10.3390/nu12103077.
- 32.** Jia YJ, Xu RX, Sun J, Tang Y and Li JJ. Enhanced circulating PCSK9 concentration by berberine through SREBP-2 pathway in high fat diet-fed rats. *J. Transl. Med.* 2014; 12: 103. doi: 10.1186/1479-5876-12-103.
- 33.** Nyambe-Silavwe H, Villa-Rodriguez JA, Ifie I, Holmes M, Aydin E, Jensen JM and Williamson G. Inhibition of human α -amylase by dietary polyphenols. *Journal of Functional Foods.* 2015; 19:723-32. doi: 10.1016/j.jff.2015.10.003.
- 34.** Duwaerts CC, Maher JJ. Macronutrients and the adipose-liver axis in obesity and fatty liver. *Cell. Mol. Gastroenterol. Hepatol.* 2019; 7(4): 749-61. doi: 10.1016/j.jcmgh.2019.02.001.
- 35.** Lee GH, Peng C, Park SA, Hoang TH, Lee HY, Kim J, Kang S-I, Lee Ch-H, Lee J-S and Chae H-J. Citrus peel extract ameliorates high-fat diet-induced NAFLD via activation of AMPK signaling. *Nutrients.* 2020; 12(3): 673. doi: 10.3390/nu12030673.
- 36.** Uroko RI, Uchenna ON, Achi NK, Agbafor A, Egba SI and Orjiakor CA. The effects of the aqueous extracts of *Elaeis guineensis* fruits on the lipid profile and kidney function indices of male Wistar Albino rats. *JJBS.* 2019; 12(1): 5-16.
- 37.** Bansal AB and Cassagnol M. HMG-CoA Reductase Inhibitors. StatPearls. 2023, Bookshelf ID: NBK542212.
- 38.** Casula M, Colpani O, Xie S, Catapano AL and Baragetti A. HDL in atherosclerotic cardiovascular disease: In search of a role.

- Cells*. 2021; 10(8): 1869. doi: 10.3390/cells10081869.
- 39.** Patel KK and Kashfi K. Lipoproteins and cancer: The role of HDL-C, LDL-C, and cholesterol-lowering drugs. *Biochem. Pharmacol.* 2022; 196: 114654. doi: 10.1016/j.bcp.2021.114654.
- 40.** Tabeshpour J, Hosseinzadeh H, Hashemzaei M and Karimi GHR. A review of the hepatoprotective effects of hesperidin, a flavanon glycoside in citrus fruits, against natural and chemical toxicities. *DARU*. 2020; 28(1): 305-17. doi: 10.1007/s40199-020-00344-x.
- 41.** Rideout TC, Harding SV, Jones PJH and Fan MZ. Guar gum and similar soluble fibers in the regulation of cholesterol metabolism: Current understandings and future research priorities. *Vasc. Health Risk Manag.* 2008; 4(5): 1023-33. doi: 10.2147/vhrm.s3512.
- 42.** van Bennekum AM, Nguyen DV, Schulthess G, Hauser H and Phillips MC. Mechanisms of cholesterol-lowering effects of dietary insoluble fibres: relationships with intestinal and hepatic cholesterol parameters. *Br. J. Nutr.* 2005; 94(3): 331-7. doi: 10.1079/bjn20051498.
- 43.** Guyton AC and Hall JE. Textbook of Medical Physiology. 12th ed. Gruliow R, editor. Philadelphia: Elsevier Sounder; 2011, 1-1091 p.
- 44.** Shi Z, Li T, Liu Y, Cai T, Yao W, Jiang J, He Y and Shan L. Hepatoprotective and anti-oxidative effects of total flavonoids from Qu Zhi Qiao (fruit of *Citrus paradisi* cv. Changshanhuoyou) on nonalcoholic steatohepatitis *In vivo* and *In vitro* through Nrf2-ARE signaling pathway. *Front. Pharmacol.* 2020; 11: 483. doi: 10.3389/fphar.2020.00483.
- 45.** Li S, Yin S, Ding H, Shao Y, Zhou S, Pu W, Han L, Wang T and Yu H. Polyphenols as potential metabolism mechanisms regulators in liver protection and liver cancer prevention. *Cell Prolif.* 2023; 56(1): e13346. doi: 10.1111/cpr.13346.
- 46.** Shraideh Z, Badran DH, Alzbeede AA, Qattan D, Alzbeede AA and Friehat K. Effect of Garlic, Vitamin C, Vitamin E–Selenium against bioaccumulated Organolead-induced cellular injury in Liver and Spleen of Albino rats: pilot study. *JJBS*. 2021; 14(2): 285-90. doi: 10.54319/jjbs/140213.
- 47.** Elemo O, Ishola I and Olayemi S. Hypolipidaemic and antioxidant effects of *Citrus aurantifolia* fruit juice. *University of Lagos Journal of Basic Medical Sciences*. 2014; 2(2): 22-9.
- 48.** Sivasubramanian P, Gayathri R, Priya VV, Selvaraj J and Kavitha S. Evaluation of anti cholesterol and antioxidant potentiality of aqueous extracts of *Citrus aurantifolia*, *Zingiber officinale* and its formulation - a comparative *In vitro* study. *JPRI*. 2021; 33(60B): 1873-82.
- 49.** Kazeem MI, Bankole HA, Oladokun TI, Bello AO and Maliki MA. *Citrus aurantifolia* (Christm.) Swingle (lime) fruit extract inhibits the activities of Polyol pathway enzymes. *eFood*. 2020; 1(4): 310-5. doi: 10.2991/efood.k.200824.001.

How to cite this article: Sitio R, Nugroho EGZ, Maulydia NB. A study on the hypocholesterolemic and potential hepatoprotective effects of ethanol extract of *Citrus aurantifolia* peel in rats fed a high-fat diet. *Journal of Medicinal Plants* 2025; 24(96): 83-96. doi: [10.66224/jmp.24.96.83](https://doi.org/10.66224/jmp.24.96.83)