J. Med. Plants 2026; 25(98): 1-16

Institute of Medicinal Plants

Journal of Medicinal Plants

Journal homepage: www.jmp.ir



Research Article

Therapeutic effect of hydroalcoholic extract of *Portulaca oleracea* against cuprizone-induced demyelination by targeting Nrf2/HO-1/NQO-1/NF-kB in C57BL/6 mice

Tayebeh Noori[1], Seyede Zahra Hosseini[2], Sina Korani[2], Seyede Darya Alavi[2], Niloofar Heidarizade[2], Ahmad Mohammadi-Farani[3,4], Samira Shirooie[1,*]

[1]*Pharmaceutical Sciences Research Center, Health Institute, Kermanshah University of Medical Sciences, Kermanshah, Iran*
[2]*Student Research Committee, Faculty of Pharmacy, Kermanshah University of Medical Sciences, Kermanshah, Iran*
[3]*Medical Plants Research Center, Basic Health Sciences Institute, Shahrekord University of Medical Sciences, Shahrekord, Iran*
[4]*Department of Physiology and Pharmacology, School of Medicine, Shahrekord University of Medical Sciences, Shahrekord, Iran*

ARTICLE INFO

Keywords:
Multiple sclerosis
Cuprizone
P. oleracea
Demyelination
Nrf2
NF-kB

ABSTRACT

Background: Multiple sclerosis (MS) is a chronic autoimmune disorder of the central nervous system that leads to inflammatory demyelination and axonal damage. **Objective**: This study evaluated the therapeutic potential of *Portulaca oleracea* extract in a mice model of CPZ-induced multiple sclerosis. **Methods:** In the present experiment, CPZ was used to induce an MS-like conditions in mice. During the final two weeks of CPZ exposure, mice received *P. oleracea* extract at doses of 100, 200, or 300 mg/kg/day by intraperitoneal injection. After the study period, behavioral tests, histochemical examination, and immunohistochemical analysis were performed to assess HO-1, NQO-1, p-Nrf2, and NF-κB p65. **Results:** Compared with control group, mice fed CPZ showed significant weight loss, impaired motor function, and significant demyelination of the corpus callosum in LFB staining. Administration of *P. oleracea* during the last two weeks improved behavioral deficits and reduced CPZ-associated weight loss and myelin damage. In the corpus callosum, CPZ decreased the expression of HO-1, NQO-1, and p-Nrf2 while increasing the expression of NF-κB p65. These changes were partially reversed by treatment with the extract. **Conclusion:** *P.* oleracea may be a potential candidate for further preclinical research on MS.

1. Introduction

Multiple sclerosis (MS) is a long-standing inflammatory disorder that causes demyelination within the central nervous system (CNS) [1] which causes various degrees of myelin and axon destruction [2]. Inflammation-

Abbreviations: CNS, Central Nervous System; CPZ, Cuprizone; HO-1, Heme Oxygenase-1; IHC, Immunohistochemistry; LFB, Luxol Fast Blue; MS, Multiple Sclerosis; NF-κB, Nuclear Factor Kappa B; NQO-1, NAD(P)H Quinone Oxidoreductase 1; Nrf2, Nuclear Factor Erythroid 2-related Factor 2; OFT, Open Field Test; PBMCs, Peripheral Blood Mononuclear Cells; ROS, Reactive Oxygen Species; SEM, Standard Error of the Mean

*Corresponding author: samira.shirooei@kums.ac.ir; shirooie@gmail.com

doi: 10.66224/jmp.25.98.1

Received 30 December 2024; Received in revised form 18 November 2025; Accepted 1 June 2026

© 2023. Open access. This article is distributed under the terms of the Creative Commons Attribution-NonCommercial 4.0 International License (https://creativecommons.org/licenses/by-nc/4.0/)

[Downloaded from jmp.ir on 2026-11-28]

[DOI: 10.66224/jmp.25.98.1]

related loss of myelin and axonal damage in the Corpus Callosum are the characteristics of MS, which may contribute to poor function on challenging tasks [3]. MS usually begins between the ages of 20- 40. Based on investigations, 2.8 million individuals worldwide suffer from MS, and due to motor, autonomic, and cognitive impairments, causes significant disability [4, 5]. In the majority of patients, the condition is first characterized by reversible neurological impairment episodes, which are frequently followed by a gradual neurological decline, over time [6, 7]. Oxidative stress is regarded as one of the major pathogenic mechanisms involved in MS. Oxidative stress can activate phase II detoxification enzymes, particularly NQO-1, a key antioxidant enzyme. [8, 9]. Nuclear factor erythroid-2-related factor 2 (Nrf2) functions as a nuclear transcription factor that modulates cellular redox balance and antioxidant gene expression. One of the cellular protective factors is the transcription factor Nrf2. This transcription factor increases cell survival in the face of various stresses. It also has a significant role in protection against oxidative stress and cell damage caused by chemicals [10-12], and development of inflammation could be slowed down by activating the Nrf2 pathway [13, 14]. According to several reports, the pathophysiology of MS might be constrained to downregulation the the Nrf2-regulated antioxidant signaling axis involving HO-1 and NQO1 [11, 15]. HO-1, an Nrf2-responsive enzyme, mediates heme catabolism to biliverdin while releasing free iron and carbon monoxide, which helps protect cells from oxidative injury [16]. HO-1 expression is significantly downregulated during MS exacerbation in peripheral blood mononuclear cells (PBMCs) of patients with the condition [17, 18]. NQO1 is another Nrf2-regulated gene which expresses NQO1 enzyme with several protective effects including detoxification and anti-tumor activity [19]. Several studies have been indicated that activating Nrf2/HO-1/NQO1 signaling decreased the ROS generation, improved myelin integrity and behavioral changes in multiple sclerosis [20, 21]. Based on some research in astrocytes, macrophages, T cells, oligodendrocytes, and neurons in the CNS of MS patients, the transcription factor nuclear factor-kappa B (NF-κB) is activated, which accelerates the progression of MS by increasing inflammation. p65:p50 is the most prevalent type of NF-κB triggered by pathogenic stimuli [22-24].

Interferon *β*, glatiramer acetate, mitoxantrone, natalizumab, and fingolimod are commonly used to treat MS, and these medications present physicians with several challenges, including efficacy and adverse effects [1, 25]. *Portulaca oleracea* L., a member of the Portulacaceae family, contains diverse phytochemicals, including terpenoids, flavonoids, alkaloids, coumarins, and cerebrosides, in addition to vitamins, fatty acids, proteins, sterols, and minerals. The constituents of *P. oleracea* have been associated with neuroprotective, analgesic, hepatoprotective, antioxidant, immunomodulatory, and anti-inflammatory activities [26-30]. Its traditional medicinal use and the neuroprotective and antinociceptive effects of its constituents have also been reported [31, 32]. The anti-inflammatory properties of *P. oleracea* have been associated with suppression of iNOS and COX-2 expression, together with attenuation of NF-κB and MAPK signaling [33]. Experimental studies have also reported that *P. oleracea* reduces p65 phosphorylation and nuclear translocation, while lowering NO, TNF-*α*, and IL-6 production [28, 34, 35]. Other

[Downloaded from jmp.ir on 2026-11-28]

[DOI: 10.66224/jmp.25.98.1]

findings link the antioxidant and anti-inflammatory effects of *P. oleracea* to modulation of the Nrf2/HO-1/NQO1/NF-κB axis, with increased Nrf2 and HO-1 expression after treatment [34]. On the other hand, studies indicate that *P. oleracea* modifies the triggered Th1 ailments such as hepatitis and MS [36]]. There are different models for MS induction, including ethidium bromide (EB), lysolecithin, and cuprizone. The cuprizone (CPZ) model is a toxic demyelination model. In this paradigm, young mice consume the copper chelator CPZ, resulting in oligodendrocyte injury and subsequent myelin loss and then there is a period of remyelination recovery time [37-40]. Given the burden of MS and the traditional use of *P. oleracea*, this study examined whether its extract could improve CPZ-associated behavioral impairment in mice.

2. Materials and methods

2.1. Chemicals

Cuprizone (CPZ) was obtained from Merck KGaA, Germany. NF-kB p65 ((F-6): SANTA CRUZ -8008) and p-Nrf2 (phospho S40) antibody [EP1809Y] abcam76026, HO-1 (A-3): SANTA CRUZ-136960, Anti-NQO1 antibody abcam34173 and the secondary antibody m-IgGκ BP-HRP (SANTA CRUZ-516102) were used for immuhistochemistry tests.

2.2. Extraction method

Plant material of *P. oleracea* was obtained from a local herbal supplier and authenticated at the Herbarium Institute of Kermanshah University of Medical Sciences (herbarium code: 001/001/151). After washing with distilled water, the material was air-dried at 25 °C and pulverized using a mechanical mill. The powder was extracted with ethanol/distilled water (70:30, v/v) on a shaker for 72 h. After concentration by rotary evaporation and drying in an incubator, the hydroalcoholic extract was reconstituted in the extraction solvent to obtain the target concentrations [41].

2.3. Animals

Thirty-five male C57BL/6 mice (8 weeks old, 20–25 g) were included in the study. Following procurement from the Pasteur Institute of Karaj, the animals were kept under standard laboratory conditions at 25 °C and a 12-h light/dark cycle, according to the ethical standards of Kermanshah University of Medical Sciences, Iran (IR.KUMS.REC.1400.232).

2.4. Cuprizone-induced demyelination and subsequent P. oleracea extract treatment

Animals received a normal diet containing 0.2 % (w/w) CPZ to induce demyelination [42, 43]. Mice were randomly assigned to five experimental groups, with seven animals per group.

1) Control group: animals that received standard food for 6 weeks.

2) CPZ group: mice exposed to a diet containing 0.2 % (w/w) CPZ for a 6-week period.

3) CPZ group + 100mg/kg *P. oleracea* extract (P1): Animals that received food containing 0.2 % CPZ for 6 weeks and 100mg/kg *P. oleracea* extract by intraperitoneal (i.p.) injection for the last two weeks of the study.

4) CPZ group + 200mg/kg *P. oleracea* extract (P2): Animals that received food containing 0.2 % CPZ for 6 weeks and 200 mg/kg *P. oleracea* extract by i.p. injection for the last two weeks of the study.

5) CPZ group + 300mg/kg *P. oleracea* extract (P3): Animals that received food containing 0.2 % CPZ for 6 weeks and 300 mg/kg *P. oleracea* extract by i.p. injection during the final 2 weeks of the experimentAll the selected doses were chosen by previous studies [25, 44-47].

[Downloaded from jmp.ir on 2026-11-28]

[DOI: 10.66224/jmp.25.98.1]

2.5. Behavioral tests

At the completion of the experiment, the open field test (OFT), pole test, and rotarod test were conducted to assess locomotor activity, coordination, and motor balance in mice. For the pole test, each mouse was positioned at the upper end of the bar, and the time required to reach the base was recorded. The bar had 1 cm diameter and measured 50-60 cm tall (cut-off time: 1min). Three times of this test were run, each with a five-minute break in between [44].

To assess each mouse's motor learning and sensorimotor coordination, the Rotarod test was used. The gadget rotated at 25 revolutions per minute, and the mice's contact angle with the rotating cylinder was 45 degrees. Three times of this test were conducted, each with a three-minute break (cut-off time: 5 min) [25].

The OFT is an uncomplicated sensorimotor test designed to assess general levels of activity. In this experiment, mice are placed in a wooden box (50 cm x 60 cm x 40 cm). The bottom of the box is divided into 16 equal squares, and the number of houses they pass through in 5 minutes is calculated [44].

2.6. Brain preparations

After completion of the behavioral assays, anesthesia was induced with ketamine (50 mg/kg) and xylazine (10 mg/kg) via the intraperitoneal route, after which the brains were removed and fixed in 10 % formalin for histopathological examination, including IHC, H&E, and LFB staining.

2.7. Myelin staining

A common technique for observing myelin and evaluating the process of demyelination is LFB staining. With this method, myelin, neuropil, and neuronal structures appear blue, pink, and purple, respectively. Corpus callosum tissues were cut into 5-um sagittal cuts and dried for an entire night at 37 °C. Following deparaffinization, clarification, hydration in ethanol (95 %), rinsing with distilled water, and staining with LFB (0.1 %), tissues were processed. Ethanol (95 %) and water were used to clean away extra dyes. 70 percent ethanol and 0.05 % lithium carbonate were used to induce tissue differentiation. Finally, xylene was used to clean and mount dehydrated tissue sections [25].

2.8. Hematoxylin and eosin (H&E) staining

Five-micrometer sections of the prefrontal cortex were prepared using a microtome. Slides were stained with hematoxylin for 6 h at 60 °C and subsequently rinsed with distilled water. Differentiation was performed using 10 % acetic acid and 85 % ethanol. Sections were then immersed in saturated lithium carbonate, washed with water, and counterstained with eosin [25].

2.9. Immunohistochemistry (IHC) staining

Paraffin-embedded corpus callosum sections (5 μm) were used to evaluate HO-1, NQO-1, NF-κB p65, and p-Nrf2 expression. Sections were deparaffinized in xylene, passed through ethanol, and rehydrated in citrate buffer. Following antigen retrieval in citrate buffer (pH 6.0) at 90 °C for 15 min, samples were blocked with 1 % BSA for 1 h at 37 °C [25].

2.10. Data analysis

GraphPad Prism 9 (San Diego, CA, USA) was used for statistical analysis. Group differences were examined by one-way ANOVA with Tukey's post hoc multiple-comparison test. Data are presented as mean ± SEM, and $P < 0.05$ was considered statistically significant. Quantification of LFB and IHC data was performed in ImageJ.

[Downloaded from jmp.ir on 2026-11-28]

[DOI: 10.66224/jmp.25.98.1]

3. Results

3.1. Bodyweight

Body weight was measured on a weekly basis, as shown in Figure 1A and B. Compared with the control group, mice exposed to CPZ exhibited a marked reduction in body weight after the first week, and this decline persisted throughout the 6-week experimental period ($P < 0.05$). Throughout the study, body weight in the CPZ group remained consistently lower than that of the controls. In the last 2 weeks of the experiment, treatment with P. oleracea extract at all three doses significantly alleviated CPZ-induced weight loss relative to the CPZ group ($P < 0.05$).

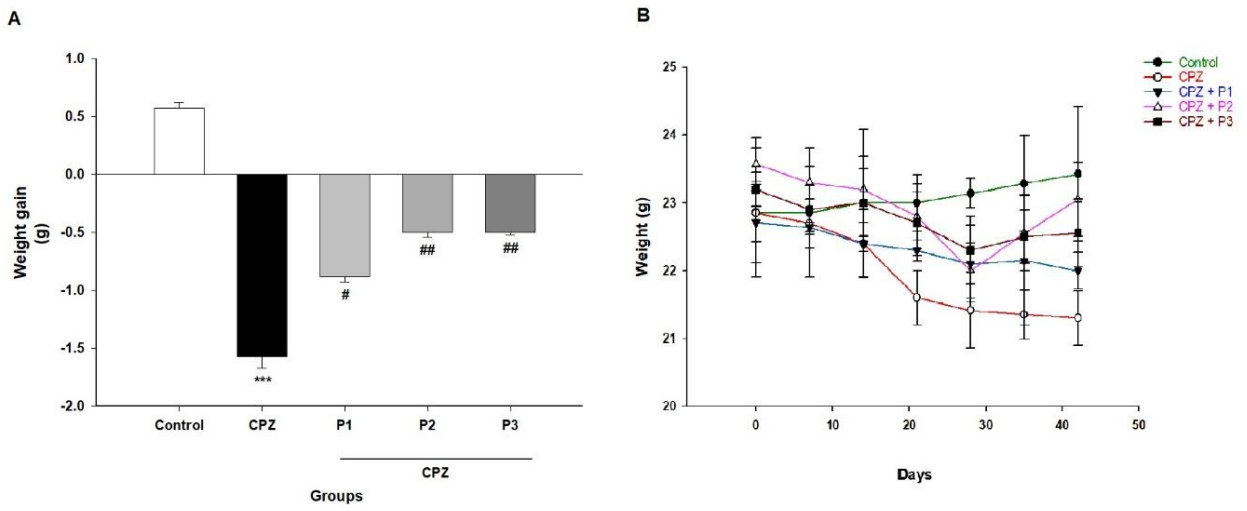

Fig. 1. The body weight changes (n = 7). (A) Weight gain, (B) the body weight variations during 6 weeks. CPZ: CPZ group; CPZ + P1: *P. oleracea* extract 100 mg/kg treated-CPZ group; CPZ + P2: *P. oleracea* extract 200 mg/kg treated-CPZ group; CPZ + P3: *P. oleracea* extract 300 mg/kg treated-CPZ group. $^{\#}P < 0.05$; $^{\#\#}P < 0.01$ compared with the CPZ group; $^{***}P < 0.001$ compared with control group.

3.2. Behavioral tests

3.2.1. The pole test

Motor coordination was assessed using the pole test, and the results are presented in Figure 2A. Mice given CPZ performed worse than the control group in terms of motor coordination ($F(4, 94) = 4.736$, $P < 0.05$). While mice that were treated with 100 and 200 mg/kg *P. oleracea* extract, performed better ($P < 0.05$) versus the CPZ group ($P < 0.05$). However, there was no significant difference for the dose of 300 mg/kg.

3.2.2. Rotarod performance test

Rotarod performance was significantly reduced in the CPZ group, as indicated by a shorter latency to fall compared with controls ($F(4, 83) = 7.041$, $P < 0.001$). Compared to the CPZ group, the rats who took 100, 200, and 300 mg/kg *P. oleracea* extract, spent a lot longer time on the rotating cylinder, indicating improved motor coordination ($P < 0.01$, $P < 0.01$, $P < 0.05$ respectively) (Figure 2B).

3.2.3. Open field test (OFT)

Figure 2C shows that CPZ exposure markedly reduced movement counts and increased immobility time in mice ($F(4, 27) = 7.200$, $P < 0.01$). In contrast, the number of movements of mice that received the *P. oleracea* extract increased meaningfully versus the CPZ group ($P < 0.01$, $P < 0.05$, $P < 0.01$ respectively at 100, 200, and 300 mg/kg).

[Downloaded from jmp.ir on 2026-11-28]

[DOI: 10.66224/jmp.25.98.1]

3.3. Myelin staining (Luxol fast blue staining)

LFB staining demonstrated marked corpus callosum demyelination in the CPZ group compared with the control group ($F(4, 12) = 4.159$, $P < 0.01$). This was demonstrated by a considerable decrease in the intensity of the blue color. *P. oleracea* treatment (3 doses) reduced the demyelination process seen in the CPZ group and protected myelin from damage caused by CPZ ($P < 0.05$). An area of myelin rich in lipids and the beneficial effects of *P. oleracea* on myelin repair are revealed by the blue color's intensity, which is similar to the control group (figure 3A-B).

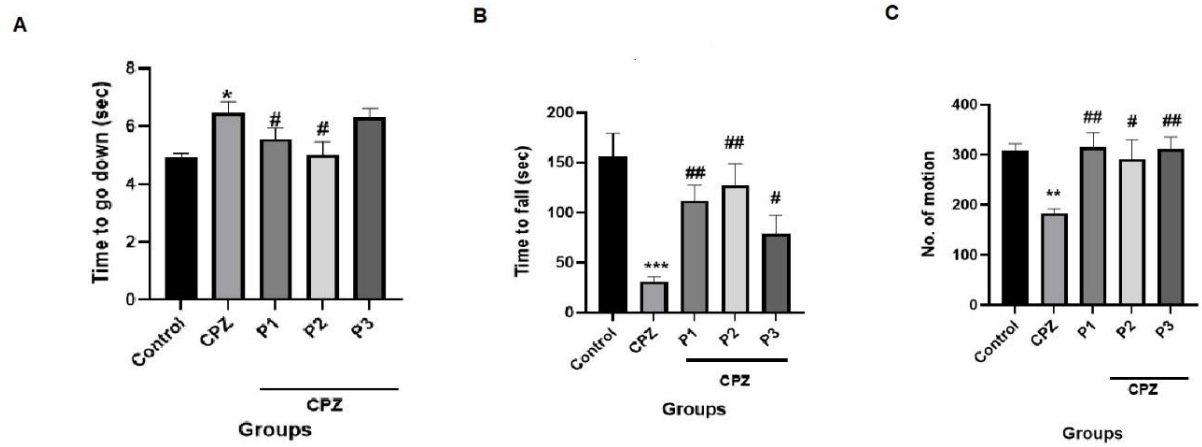

Fig. 2. Behavioral tests (n = 7). A: The pole test, the graph shows the time to reach the floor. B: The rotarod test, the graph demonstrates the latency to fall. C: The open field test, Number of motions is shown. CPZ: CPZ group; CPZ + P1: *P. oleracea* extract 100 mg/kg treated-CPZ group; CPZ + P2: *P. oleracea* extract 200 mg/kg treated-CPZ group; CPZ + P3: *P. oleracea* extract 300 mg/kg treated-CPZ group. #P < 0.05 compared with CPZ group; *P < 0.05 versus the control group.

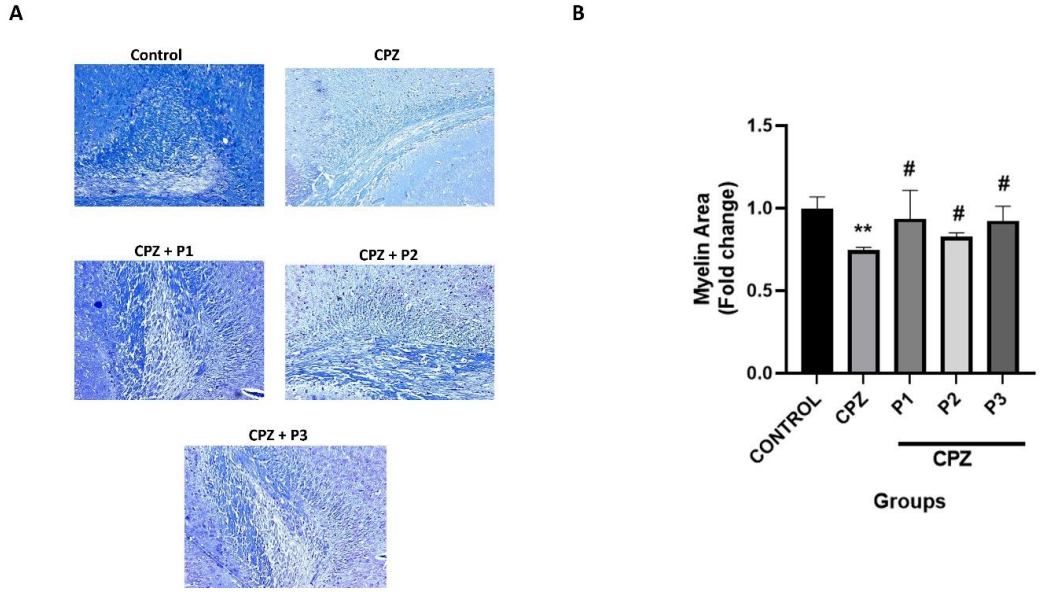

Fig. 3. LFB staining of the corpus callosum (× 100). CPZ causes demyelination, which results in diminished blue color intensity, whereas normal myelin is observed in the corpus callosum in the control and CPZ + P groups (increased blue intensity color). CPZ: CPZ group; CPZ+P1: *P. oleracea* extract 100 mg/kg treated-CPZ group; CPZ+P2: *P. oleracea* extract 200 mg/kg treated-CPZ group; CPZ+P3: *P. oleracea* extract 300 mg/kg treated-CPZ group. #P < 0.05; compared with CPZ group; **P < 0.01 versus control group.

[Downloaded from jmp.ir on 2026-11-28]

[DOI: 10.66224/jmp.25.98.1]

3.4. Hematoxylin and eosin staining (H&E)

Cortical H&E staining was done to evaluate histological alterations involving neurons, oligodendrocytes, and tissue architecture. In the perspective of histological characteristics, according to Figure 4 the cerebral cortex's detrimental consequences of CPZ, including myelin degradation, chromatolysis, aberrant Nissl granules, hyperchromatic nuclei, and vacuolated neurons, were diminished by injection of *P. oleracea* extract, which also revealed near-normal features like what is observed in the control group. In contrast to the CPZ group, the prefrontal cortex morphology, numbers of oligodendrocyte, and myelin density are all normal in the control group.

3.5. Immunohistochemistry assay of HO-1, NQO-1, p-Nrf2 and NF-κB p65

Immunohistochemical staining was performed to examine CPZ-associated changes and the effects of *P. oleracea* treatment to observe the protein expression of HO-1, NQO-1, NF-κB p65, and p-Nrf2 in the corpus callosum of animals' brain.

HO-1 ($F(4, 10) = 5.557$, $P < 0.05$), NQO-1 ($F(4, 14) = 7.417$, $P < 0.001$) and p-Nrf2 ($F(4, 14) = 6.500$, $P < 0.01$) expression in the CPZ group was considerably reduced compared to the control group ($P < 0.05$); Meanwhile, consumption of the *P. oleracea* extract (100 and 200 mg/kg doses) recovered the expression reduction of HO-1 and there was a significant difference compared to the CPZ group ($P < 0.05$) (Figure 5). Moreover, consumption of the extract (100 and 200 mg/kg doses) recovered the expression reduction of NQO-1 compared to CPZ group ($P < 0.001$, $P < 0.05$ respectively) (Figure 6), and also the expression reduction of p-Nrf2 was recovered after consumption of the extract (100 and 200 mg/kg doses) versus to CPZ group (0.1, 0.05 respectively) (Figure 7). In contrast, the corpus callosum NF-κB p65 expression in the CPZ group, was significantly higher than versus the control group ($F(4, 21) = 10.96$, $P < 0.001$). The elevated levels of NF-κB p65 expression noticeably declined after the consumption of *P. oleracea* extract (100 and 200 mg/kg doses) compared CPZ group ($P < 0.01$) (Figure 8).

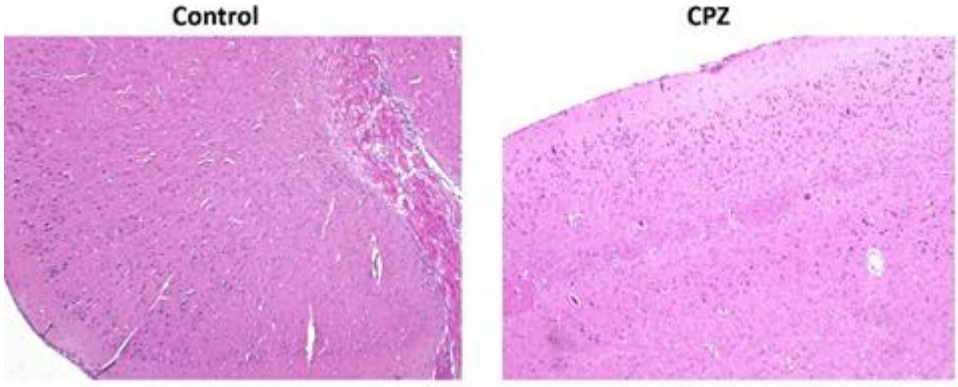

Fig. 4. Photomicrograph of cortex H & E (hematoxylin and eosin staining) (× 100). CPZ causes abnormalities in Nissl substance and neurons whereas the control group and CPZ + P treatment groups show normal structure. CPZ: CPZ group; CPZ+P1: *P. oleracea* extract 100 mg/kg treated-CPZ group; CPZ + P2: *P. oleracea* extract 200 mg/kg treated-CPZ group; CPZ+P3: *P. oleracea* extract 300 mg/kg treated-CPZ group.

[Downloaded from jmp.ir on 2026-11-28]

[DOI: 10.66224/jmp.25.98.1]

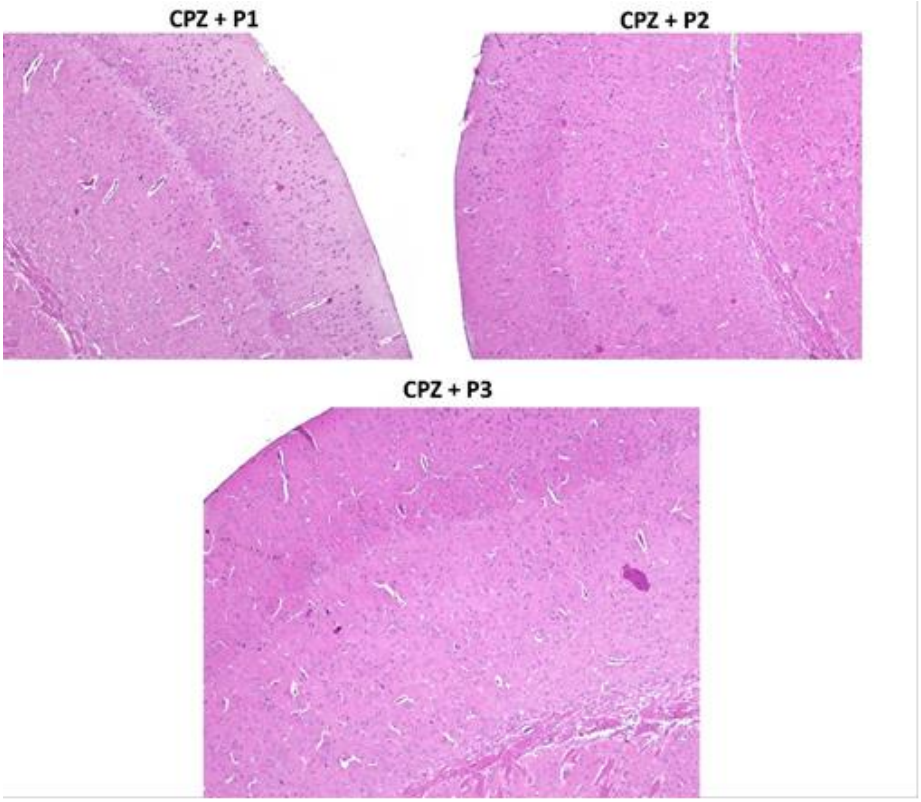

Fig. 4. Photomicrograph of cortex H & E (hematoxylin and eosin staining) (× 100). CPZ causes abnormalities in Nissl substance and neurons whereas the control group and CPZ + P treatment groups show normal structure. CPZ: CPZ group; CPZ+P1: *P. oleracea* extract 100 mg/kg treated-CPZ group; CPZ + P2: *P. oleracea* extract 200 mg/kg treated-CPZ group; CPZ+P3: *P. oleracea* extract 300 mg/kg treated-CPZ group (continued).



Fig. 5. A

[Downloaded from jmp.ir on 2026-11-28]

[DOI: 10.66224/jmp.25.98.1]

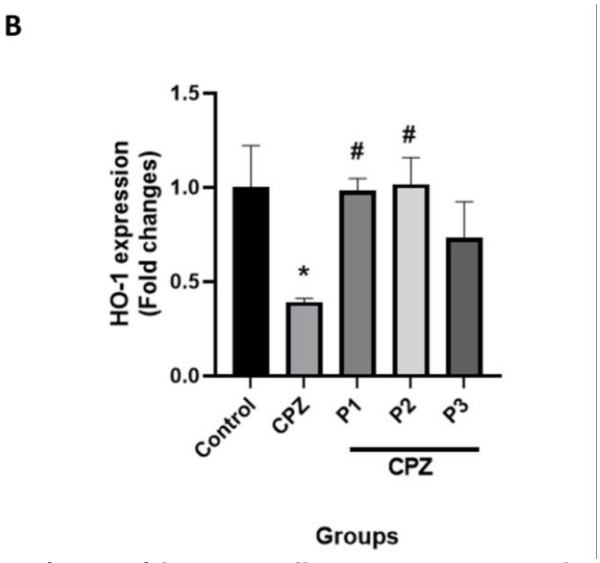

Fig. 5. A: Immunohistochemistry of HO-1 of the corpus callosum (×40, ×100). B: The quantified intensity of HO-1 staining by ImageJ. CPZ: CPZ group; CPZ + P1: *P. oleracea* extract 100 mg/kg treated-CPZ group; CPZ + P2: *P. oleracea* extract 200 mg/kg treated-CPZ group; CPZ + P3: *P. oleracea* extract 300 mg/kg treated-CPZ group. #P < 0.05; compared with CPZ group; *P < 0.05 versus the control group.

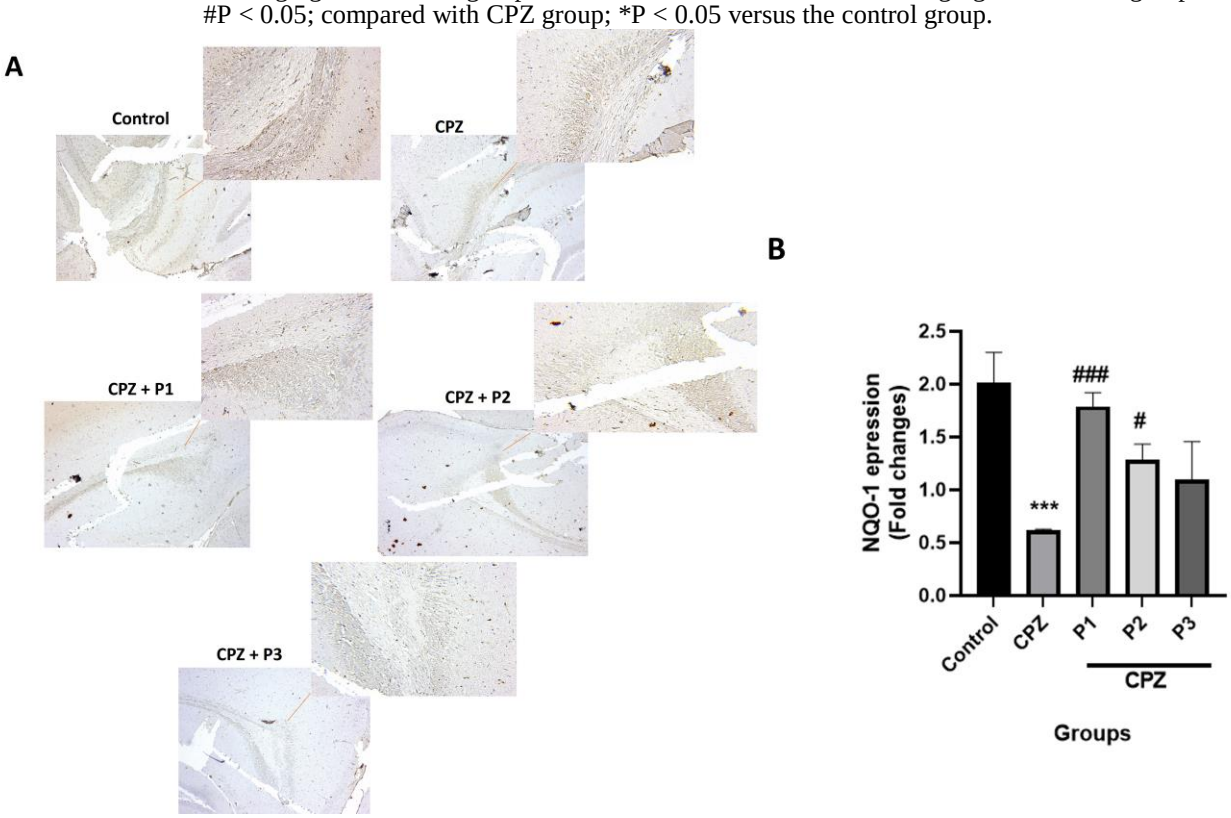

Fig. 6. A: Immunohistochemistry of NQO-1 of the corpus callosum (× 40, × 100). B: The quantified intensity of NQO-1 staining by ImageJ. CPZ: CPZ group; CPZ + P1: *P. oleracea* extract 100 mg/kg treated-CPZ group; CPZ + P2: *P. oleracea* extract 200 mg/kg treated-CPZ group; CPZ + P3: *P. oleracea* extract 300 mg/kg treated-CPZ group. $^{\#}P < 0.05$; $^{\#\#\#}P < 0.001$ compared with CPZ group; $^{***}P < 0.001$ compared with control group.

[Downloaded from jmp.ir on 2026-11-28]

[DOI: 10.66224/jmp.25.98.1]

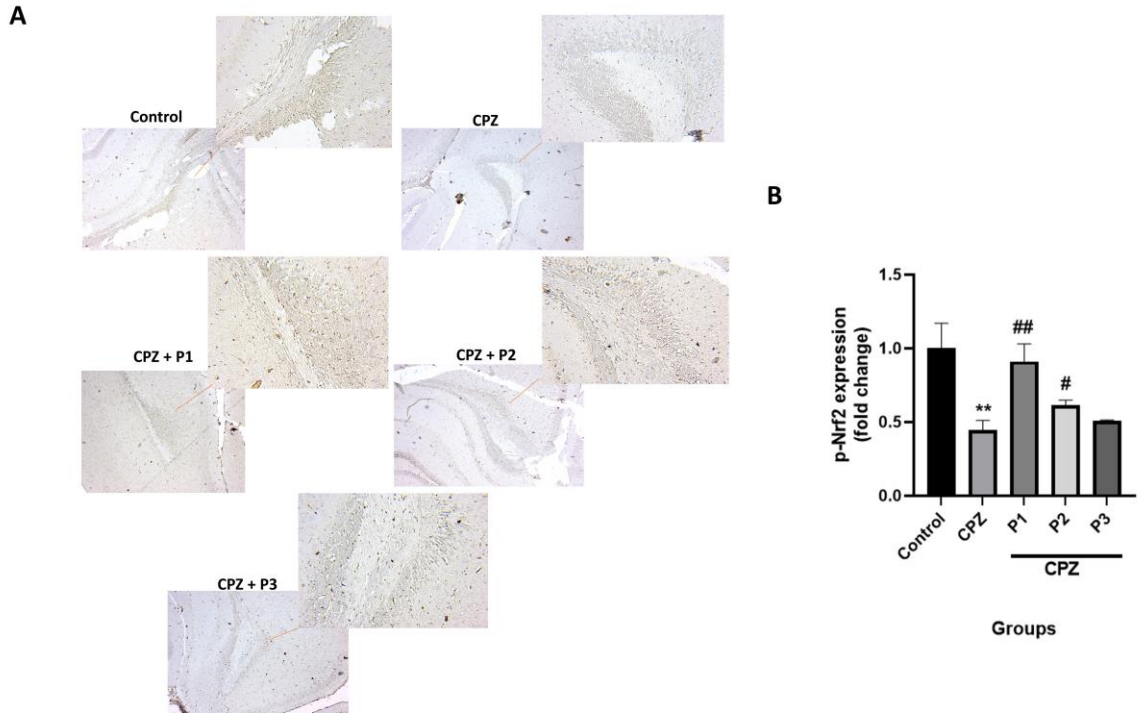

Fig. 7. A: Immunohistochemistry of p-Nrf2 of the corpus callosum (×40, ×100). B: The quantified intensity of p-Nrf2 staining by ImageJ. CPZ: CPZ group; CPZ + P1: *P. oleracea* extract 100 mg/kg treated-CPZ group; CPZ + P2: *P. oleracea* extract 200 mg/kg treated-CPZ group; CPZ + P3: *P. oleracea* extract 300 mg/kg treated-CPZ group. #P < 0.05; ##P < 0.01 compared with CPZ group; **P < 0.01 versus control group.

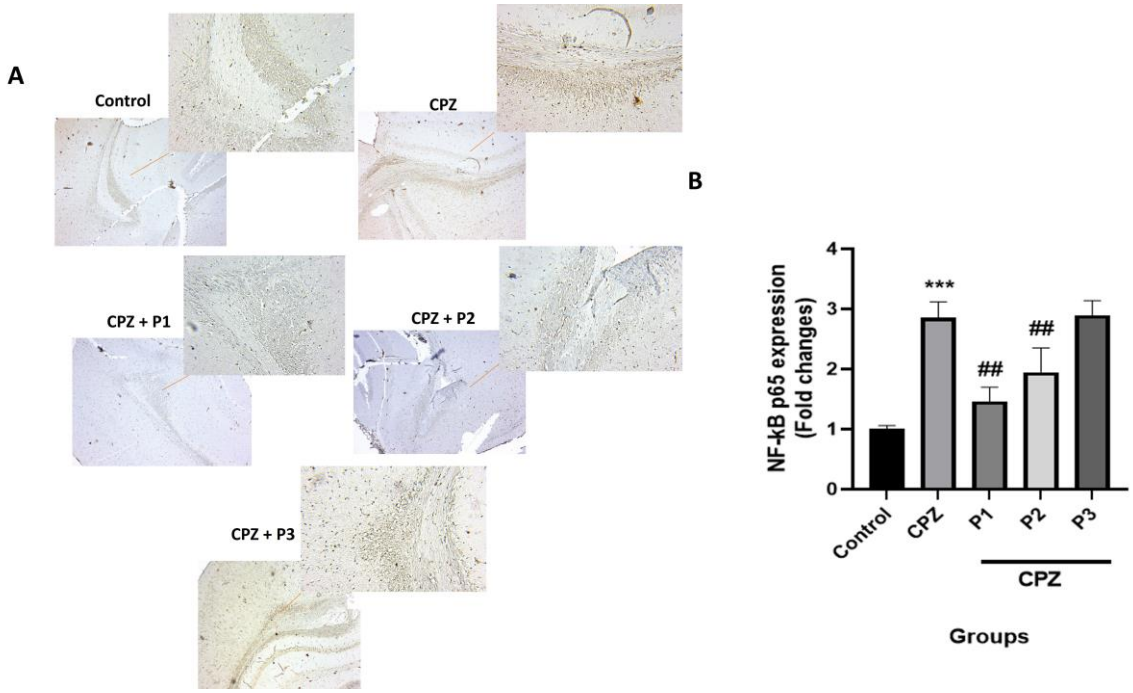

Fig. 8. A: Immunohistochemistry of NF-kB p65 of the corpus callosum (× 40, × 100). B: The quantified intensity of NF-kB p65 staining by ImageJ. CPZ: CPZ group; CPZ + P1: *P. oleracea* extract 100 mg/kg treated-CPZ group; CPZ + P2: *P. oleracea* extract 200 mg/kg treated-CPZ group; CPZ + P3: *P. oleracea* extract 300 mg/kg treated-CPZ group. ##P < 0.01 compared with CPZ group; ***P < 0.001 versus control group.

[Downloaded from jmp.ir on 2026-11-28]

[DOI: 10.66224/jmp.25.98.1]

4. Discussion

Ms is a long-term immune-mediated CNS disorder in which inflammatory demyelination and progressive neurodegenerative processes occur. It is associated with a cascade of pathological events, such as oxidative stress, apoptosis, axonal damage, and gliosis, leading to motor and behavioral impairments [48]. There are numerous animal models, including CPZ, for MS research [49]. By interfering with copper-dependent mitochondrial enzymes, CPZ promotes oxidative stress and oligodendrocyte injury. The resulting cellular damage can contribute to axonal inflammation and functional impairment in demyelinating disorders [25]. In several CPZ animal model studies, results have reported behavioral and motor changes in the CPZ group that were proven by various tests such as rotarod, open field, and pole [45, 50]. Moreover, CPZ reduces the body weight [44]. In the present study, we investigated the capability of *P. oleracea* to ameliorate the dysfunction of behavioral motor and to protect myelin in a CPZ-induced demyelination model. Interestingly, our study's outcomes indicate that consumption of the *P. oleracea* extract led to the compensation of the lost weight. In this study, the 100- and 200-mg/kg doses of *P. oleracea* improved locomotor performance and motor coordination ($P < 0.05$ and $P < 0.01$), whereas the 300 mg/kg dose showed a milder or non-significant effect in certain tasks. These behavioral improvements reflect the extract's ability to reverse neurological damage, potentially by enhancing myelin integrity. Previous evidence suggests that *P. oleracea* can modulate Nrf2 signaling and reduce oxidative cellular injury [51]. Previous research results have shown that demyelination in the mouse brain leads to behavioral dysfunction [52]. Exposure of animals to CPZ has an effective role in increasing the number of demyelinating fibers. Nevertheless, *P. oleracea* consumption significantly reduced these histological changes, which shows the effectiveness of *P. oleracea* in improving the remyelination process. Earlier in vivo findings have associated more extensive CPZ-induced demyelination with greater body-weight loss. Therefore, the attenuation of weight loss observed after *P. oleracea* treatment may reflect partial protection against demyelinating injury [53]. The outcomes of this research showed that CPZ diet leads to the induction of demyelinated areas in the brain which is in accordance with the results of prior studies [45]. *P. oleracea* has been reported to suppress NF-κB/MAPK signaling, limit p65 phosphorylation, and reduce inflammatory mediator production, reduces NO, TNF-, and IL-6 production, and that its anti-inflammatory and antioxidant activities are linked to the Nrf2/HO-1/ NF-κB pathway [54]. In the present study, *P. oleracea* counteracted the CPZ-associated reduction in HO-1, NQO-1, and p-Nrf2 expression and lowered the elevated NF-κB level. This pattern is compatible with antioxidant protection involving Nrf2/HO-1 signaling. It also agrees with previous reports of reduced HO-1 expression during MS exacerbation and the contribution of NF-κB activation to neuroinflammation through immune and glial-cell responses [14-18, 22-24]. In the present work, NF-kB p65 levels were meaningfully higher in the CPZ group. Nevertheless, PO decreased the NF-kB expression [44]. Histological assessments using luxol fast blue and H&E staining confirmed severe demyelination and neuronal damage following CPZ administration ($P < 0.01$). Treatment with *P. oleracea* notably reduced the extent of these alterations ($P < 0.05$), preserving myelin structure and restoring near-normal cellular architecture, demonstrating the effectiveness of *P. oleracea* treatment in enhancing the process of remyelination.

5. Conclusion

This study confirmed that CPZ exposure produced demyelination and movement-related

[Downloaded from jmp.ir on 2026-11-28]

[DOI: 10.66224/jmp.25.98.1]

impairment in mice. P. oleracea improved behavioral performance and reduced histological evidence of myelin injury. The accompanying increase in Nrf2-related antioxidant markers and reduction in NF-κB expression suggest possible antioxidant and anti-inflammatory mechanisms. Further mechanistic and preclinical studies are required before clinical relevance in MS can be considered.

Author contributions

SS Conceptualization, Methodology, Writing - original draft, Writing - review & editing & Supervision. SDA, SZH and SK Data curation, Writing- Original draft preparation. AMF Validation, Investigation & Writing - review & editing. TN & NH Visualization, Investigation & Writing - review & editing.

Conflicts of interest

The authors have no conflict of interest.

Acknowledgments

This project was supported by the Kermanshah University of Medical Sciences with grant number 4000577.

References

1. Hauser SL and Cree BAC. Treatment of Multiple Sclerosis: A review. *Am. J. Med.* 2020. 133(12): 2020; 1380-1390.e2. doi: 10.1016/j.amjmed.2020.05.049.

2. Weinshenker BG. Epidemiology of multiple sclerosis. *Neurol. Clin.* 1996; 14(2): 291-308. doi: 10.1016/s0733-8619(05)70257-7.

3. Gh Popescu BF, Pirko I and Lucchinetti CF. Pathology of multiple sclerosis: where do we stand? *Continuum (Minneapolis, Minn).* 2013; 19(4 Multiple Sclerosis): 901-21. doi: 10.1212/01.CON.0000433291.23091.65.

4. McFarlin DE and McFarland HF. Multiple sclerosis (second of two parts). *N. Engl. J. Med.* 1982; 307(20): 1246-51. doi: 10.1056/ NEJM198211113072005.

5. Walton C, King R, Rechtman L, Kaye W, Leray E, Marrie RA, Robertson N, Rocca NL, Uitdehaag B, der Mei IV, Wallin M, Helme A, Napier CA, Rijke N and Baneke P. Rising prevalence of multiple sclerosis worldwide: Insights from the Atlas of MS. *Mult. Scler. J.* 2020; 26(14): 1816-21. doi: 10.1177/ 1352458520970841.

6. Goldenberg MM. Multiple sclerosis review. *P. T.* 2012; 37(3): 175-84.

7. van Horssen J, Schreibelt G, Bö L, Montagne L, Drukarch B, van Muiswinkel FL and de Vries HE. NAD(P)H:quinone oxidoreductase 1 expression in multiple sclerosis lesions. *Free Radic. Biol. Med.* 2006; 41(2): 311-7. doi: 10.1016/j.freeradbiomed.2006.04.013.

8. Agúndez JAG, García-Martín E, Martínez C, Benito-León J, Millán-Pascual J, Calleja P, María Díaz-Sánchez M, Pisa D, Turpín-Fenoll L, Alonso-Navarro H, Ayuso-Peralta L, Torrecillas D, Plaza-Nieto JF and Jiménez-Jiménez FJ. NQO1gene rs1800566 variant is not associated with risk for multiple sclerosis. *BMC Neurol.* 2014; 14(1): 87. doi: 10.1186/1471-2377-14-87.

9. Komatsu M, Kurokawa H, Waguri S, Taguchi K, Kobayashi A, Ichimura Y, Sou YS, Ueno I, Sakamoto A, Tong KI, Kim M, Nishito Y, Iemura SI, Natsume T, Ueno T, Kominami E, Motohashi H, Tanaka K and Yamamoto M. The selective autophagy substrate p62 activates the stress responsive transcription factor Nrf2

[Downloaded from jmp.ir on 2026-11-28]

[DOI: 10.66224/jmp.25.98.1]

through inactivation of Keap1. *Nat. Cell Biol*. 2010; 12(3): 213-23. doi: 10.1038/ncb2021.

10. Luo J-F, Shen X-Y, Lio CK, Dai Y, Cheng C-S, Liu J-X, Yao Y-D, Yu Y, Xie Y, Luo P, Yao X-Sh, Liu Zh-Q and Zhou H. Activation of Nrf2/HO-1 pathway by Nardochinoid C inhibits inflammation and oxidative stress in Lipopolysaccharide-Stimulated Macrophages. *Front Pharmacol.* 2018; 9. doi: 10.3389/fphar. 2018.00911.

11. Ma Q. Role of nrf2 in oxidative stress and toxicity. A*nnu. Rev. Pharmacol. Toxicol.* 2013; 53: 401-26. doi: 10.1146/annurev-pharmtox-011112-140320.

12. Xu H, Barnes GT, Yang Q, Tan G, Yang D, Chou CJ, Sole J, Nichols A, Ross JS, Tartaglia LA and Chen H. Chronic inflammation in fat plays a crucial role in the development of obesity-related insulin resistance. *J. Clin. Invest* 2003; 112(12): 1821-30. doi: 10.1172/JCI19451.

13. Seminotti B, Grings M, Tucci P, Leipnitz G and Saso L. Nuclear factor Erythroid-2-Related factor 2 signaling in the Neuropathophysiology of inherited metabolic Disorders. *Front. Cell. Neurosci.* 2021; 15. doi: 10.3389/ fncel.2021.785057.

14. Upadhayay S, Mehan S, Prajapati A, Sethi P, Suri M, Zawawi A, Almashjary Mn and Tabrez Sh. Nrf2/HO-1 signaling stimulation through Acetyl-11-Keto-Beta-Boswellic acid (AKBA) provides neuroprotection in ethidium Bromide-Induced experimental model of Multiple Sclerosis. *Genes*. 2022; 13(8). doi: 10.3390/genes13081324.

15. Fiorelli S, Porro B, Cosentino N, Di Minno A, Manega CM, Fabbiocchi F, Niccoli G, Fracassi F, Barbieri S, Marenzi G, Crea F, Cavalca V, Tremoli E and Eligini S. Activation of Nrf2/HO-1 pathway and human Atherosclerotic plaque vulnerability: An in vitro and in vivo study. *Cells*. 2019; 8(4): 356. doi: 10.3390/cells8040356.

16. Fagone P, Patti F, Mangano K, Mammana S, Coco M, Touil-Boukoffa C, Chikovani T, Di Marco R and Nicoletti F. Heme oxygenase-1 expression in peripheral blood mononuclear cells correlates with disease activity in multiple sclerosis. *J. Neuroimmunol.* 2013; 261(1-2): 82-6. doi: 10.1016/j.jneuroim. 2013.04.013.

17. Araujo JA, Zhang M and Yin F. Heme oxygenase-1, oxidation, inflammation, and atherosclerosis. *Front Pharmacol.* 2012; 3: 119. doi: 10.3389/fphar.2012.00119.

18. Rothman N, Smith MT, Hayes RB, Traver RD, Hoener B, Campleman S, Li GL, Dosemeci M, Linet M, Zhang L, Xi L, Wacholder S, Lu W, Meyer KB, Titenko-Holland N, Stewart JT, Yin S and Ross D. Benzene poisoning, a risk factor for hematological malignancy, is associated with the NQO_1 609C→ T mutation and rapid fractional excretion of chlorzoxazone. *Cancer Res.* 1997; 57(14): 2839-42.

19. Tian H, Sun W, Zhang Q, Li X, Sang Y, Li J, Niu Y and Ding H. Procyanidin B2 mitigates behavioral impairment and protects myelin integrity in cuprizone-induced schizophrenia in mice. *RSC Adv.* 2018; 8(42): 23835-46. doi: 10.1039/c8ra03854f.

20. Grajchen E, Wouters E, van de Haterd B, Haidar M, Hardonnière K, Dierckx T, Van Broeckhoven J, Erens C, Hendrix S, Kerdine-Römer S, Hendriks JJA, Bogie JFJ. CD36-mediated uptake of myelin debris by macrophages and microglia reduces neuroinflammation. *J. Neuroinflamm.* 2020; 17: 1-14. doi: 10.1186/s12974-020-01899-x.

21. Stone S, Jamison S, Yue Y, Durose W, Schmidt-Ullrich R and Lin W. NF-κB activation protects oligodendrocytes against inflammation. *JNR.* 2017; 37(38): 9332-44. doi: 10.1523/ JNEUROSCI.1608-17.2017.

[Downloaded from jmp.ir on 2026-11-28]

[DOI: 10.66224/jmp.25.98.1]

22. Yue Y, Stone S and Lin W. Role of nuclear factor κB in multiple sclerosis and experimental autoimmune encephalomyelitis. *Neural Regen. Res.* 2018; 13(9): 1507-15. doi: 10.4103/1673-5374.237109.

23. Giridharan S and Srinivasan M. Mechanisms of NF-κB p65 and strategies for therapeutic manipulation. *J. Inflamm. Res.* 2018; 407-19. doi: 10.2147/JIR.S140188.

24. Hauser SL and Cree BAC. Treatment of multiple sclerosis: A review. *Am. J. Med*. 2020; 133(12): 1380-90.e2. doi: 10.1016/ j.amjmed.2020.05.049.

25. Khaledi E, Noori T, Mohammadi-Farani A, Sureda A, Dehpour AR, Yousefi-Manesh H, Sobarzo-Sanchez E and Shirooie S. Trifluoperazine reduces cuprizone-induced demyelination via targeting Nrf2 and IKB in mice. *Eur. J. Pharmacol* 2021; 909: 174432. doi: 10.1016/j.ejphar.2021.174432.

26. Baradaran Rahimi V, Mousavi SH, Haghighi S, Soheili-Far S and Askari VR. Cytotoxicity and apoptogenic properties of the standardized extract of *Portulaca oleracea* on glioblastoma multiforme cancer cell line (U-87): A mechanistic study. *Excli. J.* 2019; 18: 165-86. doi: 10.17179/excli2019-1063.

27. Qiao JY, Li HW, Liu FG, Li YC, Tian S, Cao LH, Hu k, Wu X-X and Miao M-S. Effects of *Portulaca oleracea* extract on acute alcoholic liver injury of rats. *Molecules.* 2019; 24(16): 2887. doi: 10.3390/molecules24162887.

28. Ahn EY, Lee YJ, Park J, Chun P and Park Y. Antioxidant potential of *Artemisia capillaris*, *Portulaca oleracea*, and *Prunella vulgaris* extracts for biofabrication of gold nanoparticles and cytotoxicity assessment. *Nanoscale Res. Lett.* 2018; 13(1): 348. doi: 10.1186/s11671-018-2751-7.

29. Miao L, Tao H, Peng Y, Wang S, Zhong Z, El-Seedi H, Dragan S, Zengin G, Cheang WS, Wang Y and Xiao J. The anti-inflammatory potential of *Portulaca oleracea* L. (purslane) extract by partial suppression on NF-κB and MAPK activation. *Food Chem.* 2019; 290: 239-45. doi: 10.1016/j.foodchem.2019.04.005.

30. Abdel Moneim AE. The neuroprotective effects of purslane (*Portulaca oleracea*) on rotenone-induced biochemical changes and apoptosis in brain of rat. *CNS Neurol. Disord. Drug Targets.* 2013; 12(6): 830-41. doi: 10.2174/18715273113129990081.

31. Chan K, Islam MW, Kamil M, Radhakrishnan R, Zakaria MN, Habibullah M and Attas A. The analgesic and anti-inflammatory effects of *Portulaca oleracea* L. subsp. Sativa (Haw.) Celak. *J. Ethnopharmacol*. 2000; 73(3): 445-51. doi: 10.1016/s0378-8741(00)00318-4.

32. Jalali J and Ghasemzadeh Rahbardar M. Ameliorative effects of *Portulaca oleracea* L.(purslane) and its active constituents on nervous system disorders: A review. *IJBMS.* 2023; 26(1): 2. doi: 10.22038/ IJBMS.2022. 65764.14464.

33. Lim YY and Quah EP. Antioxidant properties of different cultivars of *Portulaca oleracea*. *Food Chem*. 2007; 103(3): 734-40. doi: 10.1016/j.foodchem.2006.09.025.

34. Ullah HA, Kim T-H, Saba E, Kim SD and Rhee MH. Korean red ginseng and *Portulaca oleracea* extracts attenuate Lipopolysaccharide-induced inflammation via Downregulation of nuclear factor Kappa-B and the Mitogen-activated protein Kinase signaling pathway in macrophage cell line RAW 264.7. *Biomed. Sci. Lett.* 2021; 27(2): 51-8. doi: 10.15616/ BSL.2021.27.2.51.

35. Guoyin Z, Hao P, Min L, Wei G, Zhe C and Changquan L. Antihepatocarcinoma effect of *Portulaca oleracea* L. in mice by PI3K/Akt/mTOR and Nrf2/HO-1/NF-κB

[Downloaded from jmp.ir on 2026-11-28]

[DOI: 10.66224/jmp.25.98.1]

pathway. *eCAM*. 2017; 2017(1): 8231358. doi: 10.1155/2017/8231358.

36. Baradaran Rahimi V, Ajam F, Rakhshandeh H and Askari VR. A pharmacological review on *Portulaca oleracea* L.: Focusing on anti-inflammatory, anti-oxidant, immuno-modulatory and antitumor activities. *J. Pharmacopunct.* 2019; 22(1): 7-15. doi: 10.3831/KPI.2019.22.001.

37. Torkildsen Ø, Brunborg LA, Myhr K-M and Bø L. The cuprizone model for demyelination. *Acta Neurol. Scand. Suppl.* 2008; 188: 72-6. doi: 10.1111/j.1600-0404.2008.01036.x.

38. Zirngibl M, Assinck P, Sizov A, Caprariello AV and Plemel JR. Oligodendrocyte death and myelin loss in the cuprizone model: an updated overview of the intrinsic and extrinsic causes of cuprizone demyelination. *Mol. Neurodegener.* 2022; 17(1): 34. doi: 10.1186/s13024-022-00538-8.

39. Oveland E, Ahmad I, Lereim RR, Kroksveen AC, Barsnes H, Guldbrandsen A, Myhr K-M, Bø L, Berven FS and Wergeland S. Cuprizone and EAE mouse frontal cortex proteomics revealed proteins altered in multiple sclerosis. *Sci. Rep*. 2021; 11(1): 7174. doi: 10.1038/s41598-021-86191-5.

40. Praet J, Guglielmetti C, Berneman Z, Van der Linden A and Ponsaerts P. Cellular and molecular neuropathology of the cuprizone mouse model: Clinical relevance for multiple sclerosis. *Neurosci. Biobehav. Rev.* 2014; 47: 485-505. doi: 10.1016/j.neubiorev.2014.10.004.

41. Valdez-Uriostegui LA, Sánchez-García AD, Zamilpa A, Sánchez JE, González-Garduño R, Mendoza-de-Gives P, Castañeda-Ramirez GS, González-Cortázar M and Aguilar-Marcelino L. In vitro evaluation of hydroalcoholic extracts of mycelium, basidiomata and spent substrate of *Pleurotus ostreatus* against Haemonchus contortus. *Trop. Subtrop. Agroecosystems.* 2021; 24(2). doi: 10.56369/tsaes.3272.

42. Kipp M, Clarner T, Dang J, Copray S and Beyer C. The cuprizone animal model: new insights into an old story. *Acta Neuropathol.* 2009; 118(6): 723-36. doi: 10.1007/s00401-009-0591-3.

43. Mandolesi G, Bullitta S, Fresegna D, De Vito F, Rizzo FR, Musella A, Guadalupi L, Vanni V, Stampanoni Bassi M, Buttari F, Viscomi MT, Centonze D and Gentile A. Voluntary running wheel attenuates motor deterioration and brain damage in cuprizone-induced demyelination. *Neurobiol. Dis.* 2019; 129: 102-17. doi: 10.1016/j.nbd.2019.05.010.

44. Noori T, Dehpour AR, Alavi SD, Hosseini SZ, Korani S, Sureda A, Esmaeili J and Shirooie S. Synthesis and evaluation of the effects of solid lipid nanoparticles of ivermectin and ivermectin on cuprizone-induced demyelination via targeting the TRPA1/NF-kB/GFAP signaling pathway. *Iran. J. Basic Med. Sci.* 2023; 26(11): 1272-1282. doi: 10.22038/IJBMS.2023.71309.15493.

45. Dehpour AR, Khaledi E, Noori T, Mohammadi-Farani A, Delphi L, Sureda A, Sobarzo-Sanchez E and Shirooie S. Dapsone reduced cuprizone-induced demyelination via targeting Nrf2 and IKB in C57BL/6 mice. *Iran. J. Basic Med. Sci.* 2022; 25(6): 675-82. doi: 10.22038/IJBMS.2022.64993.14310.

46. Ghorani V, Saadat S, Khazdair MR, Gholamnezhad Z, El-Seedi H and Boskabady MH. Phytochemical characteristics and anti-inflammatory, immunoregulatory, and antioxidant effects of *Portulaca oleracea* L.: A comprehensive review. *eCAM.* 2023; 2023(1): 2075444. doi: 10.1155/2023/2075444.

47. Hassan SF, Ghoneim AI, Ghareeb DA and Nematalla HA. *Portulaca oleracea* L. (purslane)

[Downloaded from jmp.ir on 2026-11-28]

[DOI: 10.66224/jmp.25.98.1]

improves the anti-inflammatory, antioxidant and autophagic actions of metformin in the hippocampus of diabetic demented rats. *Fitoterapia.* 2023; 168: 105566. doi: 10.1016/j.fitote.2023.105566.

48. Mathur D, Rout S, Mishra BK, Rodas GL, Vallamkondu J, Kandimalla R and Casanova B. Potential Pathological biomarkers in multiple Sclerosis. 2020. doi: 10.20944/ preprints 202009.0293.v1.

49. Abdi M, Pasbakhsh P, Shabani M, Nekoonam S, Sadeghi A, Fathi F, Abouzaripour M, Mohamed W, Zibara K, Ragerdi Kashani I and Zendedel A. Metformin therapy attenuates pro-inflammatory microglia by inhibiting NF-κB in cuprizone demyelinating mouse model of multiple sclerosis. *Neurotox. Res.* 2021; 39: 1732-46. doi: 10.1007/s12640-021-00417-y.

50. Sen MK, Almuslehi MSM, Coorssen JR, Mahns DA and Shortland PJ. Behavioural and histological changes in cuprizone-fed mice. *BBI.* 2020; 87: 508-23. doi: 10.1016/ j.bbi.2020. 01.021.

51. He Y, Long H, Zou C, Yang W, Jiang L, Xiao Z, Li Q and Long Sh. Anti-nociceptive effect of *Portulaca oleracea* L. ethanol extracts attenuated zymosan-induced mouse joint inflammation via inhibition of Nrf2 expression. *Innate Immun.* 2021; 27(3): 230-9. doi: 10.1177/1753425921994190.

52. Zhang Y, Bi X, Adebiyi O, Wang J, Mooshekhian A, Cohen J, Wei Z, Wang F and Li X-M. Venlafaxine improves the cognitive impairment and depression-like behaviors in a cuprizone mouse model by alleviating demyelination and neuroinflammation in the brain. *Front Pharmacol.* 2019; 10: 332. doi: 10.3389/fphar.2019.00332.

53. Babbs RK, Beierle JA, Yao EJ, Kelliher JC, Medeiros AR, Anandakumar J, Shah AA, Chen MM, Johnson WE and Bryant CD. The effect of the demyelinating agent cuprizone on binge-like eating of sweetened palatable food in female and male C57BL/6 substrains. *Appetite*. 2020; 150: 104678. doi: 10.1016/j.appet. 2020.104678.

54. Aziz WM, Ahmed SA, Shaker SE, Fayed DB, Metwally NS and Shawky H. *Portulaca oleracea* L seed extracts counteract diabetic nephropathy through SDF-1/IL10/PPARγ–mediated tuning of keap1/Nrf2 and NF-κB transcription in Sprague Dawley rats. *Diabetol. Metab. Syndr.* 2024; 16(1): 119. doi: 10.1186/s13098-024-01330-y.

How to cite this article: Noori T, Hosseini SZ, Korani S, Alavi SD, Heidarizade N, Mohammadi-Farani A, Shirooie S. Therapeutic effect of hydroalcoholic extract of *Portulaca oleracea* against cuprizone-induced demyelination by targeting Nrf2/HO-1/NQO-1/NF-kB in C57BL/6 mice. ***Journal of Medicinal Plants*** 2026; 25(98): 1-16.
doi: 10.66224/jmp.25.98.1

[Downloaded from jmp.ir on 2026-11-28]

[DOI: 10.66224/jmp.25.98.1]