




Institute of
Medicinal Plants

Journal of Medicinal Plants

Journal homepage: www.jmp.ir



Research Article

Wound healing activity of the flowers of *Lilium candidum* L. in burn wound model in rats

Saeideh Momtaz¹, Mahshid Dibaj², Alireza Abdollahi³, Gholamreza Amin⁴, Roodabeh Bahramsoltani⁵, Mohammad Abdollahi⁶, Parvin Mahdavi⁷, Amir Hossein Abdolghaffari^{2,8,*}

¹ Medicinal Plants Research Center, Institute of Medicinal Plants, ACECR, Karaj, Iran

² Department of Toxicology & Pharmacology, Faculty of Pharmacy, Tehran Medical Sciences, Islamic Azad University, Tehran, Iran

³ Department of Pathology, Imam Hospital, Tehran University of Medical Sciences, Tehran, Iran

⁴ Department of Pharmacognosy, Faculty of Pharmacy, Tehran University of Medical Sciences, Tehran, Iran

⁵ Department of Traditional Pharmacy, School of Persian Medicine, Tehran University of Medical Sciences, Tehran, Iran

⁶ Department of Toxicology and Pharmacology, Faculty of Pharmacy, Tehran University of Medical Sciences, Tehran, Iran

⁷ Department of Pharmaceutics, Faculty of Pharmacy, Tehran University of Medical Sciences, Tehran, Iran

⁸ Gastrointestinal Pharmacology Interest Group (GPIG), Universal Scientific Education and Research Network (USERN), Tehran, Iran

ARTICLE INFO

Keywords:

Lilium candidum

Burn

Flavonoids

Phenols

Wound healing

ABSTRACT

Background: Ethnomedicinal plants are of interest for treatment of various wound types. **Objective:** This study aimed to evaluate burn wound healing potential of the hydro-alcoholic extract of the flowers of *Lilium candidum* L. in rats. **Methods:** DPPH free radical scavenging power, total flavonoids, and the phenolic content of the extract were evaluated. Following burn wound induction, 30 Wistar rats were divided into 5 groups; silver sulfadiazine cream 1% (reference standard), eucerin (control), and 5%, 10% and 20% ointments of *L. candidum* flowers extract (treatment groups). Wound contraction and the percentage of wound healing were measured every day until 14th day and the histological changes were evaluated. **Results:** DPPH assay of *L. candidum* extract indicated high antioxidant activity. Total phenolic content of *L. candidum* extract was equal to 157 mg gallic acid equivalent/g; while total flavonoid was measured as 32.4 mg quercetin equivalent/g dried extract. The mean of wound area was significantly different in three 5%, 10% and 20% extract-treated rats in comparison with the control. Although, 20% ointment of *L. candidum* flowers extract demonstrated the best wound healing improvement, even better than silver sulfadiazine. Histopathological analysis confirmed the wound healing activity of *L. candidum* and promoting tissue repair, especially for the ointment containing 20% extract. **Conclusion:** Regarding the high content of phenolic compounds and flavonoids, besides potent antioxidant properties of the flowers of *L. candidum*, the use of its ointments led to significant decrease of burn wound area, suggesting that these extract ointments can treat burn wounds and improve the healing processes.

Abbreviations: HSV, Herpes Simplex Virus-1; DPPH, 2, 2-diphenyl-1-picrylhydrazyl; BHA, Butylated hydroxyanisole; AlCl₃, Aluminium chloride; NaOH, Sodium hydroxide; SSD, Silver Sulphadiazine; IP, intra peritoneal; VEGF, vascular endothelial growth factor; TGF- β , Ang-1/Tie-2, transforming growth factor beta

* Corresponding author: amirhosein172@hotmail.com

doi: 10.29252/jmp.1.73.109

Received 20 August 2019; Received in revised form 9 December 2019; Accepted: 7 January 2020

© 2020. Open access. This article is distributed under the terms of the Creative Commons Attribution-NonCommercial 4.0 International License (<https://creativecommons.org/licenses/by-nc/4.0/>)

1. Introduction

Burn is a kind of skin or tissue injury caused by heat, electricity, chemicals, or radiation [1]. The severity of burns can be specified by the depth and the degree of skin damage [2]. Burns that only involve the outer layer of the skin (epidermis) is known as the first-degree burn. In this type of burn, skin usually become red and very painful with an obvious dry appearance [3]. In second-degree burns, both the epidermis and the second layer of the skin (dermis) are involved, inducing white or red color, pain, swelling, and dryness. In third-degree burns, there is a destruction in all layers of the skin with dry appearance and no pain [4]. Burn injuries may cause physical disabilities as well as mental and emotional illness, even sometimes there is a possibility of mortality [5, 6]. The healing process includes inflammatory, proliferative and remodeling phases [7], nevertheless, burn healing is an ongoing challenge in modern medicine [1]. Despite the existence of various chemical products for burn treatment, there is a growing trend for natural products and traditional medicine worldwide [8]. In a comprehensive review, Bahramsoltani et al. reported that single herbal preparations including *Allium sativum*, *Aloe vera*, *Centella asiatica*, and *Hippophae rhamnoides* were the most effective species for burn wound healing [9]. Herbal-based remedies/medications with potent antioxidant and anti-inflammatory activities are frequently used to treat burn injuries, and can accelerate the healing process [10].

Lilium candidum L. (popularly known as the Madonna lily) from Liliaceae, is confirmed to improve the symptoms of a variety of ulcers, inflammations, wounds, and burns. Yet, there are limited data about the phytochemical composition of the plant [11, 12]. *L. candidum* contains important phytochemicals; mainly

flavonoids (quercetin, isorhamnetin, kaempferol) and other phytochemicals such as organic acids, glycosides, nitrogenous, steroidal compounds, saponins, and jatrophan [11, 13, 14]. Moreover, white lily flowers are rich in carotenoids, anthocyanins, phenyl propanoids, and essential oil components [15, 16]. The extracts of *L. candidum* were found to possess antibacterial, antifungal, antioxidant, anti-tumor, and anti-yeast activities [17-20]. In traditional medicine, the flowers of *L. candidum* were known to have anti-inflammatory properties [21]. It is believed that the flavonoid constituents of lily flowers are responsible for its anti-inflammatory activities, which was attributed to the cyclooxygenase inhibition [22].

It was evidenced that the leaf extract of *L. candidum* strongly inhibited the Herpes Simplex Virus-1 (HSV) - 1, while slightly affected HSV-2 [23]. In folk medicine, the whole parts of the plant were used to lighten the skin, especially for periocular hyperpigmentation [11, 24]. The steroidal glycosides isolated from Easter lily (*L. longiflorum*) bulbs enhanced the dermal fibroblast migration activity, a model for the early events in wound healing [7]. In this paper, the wound healing property of an ointment containing the hydro-alcoholic extract of *L. candidum* in rats, besides, its antioxidant effects and phenolic content are reported.

2. Materials and Methods

2.1. Chemicals

2,2- diphenyl-1- picryl- hydrazyl- hydrate (DPPH), Folin ciocalteu, Butylated hydroxyanisole (BHA) were purchased from Sigma Chemical Company (USA). Aluminium chloride ($AlCl_3$), Sodium hydroxide (NaOH), Sodium nitrite ($NaNO_2$), Sodium bicarbonate, Gallic acid, Ethanol, Formalin, Ketamine, Xylazine were provided by Merck company

(Germany). Eucerin (Farabi, Iran) and Silver Sulphadiazine (SSD) 1% cream (Najo, Iran) were purchased from Iranian companies.

2.2. Plant materials

Flowers of *L. candidum* were collected during February 2015 from a local flower market in south of Tehran province, Iran, and were identified by Professor Gh. Amin. Voucher specimen was deposited at the herbarium of the Faculty of Pharmacy, Tehran University of Medical Science, Tehran, Iran (No: 7072-TEH).

2.3. Extraction

Flowers were shadow-air-dried at room temperature and 120 g of dried flowers were pulverized, and extracted using the percolation method. Every 24 hours, three sequential extractions were performed, using a mixture of ethanol/water (70:30 v/v). The extract was concentrated by a rotary vacuum evaporator (50 °C, 100 rpm) [20].

2.4. DPPH free radical scavenging activity

The DPPH scavenging activity was measured following the method published by Fahimi et al., 2015 [5, 25]. The experiment was carried out in triplicate and methanol was used as blank. The radical scavenging activity was calculated as the percentage of DPPH discoloration using following formula:

$$\text{Inhibition (\%)} = 100 - \frac{(\text{sample absorbance} - \text{control absorbance})}{(\text{blank absorbance})}$$

Where the sample absorbance is the absorbance of different extract concentrations mixed with DPPH, the control absorbance is the absorbance of the mixture of the extract and methanol, and the blank absorbance considered as the absorbance of DPPH with ethanol without any extract.

2.5. Total phenol assay

The phenolic content of the plant extract was determined using Folin-ciocalteu reagent, and the total phenolic content was expressed as gallic acid equivalent/g extract [26].

2.6. Total flavonoids assay

The reaction mixture contained the extract, 70% ethanol, and NaNO₂. After a while, AlCl₃ and NaOH were added, and later, the absorbance was measured at 510 nm against the blank [27]. Total flavonoid content was expressed as microgram (µg) quercetin equivalent in mg extract (µg quercetin/mg extract).

2.7. Preparation of the ointment

The ointment was prepared using 5%, 10%, and 20% of *L. candidum* extract in an eucerin base (25%), while SSD cream 1% was used as the reference standard. The concentrations of the extract were selected based on data obtained by our pilot study.

2.8. Animal study

Male Wistar rats (N= 30, 6 in each group, 200 ± 30 g) were kept under standard conditions; temperature (25 ± 1 °C), humidity (55% ± 10%), and 12/12 hours (h) light/dark cycle with full access to the standard pellet diet and tap water. Animals were kept in accordance with the instructions provided by the Tehran University of Medical Sciences Review Board and the experiments were performed following the approval of ethical committee of animal experimentation, Tehran University of Medical Sciences (TUMS), Tehran, Iran. Animals were anaesthetized by intra peritoneal (IP) injection of ketamine/xylazine. The dorsal part of the skin was shaved and a full-thickness circular 1cm diameter second degree burn wound was created using an electrical heater (110 °C heat for 10 sec) [5].

Rats were divided into 5 groups including; SSD cream 1% as the reference standard, eucerin as the control, and 5 %, 10 % and 20 % ointments of *L. candidum* flowers extract as the treatment groups, starting right after burn wound induction. Ointments were used topically over the wounds every day for 14 days [5]. The wounds areas were cleaned, photographed with a digital camera and calculated using Adobe Photoshop CS5. The wound contraction rate was measured according to this formula:

Wound contraction % = $100 \times [(first\ day\ wound\ area - specific\ wound\ area) / first\ day\ wound\ area]$

On the day 14 (the end of experiment), animals were sacrificed, the granulated tissues were collected, and preserved in buffered formalin 10% to evaluate the histological changes. Series of 3-4 μ m thickness sections were

prepared for each sample, stained with hematoxylin/eosin, and microscopic photographs were captured under $\times 400$ magnification.

2.9. Statistical analysis

Data were analyzed using the SPSS 20 software (one-way ANOVA and Tukey's *Post hoc* test). $P \leq 0.05$ were statistically considered significance.

3. Results

3.1. Plant material yield

The extraction procedure yielded to 51.1% dry extract.

3.2. DPPH free radical scavenging activity

The 50% inhibitory concentration of DPPH radical scavenging activity was equal to 248 mg/ml (Table 1).

Table 1. The antioxidant content of *L. candidum* extract

DPPH IC ₅₀ (mg/ml)	Total phenol (mg of gallic acid equivalent/g extract)	Total flavonoids (mg of quercetin equivalent/g extract)
248	157	32.4

DPPH: 1, 1-diphenyl-2-picrylhydrazyl, IC₅₀: inhibitory concentration 50%

3.3. Total phenols

Total phenolic content of *L. candidum* extract was calculated using standard curve of gallic acid ($y=0.454x+0.139$, $R^2=0.997$), which was equal to 157 mg gallic acid /g dried extract (Table 1).

3.4. Total flavonoids

Total flavonoid content was measured as 32.4 mg quercetin equivalent/g dried extract using this formula:

$$y = 0.002x + 0.0227$$

Y is the absorbance of solution at 510 nm, X is total flavonoid content of the extract as μ g quercetin equivalent in mg extract (Table 1).

3.5. Rate of wound healing

The percentage of wound healing enhanced in all animal treated groups during 14 days of the study. The wound area was significantly reduced in rats treated with *L. candidum* ointment compared with both positive and negative controls ($P < 0.001$). On the 14th day, 20% extract group exhibited the best wound healing effect in comparison with other groups ($P < 0.001$). Table 1 shows the rate of wound healing in *L. candidum* ointment treated groups (Table 2).

3.6. Histopathological analysis

In SSD treated group, the wound has almost been repaired and the epidermal layer is completely formed. In some areas, layers were

thin. Epidermal and dermal junction folder (that support the skin), and the auxiliary parts such as hair follicles were not formed. Collagen bundles were formed in most parts of the dermal layers, although it was less than that of the 20% group. Tissue inflammation was significantly diminished; but the inflammatory cells are still observed in some areas. In non-treated group, the wound area has not been repaired with significant depth. Extensive hyperemia and inflammation and copious exudate are seen. Granulation tissue at rim of the wound is under development (Fig. 1).

Wound was covered with granulation tissue in rats treated with ointment containing 5% extract. Wound depth was less than the control group; however, the inflammation and hyperemia are still

significant. Epidermal repairing was started at rim of the wound and collagen bundles are not observed in dermal layers. The application of 10% extract caused a complete wound healing in this group. The epidermis was completely formed, but in some areas was thin. Epidermal and dermal junction folder and the auxiliary parts were not formed. Collagen bundles have been disappeared in dermal layers. Tissue inflammation and hyperemia are still observed in most areas. In group of ointment with 20% extract, wound was repaired, and the epidermal layer was completely formed. Epidermal and dermal junctions were formed in most areas, and a few hair follicles grown. Collagen bundles were formed in most parts of the dermal layers, and tissue inflammation was significantly diminished (Fig. 1).

Table 2. Wound healing percentage in experimental groups

Groups	14th day
Control	56 ± 0.035
SSD	73.5 ± 0.018 ^a
5% Extract	80.6 ± 0.027 ^a
10% Extract	89 ± 0.066 ^{a,b,c}
20% Extract	94 ± 0.048 ^{a,b,d}

Values are presented as Mean ± SEM

Abbreviations: SSD, silver sulfadiazine

^a significantly different from control, P < 0.001

^b significantly different from SS, P < 0.001

^c significantly different from 5%, P < 0.05

^d significantly different from 5%, P < 0.001

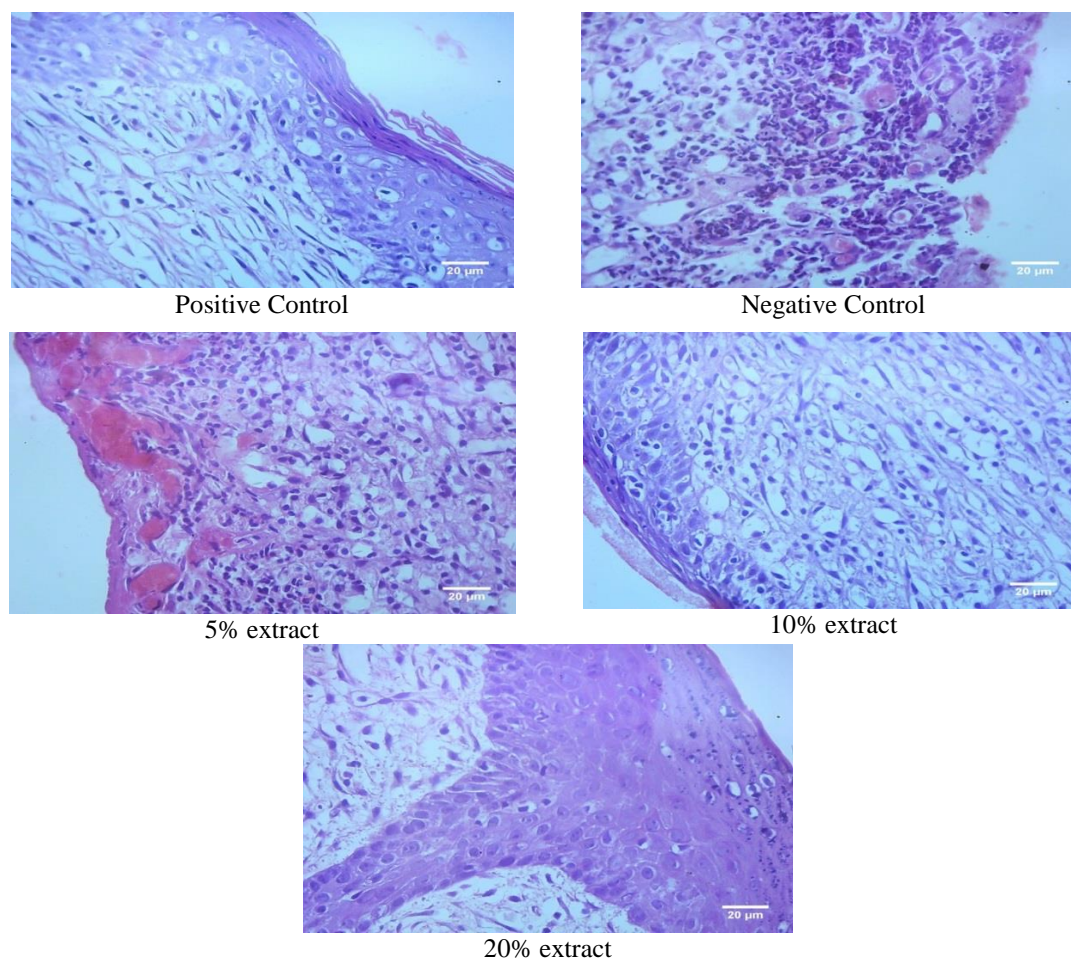


Fig. 1. Microscopic examination of skin tissue samples with magnification of $\times 400$ (Day 14th).

4. Discussion

Wound healing refers to a sequence of complicated events including inflammation, re-epithelialization, granulation, neovascularization, and wound contraction. Upon a thermal injury, neutrophils accumulate at the lesion site, which stimulate the reactive oxygen species (ROS), and the proteases overproduction. This can trigger the release of the interstitial fluid, leading to the endothelial cells, and skin damage. Excessive production of free radicals and proteases impairs the production and release of growth and angiogenic growth factors from macrophages and keratinocytes, delaying skin repair.

In this manner, herbal-based formulations containing a variety of phytochemicals with

remarkable efficacy and safety can interfere the wound healing process by means of antimicrobial, anti-inflammatory, antioxidant, collagen synthesis stimulation, cell proliferative, and angiogenic effects [9]. Well-orchestrated alliance between various cells (i.e. immunocytes, macrophages, neutrophils, lymphoid cells), local release of various growth factors, and cytokines can affect the rate of wound repair; while disruption in this process causes delayed wound healing [28]. Due to their broad vulnerability for infections, burn wounds require fast treatment. Up to date, many topical preparations have been formulated; however, instead of wound healing properties, most of them possess antimicrobial activities and may have insufficient efficacy and

can induce toxicity (i.e. SSD) [29]. Both plant extracts and a series of phytochemicals (i.e. alkaloids, flavonoids, terpenes, glycosides) showed pro-wound healing effects *in vivo* and *in vitro* models, and are of great interest, mainly due to their non-toxic properties. In addition, herbal preparations are able to interfere in each and every steps of wound healing phases [30]. Therefore, there is constant request for therapeutic strategies to treat general and chronic ulcers, particularly burn wounds, diabetic foot ulcers, venous and arterial leg ulcers, and pressure ulcers.

Topical application of the ointment of 20% extract showed the highest wound healing properties *in vivo* in comparison with all other test materials. In addition to the better result compared with the control, the ointment of 20% *L. candidum* extract demonstrated a significant enhancement of wound closure percentage, even higher than that of the positive control group. In the context of wound areas, there were considerable developments of re-epithelialization, cell proliferation, and migration in 20% *L. candidum* extract treated group.

As mentioned, flavonoids are the main constituents of the genus *Lilium*. In addition, flavonoid compounds are famous for their significant antioxidant potentials. There are various evidence confirming the effectiveness of flavonoids in managing the chronic foot ulcers [31]. Treatment with hesperidin, a flavonoid compound abundantly present in citrus species, enhanced the angiogenesis, and vasculogenesis via up-regulation of relevant genes (i.e. vascular endothelial growth factor (VEGF), Ang-1/Tie-2, transforming growth factor beta (TGF- β), and Smad-2/3) mRNA expressions, representative of wound healing in chronic diabetic foot ulcers in rats [32]. Lidhi et al. suggested that an ointment containing flavonoid-rich fractions of *Martynia*

annua and *Tephrosia purpurea* were more effective than isolated flavonoids in wound healing, which was attributed to the synergistic interactions between the flavonoids and other constituents [33]. The main mechanism that flavonoids coordinate in wound healing is proposed to be collagen synthesis and/or degradation including the acceleration of collagen synthesis, decrease of soluble collagen degradation, and inhibition of catabolism of soluble collagen. It is worth mentioning that clinically, collagen deposition in wound sites is the most important phase of healing [34], whereby the high flavonoid content of *L. candidum* might be a possible explanation for its wound healing property. On the other hand, DPPH radical scavenging activity and the high phenolic content of the extract, make it an eligible candidate for burn wound healing through an antioxidant mechanism. In accordance, previous studies have also confirmed the antioxidant properties of many species of genus *Lilium* [35, 36]. It has been well established that oxidative stress impairs the wound healing process, in turn, the antioxidant agents accelerate the repair stages and increase the healing potential [37, 38]. Overall, special chemical composition of the flowers of *L. candidum* in concomitant with its antioxidant, antibacterial, and anti-inflammatory assets leads to wound healing improvement in rats.

5. Conclusion

In terms of histopathological evaluations, the ointment of 20% *L. candidum*-treated wounds showed better granulation tissue, empowered by thick regenerated epithelial layer. These findings reveal that the high phenolic and flavonoid contents of *L. candidum*, besides its known antioxidant potential caused significant burn wound healing in rats. However, future studies

should focus on the antibacterial and anti-inflammatory properties of this species. Further, the mechanistic examination of the molecular and cellular pathways behind the wound healing effect of *L. candidum* is emerging.

Author contributions

Mahshid Dibaj, Roodabeh Bahramsoltani, and Parvin Mahdavian: Conduction of practical parts, collection and/or assembly of data and interpretation, manuscript writing; Alireza Abdollahi: Pathophysiological assessment;

Gholamreza Amin: plant material collection and identification; Saeideh Momtaz, Mohammad Abdollahi and Amir Hossein Abdolghaffari: provision of study material, conception and design, and final approval of manuscript. All the authors have read and approved the manuscript.

Conflict of interest

The authors declare that there is no conflict of interest.

References

1. Kahkeshani N, Farahanikia B, Mahdavian P, Abdolghaffari A, Hassanzadeh G, Abdollahi M and Khanavi M. Antioxidant and burn healing potential of *Galium odoratum* extracts. *Res. Pharm. Sci.* 2013; 8 (3): 197.
2. Kwansang J, Itthipanichpong C and Limpanasithikul W. Evaluation of wound healing activity of *Thunbergia laurifolia* supercritical carbon dioxide extract in rats with second-degree burn wounds. *J. Adv. Pharm. Technol. Res.* 2015; 6 (3): 103.
3. Hanson RR. Management of burn injuries in the horse. *Veterinary Clinics of North America-Equine Practice.* 2005; 21 (1): 105-24.
4. Palmieri TL and Greenhalgh DG. Topical treatment of pediatric patients with burns. *Am. J. Clin. Dermatol.* 2002; 3 (8): 529-34.
5. Fahimi S, Abdollahi M, Mortazavi SA, Hajimehdipoor H, Abdolghaffari AH and Rezvanfar MA. Wound healing activity of a traditionally used poly herbal product in a burn wound model in rats. *Iran. Red Crescent. Med. J.* 2015; 17 (9): e19960.
6. Tanideh N, Haddadi MH, Rokni-Hosseini MH, Hossienzadeh M, Mehrabani D, Sayehmiri K and et al. The healing effect of *scrophularia striata* on experimental burn wounds infected to pseudomonas aeruginosa in rat. *WJPS.* 2015; 4 (1): 16.
7. Esposito D, Munafo JP, Lucibello T, Baldeon M, Komarnytsky S and Gianfagna TJ. Steroidal glycosides from the bulbs of Easter lily (*Lilium longiflorum* Thunb.) promote dermal fibroblast migration *in vitro*. *J. Ethnopharmacol.* 2013; 148 (2): 433-40.
8. Kumar B, Vijayakumar M, Govindarajan R and Pushpangadan P. Ethnopharmacological approaches to wound healing-exploring medicinal plants of India. *J. Ethnopharmacol.* 2007; 114 (2): 103-13.
9. Bahramsoltani R, Farzaei MH and Rahimi R. Medicinal plants and their natural components as future drugs for the treatment of burn wounds: an integrative review. *Arch. Dermatol. Res.* 2014; 306 (7): 601-17.
10. de Campos EP, Trombini LN, Rodrigues R, Portella DL, Werner AC, Ferraz MC and et al. Healing activity of *Casearia sylvestris* Sw. in second-degree scald burns in rodents. *BMC Res. Notes.* 2015; 8 (1): 269.
11. Loy CJ, Mahmood K and Saliou C. Compositions comprising *Lilium candidum* extracts and uses thereof. Google Patents; 2013. <https://patents.google.com/patent/US8481093B2/en>.
12. Kopaskova M, Hadjo L, Yankulova B, Jovtchev G, Galova E, Sevcovicova A and et al. Extract of *Lillium candidum* L. can modulate the

- genotoxicity of the antibiotic zeocin. *Molecules* 2012; 17 (1): 80-97.
- 13.** Eisenreichová E, Haladová M, Mučaji P and Grančai D. The study of constituents of *Lilium candidum* L. *Acta Facult. Pharm. Univ. Comenianae* 2004; 51: 27-37.
- 14.** Patočka J, Navratilova Z and Yokozawa T. Bioactivity of *Lilium candidum* L-A Mini Review. *Biomedical Journal of Scientific & Technical Res.* 2019; 18 (5): 13859-62.
- 15.** Nørbæk R and Kondo T. Anthocyanins from flowers of *Lilium* (Liliaceae). *Phytochemistry* 1999; 50 (7): 1181-4.
- 16.** Usher G. A dictionary of plants used by man. 1974; 619 Seiten. Constable and Company Ltd., London.
- 17.** Mučaji P, Haladova M, Eisenreichova E, Sersen F, Ubik K and Grancai D. Constituents of *Lilium candidum* L. and their antioxidative activity. *Ceska a Slovenska Farmacie* 2007; 56 (1): 27-9.
- 18.** Mučaji P, Hudecova D, Haladova M and Eisenreichova E. Anti-yeast activity of ethanol extracts of *Lilium candidum* L. *Ceska a Slovenska Farmacie* 2002; 51 (6): 297-300.
- 19.** Vackuková A, Esenreichov E, Haladova M, Muci P, Józová B and Novor L. Potential carcinogenic and inhibitory activity of compounds isolated from *Lilium candidum* L. *Neoplasma*. 2000; 47 (5): 313-8.
- 20.** Bonjar S. Evaluation of antibacterial properties of some medicinal plants used in Iran. *J. Ethnopharmacol.* 2004; 94 (2): 301-5.
- 21.** Picci V. The exploitation of medicinal plants of the Mediterranean area. *J. Ethnopharmacol.* 1980; 2 (1): 81-9.
- 22.** Francis JA, Rumbelha W and Nair MG. Constituents in Easter lily flowers with medicinal activity. *Life Sciences* 2004; 76 (6): 671-83.
- 23.** Yarmolinsky L, Zaccai M, Ben-Shabat S, Mills D and Huleihel M. Antiviral activity of ethanol extracts of *Ficus binjamina* and *Lilium candidum* in vitro. *N. Biotechnol.* 2009; 26 (6): 307-13.
- 24.** Alsaad S and Mikhail M. Periocular hyperpigmentation: a review of etiology and current treatment options. *J. Drugs Dermatol.* 2013; 12 (2): 154-7.
- 25.** Momtaz S, Hussein AA, Ostad SN, Abdollahi M and Lall N. Growth inhibition and induction of apoptosis in human cancerous HeLa cells by *Maytenus procumbens*. *Food Chem. Toxicol.* 2013; 51: 38-45.
- 26.** Bahramsoltani R, Farzaei MH, Abdolghaffari AH, Rahimi R, Samadi N, Heidari M and et al. Evaluation of phytochemicals, antioxidant and burn wound healing activities of *Cucurbita moschata* Duchesne fruit peel. *Iranian J. Basic Medical Sciences* 2017; 20 (7): 798.
- 27.** Olajire A and Azeez L. Total antioxidant activity, phenolic, flavonoid and ascorbic acid contents of Nigerian vegetables. *African J. Food Science and Technol.* 2011; 2 (2): 22-9.
- 28.** Goswami S, Kandhare A, Zanwar AA, Hegde MV, Bodhankar SL, Shinde S and et al. Oral l-glutamine administration attenuated cutaneous wound healing in Wistar rats. *Int. Wound J.* 2016; 13 (1): 116-24.
- 29.** Hassanzadeh G, Hajmanouchehri F, Roi A, Hassanzadeh N, Shafigh N, Barzroudpour M and et al. Comparing effects of Silver sulfadiazine, Sucralfate and Brassica oleracea extract on burn wound healing. *Life Science J.* 2013; 10 (supp.): 104-13.
- 30.** Budovsky A, Yarmolinsky L and Ben-Shabat S. Effect of medicinal plants on wound healing. *Wound Repair Regen.* 2015; 23 (2): 171-83.
- 31.** Antunes-Ricardo M, Gutierrez-Urbe J and O Serna-Saldivar S. Anti-inflammatory glycosylated flavonoids as therapeutic agents for treatment of diabetes-impaired wounds. *Curr. Top. Med. Chem.* 2015; 15 (23): 2456-63.

32. Li W, Kandhare AD, Mukherjee AA and Bodhankar SL. Hesperidin, a plant flavonoid accelerated the cutaneous wound healing in streptozotocin-induced diabetic rats: role of TGF- β /Smads and Ang-1/Tie-2 signaling pathways. *EXCLI J.* 2018; 17: 399.

33. Lodhi S, Jain A, Jain AP, Pawar RS and Singhai AK. Effects of flavonoids from *Martynia annua* and *Tephrosia purpurea* on cutaneous wound healing. *Avicenna J. Phytomed.* 2016; 6 (5): 578.

34. İnan A, Şen M, Koca C, Akpınar A and Dener C. The effect of purified micronized flavonoid fraction on the healing of anastomoses in the colon in rats. *Surg. Today* 2006; 36 (9): 818-22.


35. Gao J, Zhang T, Jin Z-Y, Xu X-M, Wang J-H, Zha X-Q and et al. Structural characterisation, physicochemical properties and antioxidant activity of polysaccharide from *Lilium lancifolium* Thunb. *Food Chem.* 2015; 169: 430-8.

36. Jin L, Zhang Y, Yan L, Guo Y and Niu L. Phenolic compounds and antioxidant activity of bulb extracts of six *Lilium* species native to China. *Molecules* 2012; 17 (8): 9361-78.

37. Kant V, Gopal A, Pathak NN, Kumar P, Tandan SK and Kumar D. Antioxidant and anti-inflammatory potential of curcumin accelerated the cutaneous wound healing in streptozotocin-induced diabetic rats. *Int. Immunopharmacol.* 2014; 20 (2): 322-30.

38. Alvarez-Suarez JM, Giampieri F, Cordero M, Gasparri M, Forbes-Hernández TY, Mazzoni L and et al. Activation of AMPK/Nrf2 signalling by Manuka honey protects human dermal fibroblasts against oxidative damage by improving antioxidant response and mitochondrial function promoting wound healing. *J. Functional Foods* 2016; 25: 38-49.

How to cite this article: Dibaj M, Momtaz S, Abdollahi AR, Amin GhR, Bahramsoltani R, Abdollahi M, Mahdavian P, Abdolghaffari AH. Wound healing activity of the flowers of *Lilium candidum* L. in burn wound model in rats. *Journal of Medicinal Plants* 2020; 19(73): 109-118.
doi: 10.29252/jmp.1.73.109



فصلنامه گیاهان دارویی

Journal homepage: www.jmp.irپژوهشکده گیاهان دارویی
جهاد دانشگاهی

مقاله تحقیقاتی

اثر عصاره گل های گیاه *Lilium candidum* L. بر بهبود زخم در مدل زخم سوختگی در موش صحرایی سعیده ممتاز^۱، مهشید دیباج^۲، علیرضا عبداللهی^۳، غلامرضا امین^۴، رودابه بهرام سلطانی^۵، پروین مهدویانی^۶، محمد عبداللهی^۷،

امیر حسین عبدالغفاری^{۸،۲*}^۱ مرکز تحقیقات گیاهان دارویی، پژوهشکده گیاهان دارویی جهاد دانشگاهی، کرج، ایران^۲ گروه سم شناسی و فارماکولوژی، دانشکده داروسازی، دانشگاه آزاد اسلامی، تهران، ایران^۳ گروه پاتولوژی، بیمارستان امام، دانشگاه علوم پزشکی تهران، تهران، ایران^۴ گروه فارماکولوژی، دانشکده داروسازی، دانشگاه علوم پزشکی تهران، تهران، ایران^۵ گروه داروسازی سنتی، دانشکده طب سنتی، دانشگاه علوم پزشکی تهران، تهران، ایران^۶ گروه سم شناسی و فارماکولوژی، دانشکده داروسازی، دانشگاه علوم پزشکی تهران، تهران، ایران^۷ گروه داروسازی، دانشکده داروسازی، دانشگاه علوم پزشکی تهران، تهران، ایران^۸ گروه فارماکولوژی دستگاه گوارش (GPIG) شبکه جهانی آموزش و تحقیقات علمی (USERN) تهران، ایران

چکیده

اطلاعات مقاله

گل واژگان:

Lilium candidum L.

سوختگی

فلاونوئید

فنل ها

ترمیم زخم

مقدمه: گیاهان دارویی برای درمان انواع مختلف زخم مفید هستند. هدف: این مطالعه با هدف ارزیابی پتانسیل بهبود زخم سوختگی توسط عصاره هیدروالکلی گل های *Lilium candidum* L. در موش صحرایی انجام شد. روش بررسی: ظرفیت آنتی اکسیدانی عصاره به روش DPPH، توتال فلاونوئید و محتوای فنلی عصاره مورد بررسی قرار گرفتند. پس از القای زخم سوختگی، موشها به ۵ گروه تقسیم شدند: کرم سولفادیازین نقره ۱ درصد (استاندارد مرجع)، اوسرین (کنترل)، و عصاره گیاه با دوزهای ۵، ۱۰ و ۲۰ درصد که پماد آنها بر پایه اوسرین تهیه شد. میزان انقباض و درصد ترمیم زخم تا روز چهاردهم اندازه گیری شد و تغییرات بافت شناسی مورد بررسی قرار گرفتند. نتایج: فعالیت آنتی اکسیدانی بالای عصاره توسط تست DPPH نشان داده شد. توتال فنل عصاره ۱۵۷ میلی گرم معادل اسید گالیک/گرم بود. در حالی که توتال فلاونوئید عصاره خشک معادل ۳۲/۴ میلی گرم کورستین/ گرم اندازه گیری شد. میانگین سطح زخم در سه گروه موش تحت تیمار با عصاره نسبت به شاهد تفاوت معنی داری داشت. اگرچه، پماد حاوی ۲۰ درصد عصاره بالاترین میزان بهبود زخم در مقایسه با دیگر گروه های درمانی، حتی بهتر از سولفادیازین نقره نشان داد. نتایج بافت شناسی، فعالیت ترمیم زخم و بافت توسط عصاره را تأیید نمود، به ویژه برای پماد حاوی ۲۰ درصد عصاره. نتیجه گیری: با توجه به محتوای بالای ترکیبات فنولیک و فلاونوئیدها در عصاره، به علاوه خاصیت آنتی اکسیدانی بالای گل های لیلیوم که موجب کاهش چشمگیر سطح زخم سوختگی شده است، پیشنهاد می شود که پماد حاوی این عصاره می تواند زخم های سوختگی را درمان کرده و روند بهبودی را تسریع نماید.

مخفف ها: VHS، ویروس هرپس؛ DPPH، ۲،۲- دی فنیل-۱- پیکریل هیدرازیل؛ BHA، هیدروکسیل آنیزول بوتیل؛ $AlCl_3$ ، کلرید آلومینیوم؛ NaOH،هیدروکسید سدیم؛ SSD، سولفادیازین نقره؛ IP، تزریق داخل صفاقی؛ VEGF، فاکتور رشد اندوتلیال عروقی؛ $TGF-\beta$ ، فاکتور تبدیل رشد بتا* نویسنده مسؤول: amirhosein172@hotmail.com

تاریخ دریافت: ۲۹ مرداد ۱۳۹۸؛ تاریخ دریافت اصلاحات: ۱۸ آذر ۱۳۹۸؛ تاریخ پذیرش: ۱۷ دی ۱۳۹۸

doi: 10.29252/jmp.1.73.109

© 2020. Open access. This article is distributed under the terms of the Creative Commons Attribution-NonCommercial 4.0 International License (<https://creativecommons.org/licenses/by-nc/4.0/>)