

Research Article

## Therapeutic potential of ointment containing methanol extract of *Lamium album* L. on cutaneous wound healing in rats

Fereshteh Talebpour Amiri<sup>1</sup>, Fatemeh Mirzaee<sup>2</sup>, Seyedeh Nesa Hasanzadeh<sup>3</sup>, Reza Enayatifard<sup>4</sup>, Somayeh Shahani<sup>5,\*</sup>

<sup>1</sup> Department of Anatomy, Molecular and Cell Biology Research Center, Faculty of Medicine, Mazandaran University of Medical Sciences, Sari, Iran

<sup>2</sup> Medicinal Plants Research Center, Mazandaran University of Medical Sciences, Sari, Iran

<sup>3</sup> Student Research Committee, Mazandaran University of Medical Sciences, Sari, Iran

<sup>4</sup> Department of Pharmaceutics, Faculty of Pharmacy, Mazandaran University of Medical Sciences, Sari, Iran

<sup>5</sup> Department of Pharmacognosy and Biotechnology, Faculty of Pharmacy, Mazandaran University of Medical Sciences, Sari, Iran

ARTICLE INFO	ABSTRACT
<p><b>Keywords:</b> <i>Lamium album</i> Ointment Wound healing Flavonoid Rat</p>	<p><b>Background:</b> Proper wound management which improves the quality of life and reduces patient costs is required. <i>Lamium album</i> L. has been used in traditional medicine to heal skin wounds and recent studies show anti-inflammatory, haemostatic and antimicrobial properties of this plant. <b>Objective:</b> The effect of the ointment containing methanol extract of <i>L. album</i> aerial parts was evaluated on the full-thickness wound healing in rat model. <b>Methods:</b> Thirty-two Wistar rats (250-300 g) were used to be created a square full-thickness wound on the dorsal cervical area and randomly divided into four groups: I; control, II; ointment base, III; 1 % phenytoin cream and IV; 5 % <i>L. album</i> ointment. Wound size for determination of the percent of wound healing was measured on days 3, 5, 7 and 12 of the experiment. The excisional biopsies were evaluated histopathologically on the 12<sup>th</sup> day of treatment according to the Abramov score method. <b>Results:</b> The herbal ointment significantly increased fibroblast maturation, collagen deposition and neovascularization compared to the control group. The wound healing rate was significantly increased in the group treated with <i>L. album</i> ointment, same as phenytoin group, on days 3, 7 and 12. Based on the spectrophotometric analysis, the extract contains phenol and flavonoid compounds. <b>Conclusion:</b> It seems that <i>L. album</i> could be considered as a new candidate for further studies in the field of wound healing.</p>

### 1. Introduction

A wound is defined as a tissue injury with a disruption in anatomical integrity.

Physiologically the healing process begins immediately after injury to replace or restore the damaged tissues. The healing process can be

**Abbreviations:** WHR, Wound Healing Rate; HPF, High Power Field; LAO, *Lamium album* Ointment

\* Corresponding author: [s.shahani@mazums.ac.ir](mailto:s.shahani@mazums.ac.ir)

doi: 10.52547/jmp.20.79.72

Received 27 June 2021; Received in revised form 10 August 2021; Accepted 25 August 2021

© 2020. Open access. This article is distributed under the terms of the Creative Commons Attribution-NonCommercial 4.0 International License (<https://creativecommons.org/licenses/by-nc/4.0/>)

mainly divided into inflammation, proliferation and maturation phases. In the first phase, the blood vessels contract in the area and a clot is formed. Then the blood vessels dilute to allow the white blood cells and other essential elements to reach the wounded area. During this phase, the inflammation is occurred through the cells activities. In the proliferation phase, tissue regeneration, the new collagen and blood vessels development occurs. Maturation is the final phase and occurs once the wound has closed. During this phase cellular activity reduces and the remodeling of collagen is seen [1]. Because impairment or failure of wound healing during the injuries, burns or surgery, can lead to substantial morbidity and even mortality in patients [2], it is important to conduct research to accelerate wound healing. To stimulate the healing process and reduce scar formation, several wound care products and therapies have been developed. The recent therapies comprise grafts, modern dressings, bioengineered skin substitutes, and cell growth factors which exert high medical costs [3]. Despite the recent advances in wound care products, traditional therapies based on natural origin compounds, such as plant extracts are interesting alternatives [4].

*Lamium album* L. is a perennial flowering plant, which is widespread throughout Asia (including Iran), Europe, and Africa. It is belonging to the Lamiaceae family and commonly known as white nettle [5, 6]. The young shoots, leaves and flowers of this plant are edible and can be consumed raw or cooked for health benefits and nutritional value [7]. Different *Lamium* species have long been used in traditional and folk medicine for trauma [8], fracture [8], hemorrhage [9], gastric ulcer [10], wounds [11], skin [12] and joints swelling [13]. Traditionally, *L. album* is used in skin wound

care for many years [5, 9] and recent investigations show anti-inflammatory [14], haemostatic [15], antimicrobial [16], and cell-stimulating properties of the plant [17]. It is reported that phenolic compounds are responsible for these activities [18].

Considering the above properties, there has been no comprehensive study on the wound healing activities of *L. album*. The aim of the present work was to assess the healing properties of 5 % *L. album* ointment (LAO) on the full-thickness wound in Wistar albino rats by determination of wound healing rate (wound closure) and histological evaluation of skin samples. Moreover, the spectrophotometric analysis was performed for determination of the total phenol and flavonoid contents of *L. album* methanol extract.

## 2. Materials and Methods

### 2.1. Plant material and extraction

The aerial parts of *L. album* were collected from Tallarposht village, Mazandaran province, Iran, during the flowering stage (May 2019). A voucher specimen (no. E1-36-4171) was deposited at the Herbarium of the Faculty of Pharmacy, Mazandaran University of Medical Sciences, Sari, Iran. The amount of 100 g of the dried sample was powdered and macerated in methanol for 48 h (four times). The resulted extracts were filtered, then concentrated by a rotary evaporator and defatted with hexane. Finally, the extract was freeze-dried to remove the residual moisture and stored at -20°C for further uses.

### 2.2. Determination of total phenol and flavonoid contents

Total phenol and flavonoid contents of the extract were determined by Folin-Ciocalteu and aluminum chloride methods, respectively [19,

20]. The standard calibration curves were plotted using different concentrations of gallic acid and quercetin (6.25-200 µg/mL).

### 2.3. Topical ointment preparation

The *L. album* ointment (5 %) was prepared by mixing 5 g of the extract with 10 g of propylene glycol by mortar and pestle. Finally, the amount of 85 g of Eucerin was added and mixed to form homogeneous ointment, then transferred to the suitable container [21].

### 2.4. Animals

Thirty-two Wistar albino rats (female, 250-300 g) were used in this study and kept in standard conditions (12 h light/dark cycles at room temperature (20°C) with 50 % humidity) and allowed to consume standard laboratory food and water. All experiments were approved by the Ethics Committee of Mazandaran University of Medical Sciences, Sari, Iran (Approval Code IR.MAZUMS.REC.1397.3191) and were in accordance with the National Institutes of Health Guide for the Care and Use of Laboratory Animals.

### 2.5. Study design

The wound model was chosen according to our previous study [22]. Rats were anaesthetized using an intraperitoneal injection of ketamine (50 mg/kg) and xylazine (5 mg/kg). The dorsal skin (neck area) of the rats was depilated and disinfected with 70 % ethanol, a square full-thickness wounds (1.5 × 1.5 cm dimension) was excised under aseptic conditions using a surgical blade. Immediately after the surgery, the animals were randomly divided into 4 experimental groups (n = 8) as follows: (I) control group, without treatment; (II) the ointment base treated group; (III) Phenytoin group, rats treated with 1 % phenytoin cream; (IV) LAO group, rats

treated with 5 % W/W *L. album* ointment. The phenytoin cream, ointment base and LAO ointment were applied topically once daily on the wounded area by the 1<sup>st</sup> to 12<sup>th</sup> days of the study. The wounds were uncovered during the examination. The rats were maintained in their separate experimental units which were cleaned and dried daily to prevent the secondary infection.

### 2.6. Determination of the rate of wound healing

On the 3<sup>rd</sup>, 5<sup>th</sup>, 7<sup>th</sup> and 12<sup>th</sup> days, the wounded area was covered with a transparent sheet to mark the area around the wound. Then using graph paper, the number of squares within the wound area was counted. The rate of the wound healing (WHR) was determined using the following equation:

$$\text{WHR (\%)} = [(W_o - W_u)/W_o] \times 100$$

Where,  $W_o$  and  $W_u$  mean the original and unhealed area of the wound, respectively [23].

### 2.7. Histopathological analysis

To separate the biopsy specimen, about 5 mm of healthy skin with the repaired area was collected from the wound bed. The samples were fixed in 10 % formalin, dehydrated in alcohol, clarified in xylene and embedded in paraffin. The fixed skin tissues were sectioned at 5 µm thickness and stained with hematoxylin and eosin for histopathological assessment. The histological images were analyzed according to the Abramov score method [24].

The following scoring criteria were used for histological assessment of the wound. Acute inflammation grading were scored as 0: none; 1: scant; 2: moderate; 3: abundant. Granulation tissue fibroblast maturation grading were scored as 0: immature; 1: mild maturation; 2: moderate maturation; 3: fully mature. Collagen

deposition grading were scored as 0: none; 1: scant; 2: moderate; 3: abundant. Epidermis formation grading were scored as 0: none; 1: partial; 2: complete but immature or thin; 3: complete and mature. Neovascularization grading were scored as 0: none; 1: up to five vessels per high-power field (HPF); 2: 6-10 vessels per HPF; 3: more than 10 vessels per HPF. Keratin layer formation grading were scored as 0: none; 1: partial; 2: complete but immature or thin; 3: complete and mature.

### 2.8. Collagen assessment

12 days after the surgery, the skin samples stained using Light Green staining for assessment of the collagen content. The semi-quantitative evaluation was assessed by densitometry using MacBiophotonics Image J 1.41a software. The collagen fiber intensity was measured by the green color stains. The ratio of the stained area to the entire field was assessed [23].

### 2.9. Data analysis

Data were analyzed by SPSS software (version 15). All data were expressed as mean  $\pm$  standard deviation ( $M \pm SD$ ). One-way analysis of variance and Tukey tests were used.  $P < 0.05$  was considered statistically significant in all groups.

## 3. Results

### 3.1. Total phenolic and flavonoid contents

The concentration of total phenol was calculated  $96.25 \pm 0.009$  mg gallic acid ( $y = 0.0012x + 0.0625$ ,  $R^2 = 0.9996$ ) equivalents per gram of dried extract. The total flavonoid content was calculated  $77.887 \pm 0.014$  mg quercetin ( $y = 0.0071x + 0.055$ ,  $R^2 = 0.9989$ ) equivalents per gram of dried methanol extract.

### 3.2. Macroscopic evaluation of the wound healing

No obvious infections and complications were observed in any animals during the experiment. The necrotic tissue was not seen in the treated group with the herbal ointment while it was clearly visible in the control group from the early days.

A statistically significant difference ( $P < 0.05$ ) was seen in the epithelization of the wound between the treatment and control groups. New epithelium with the pink color was observed at the edges of the wound in *L. album* and phenytoin groups (Fig. 1).

### 3.3. Evaluation of the rate of wound healing

Table 1 shows the rate of wound healing in different days of treatment. The wounded area was significantly ( $P < 0.05$ ) decreased during days 3, 7 and 12 in the groups treated with the LAO and phenytoin compared to control (Table 1). On day 12, the wound had contracted down to a minimal area in the treatment groups (Fig. 2). The rate of wound healing was increased gradually during the inflammatory phase in all groups, however it was significant ( $P < 0.05$ ) in the treated with LAO and phenytoin. On day 12, a noticeable increase was observed in the healing rate during the proliferative phase in the LAO and phenytoin groups ( $P < 0.05$ ) compared to the control.

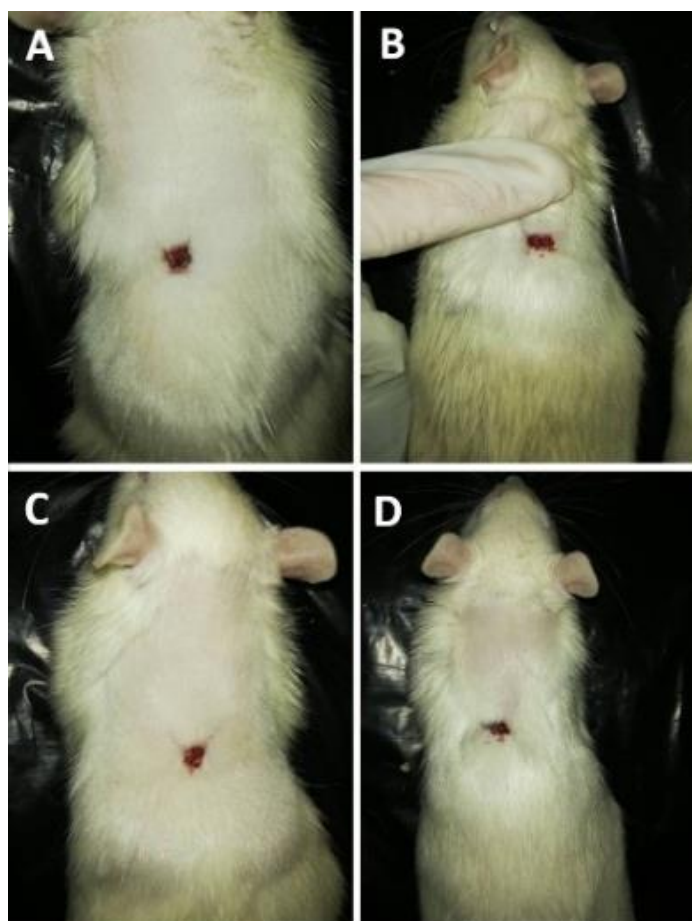
### 3.4. Microscopic observation

The photomicrographs of the wounded area in different groups are shown in Fig. 3. The wound score was calculated in each group and the average scores of wound healing criteria were analyzed (Fig. 4). Based on the findings, the granulation tissue formation appeared during the repair phase. The keratin filaments, neovascularization and the neoepiderm were

appeared. The proliferation of the fibroblast cells was induced significantly ( $P < 0.05$ ) in the treated group with LAO compared to the control. The granulation tissue increased and covered the wounded area in phenytoin and LAO groups. Moreover, the maturation of the granulation tissue was increased in the LAO group compared to the control and phenytoin groups. The number

of new blood vessels per HPF  $\times 40$  in LAO and phenytoin groups was increased rapidly.

Based on Fig. 5, the collagen fibers, which appear in light green color were deposited significantly in LAO and phenytoin ( $P < 0.05$ ) groups compared with control. The analysis of ImageJ showed a 50 % increase in the collagen content of LAO group.

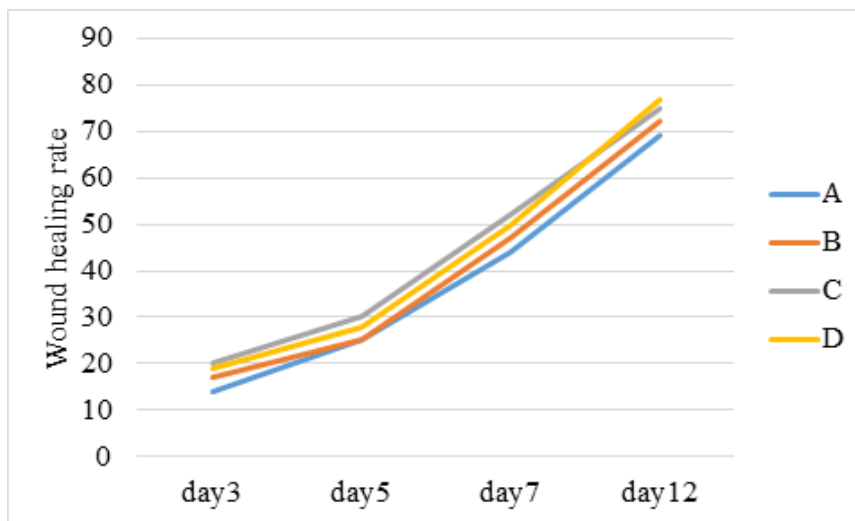


**Fig. 1.** The morphology of the wound area during the healing processes in different groups on the 12<sup>th</sup> day of the treatment. A: Control group; B: The ointment base group; C: Phenytoin group; D: *L. album* ointment group. The obvious reduction of the wound size was observed in the treated group with the *L. album* ointment.

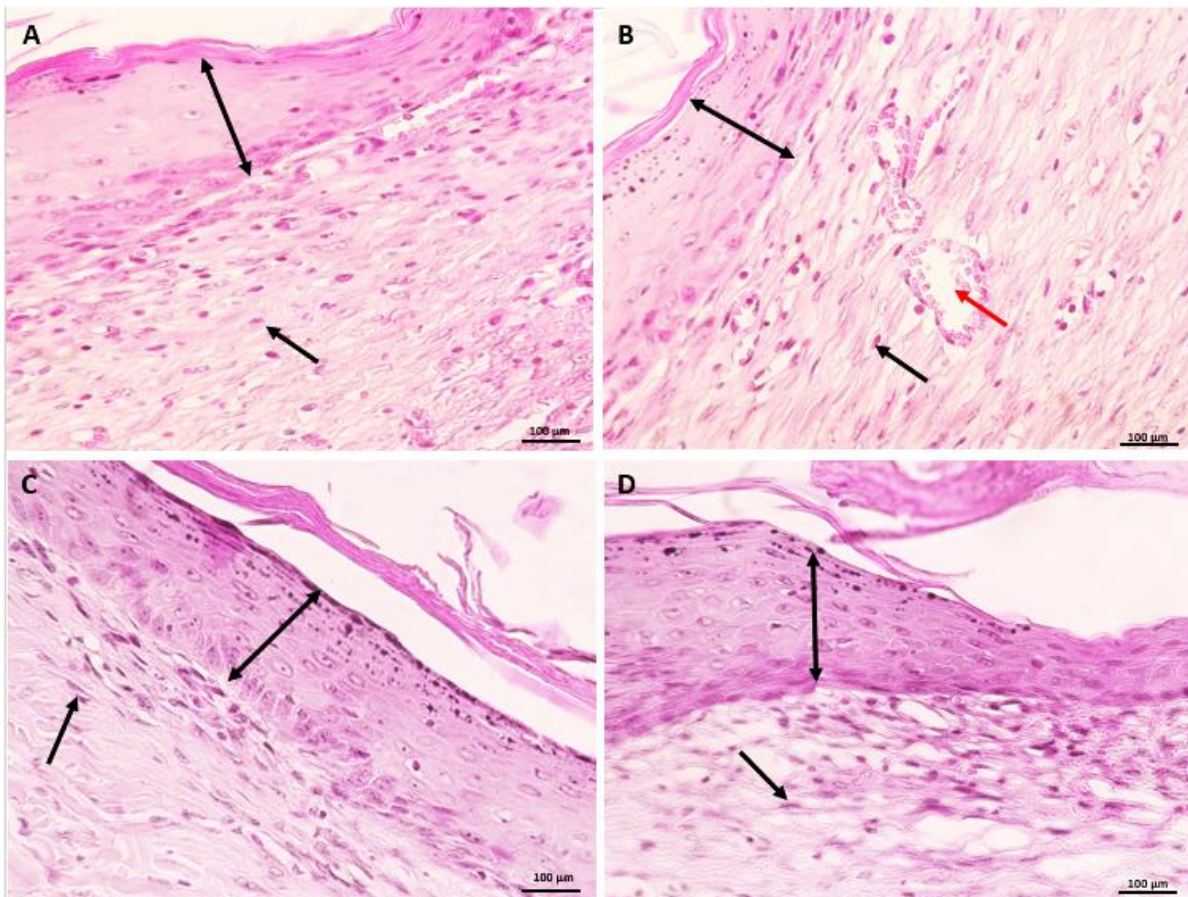
**Table 1.** The rate of wound healing in rats treated with *Lamium album* ointment

Groups	3 <sup>th</sup> day	5 <sup>th</sup> day	7 <sup>th</sup> day	12 <sup>th</sup> day
Control	14 $\pm$ 2.6	25 $\pm$ 3.5	44 $\pm$ 2.16	69 $\pm$ 2.3
Ointment base	17 $\pm$ 4.32	25 $\pm$ 4.16	47 $\pm$ 3.74	72 $\pm$ 3.86
Phenytoin	20 $\pm$ 2.56*	30 $\pm$ 3.79	52 $\pm$ 3.19*	75 $\pm$ 3.04*
5% <i>L. album</i> ointment	19 $\pm$ 2.76*	28 $\pm$ 2.94	50 $\pm$ 2.7*	77 $\pm$ 1.79*#

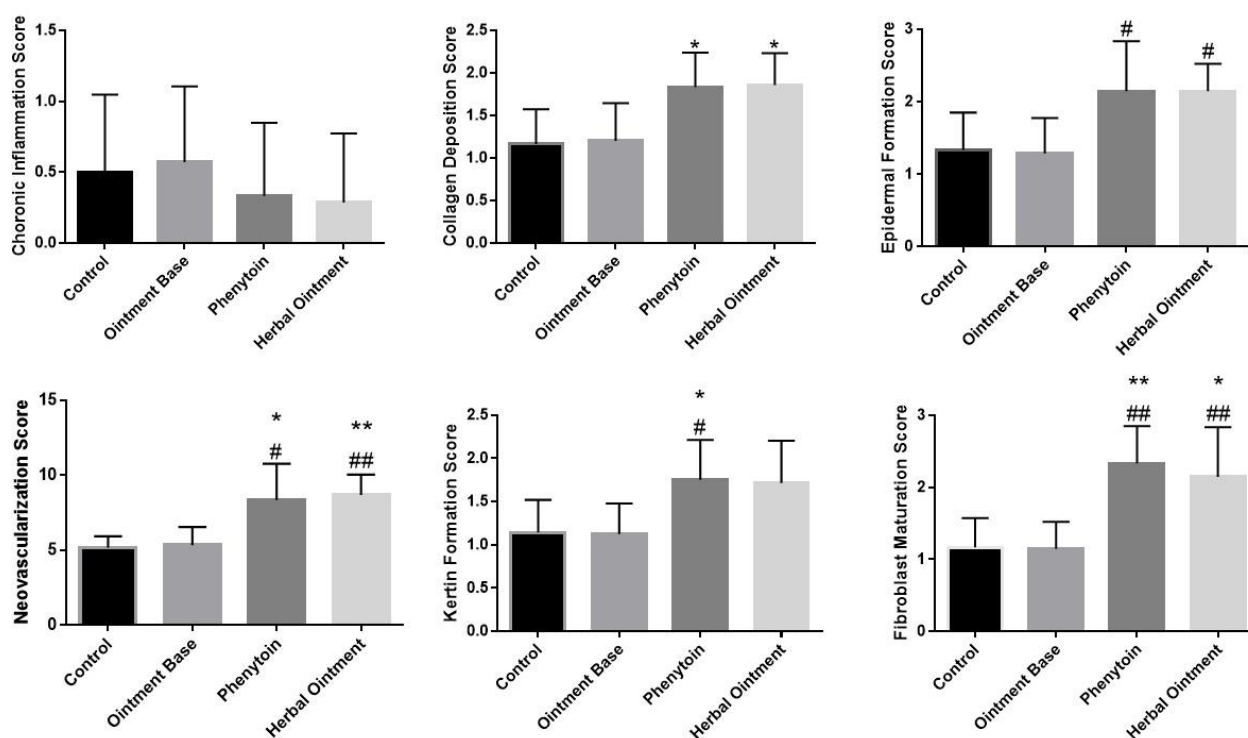
The wound healing rate was expressed as mean  $\pm$  S.D with the surface area in cm<sup>2</sup>. (\*) =  $P < 0.05$ , significant against the control group. (#) =  $P < 0.05$ , significant against the ointment base group.




**Fig. 2.** Changes in the areas of the wounds on days 3, 5, 7, and 12. A: Control group; B: The ointment base group; C: Phenytoin group; D: *L. album* ointment group.



**Fig. 3.** The photomicrographs of the biopsy specimens from the animals on day 12 of the surgery. A: Control group; B: The ointment base group; C: Phenytoin group; D: *L. album* ointment group. The new epidermis layer (↖ arrow) is seen in LAO and phenytoin groups. The granulation tissue formation (↘ arrow) and neovascularization (↘ arrow) is clearly seen in the treated groups. H & E. Mag: × 40. Scale bar = 100 μm.



**Fig. 4.** Effects of *L. album* ointment on the wound healing criteria compared to the control. All values are expressed as mean  $\pm$  SD. (\*)  $P < 0.05$  and (\*\*)  $P < 0.01$ , significant against control group. (#)  $P < 0.05$ , (##)  $P < 0.01$  significant against ointment base group.



**Fig. 5.** The amount of collagen deposition in the skin tissue on the 12<sup>th</sup> day of the study. A: Control group; B: Ointment base group; C: 1% Phenytoin; D: 5% *L. album* ointment. Light Green staining, Magnification;  $\times 10$ . Scale bar = 100  $\mu\text{m}$ .

#### 4. Discussion

The wound healing properties of various herbal formulations have been evaluated in recent years. Medicinal plants cause wound healing by different mechanisms such as wound contraction, promoting epithelization and collagen deposition, increasing granulation tissue and collagen synthesis [25].

The present study showed that the 5 % *L. album* ointment accelerates the wound healing in acute wound model in rats. The topical administration of LAO to animals significantly increased the rate of the wound healing compared to the control group during the days 3, 7 and 12. The results showed the statistically significant differences in histological criteria (collagen deposition, neovascularization and fibroblast maturation) of the groups treated with the LAO and phenytoin compared to the control. The top score fibroblast maturation and proliferation, tissue granulation, dermal and epidermal regeneration, enormous angiogenesis and collagen synthesis were observed in the group treated with LAO.

Based on the recent studies, the topical application of the plant extracts or herbal formulations is effective for the wound healing process [26]. It was reported that the topical application of 5 % *Salvia officinalis* (Lamiaceae) leaf extract ointment in excision and incision wound model, significantly ( $P < 0.05$ ) improves the wound contraction and period of re-epithelialization in Wistar rats via increasing the new vessel formation and Fibroblast distribution. The high levels of phenolic compounds and flavonoids were found in the extract [27]. The wound healing properties of 1 % ointment prepared from *S. kronenburgii* and *S. euphratica*

ethanol extracts were evaluated by Güzel et al. [28]. They reported that the topical application of the ointments, could contract the excision wounds (more than 99 %) in rats compared to the standard drug. The re-epithelialization and angiogenesis were significantly ( $P < 0.001$ ) increased in the treated group with the herbal ointments. The spectrophotometric analysis on the extracts revealed the presence of phenolic and flavonoid constituents.

In the present study, the spectrophotometric analysis of the extract from *L. album* aerial parts, revealed the presence of phenols with the total amount of  $96.25 \pm 0.009$  mg gallic acid equivalents per gram of dried extract.

Based on the recent studies, the total amount of phenolic compounds in the methanol extract of *L. album* flowers [29], and other *Lamium* species aerial parts such as *L. amplexicaule*, *L. galactophyllum*, *L. macrodon* [30] and *L. purpureum* [31], were in the range of 94.75 to 192 mg gallic acid per gram of dried extract.

The present result showed that total flavonoid content in the methanol extract of *L. album* aerial part was  $77.887 \pm 0.014$  mg quercetin equivalents per gram of dried extract. Based on two recent studies, the total flavonoid contents of *L. album* aerial parts were reported 79.83 and 82.11 mg quercetin per gram of dried methanol extract [32, 33].

Collagen is functionally one of the key protein in extracellular dermal matrix which mainly produced by fibroblast cells [34]. Collagen deposition in connective tissues can regenerate the skin and heal the wounds [35]. Several plant extracts have been reported to possess wound healing activity through the fibroblast proliferation and collagen deposition [26]. In a



recent study, cytotoxicity and cytostatic activities of the ethyl acetate and methanol extracts from *L. album* flowers against human normal skin fibroblasts were evaluated. Both extracts showed no toxic effects in the range of applied concentrations (25-225 µg/ml). Moreover, the methanol extract exhibit DPPH free radical scavenging activity and was rich in flavonoids and phenolic acids. Therefore, it was suggested that the *L. album* extracts, can be used in preparation of wound healing and skin protective formulations [17].

Control of hemorrhage following the injury is the prime concern in the management of wounds [36]. Various published results indicate that the plant extracts can promote the blood clotting in injuries [26]. Recently, the haemostatic activity of butanol extracts from the aerial parts of two *Lamium* species (*L. album* and *L. purpureum*) have been investigated by tail bleeding time determination and acenocoumarol-carrageenan test. Both of the extracts demonstrated haemostatic activity in the tail bleeding test. Moreover, the *L. album* extract showed the protective effects in acenocoumarol-carrageenan test, compared to vitamin K. They indicated that 8-acetyl shanzhiside, the iridoid glycoside detected in the extracts, might be responsible for the observed haemostatic activity [15].

Several phenol compounds especially phenyl propanoid glycoside (such as verbascoside and lamalboside) and flavonoids (such as apigenin, kaempferol and quercetin glycosides) were detected and isolated from *L. album* aerial parts [37]. Many in vivo studies, including the murine cutaneous inflammation, incisional and excisional wound model on rats, demonstrated the wound healing activities of apigenin,

kaempferol and quercetin (topical usage) via collagen synthesis of fibroblasts [38], reepithelialization, angiogenesis [39] and decreasing inflammatory cells in the wounded area [40].

Verbascoside has been widely used in the cosmetics with potential anti-inflammatory, antioxidant and photoprotecting activities [41, 42]. It has been previously shown that the topical application of a semi-synthetic derivative of this compound was able to promote the wound healing in rats [41].

It could be suggested that the wound healing activities of *L. album* extract may be attributed to the presence of phenolic and flavonoid constituents.

## 5. Conclusion

It is concluded that the 5 % ointment from the *L. album* methanol extract, same as 1 % phenytoin cream, provided considerable wound healing effects on the full-thickness wound in rats via increasing the fibroblast maturation, collagen deposition and neovascularization compared to the control group. The spectrophotometric evaluation of the extract showed considerable phenolic compounds which could be involved in the plant healing activities. It is recommended that the *L. album* extract could be as a candidate for treatment of acute wounds. Although, it is needed to evaluate the different doses of the *L. album* extract in the other wound models and to identify the effective constituents of the plant.

## Author contributions

S. Sh. and F. TA. designed the study and analyzed the results. N. H. and F. M. performed

the material preparation and data collection. R. E. supervised the laboratory work (ointment preparation). F. M. wrote the first draft of the manuscript. S. Sh. and F. TA. provided the critical reading and insightful recommendations of the manuscript. All of the authors have read the final manuscript and approved the submission.

### Conflict of interest

The authors declare that there is no conflict of interest.

### Acknowledgements

This study was financially supported by Mazandaran University of Medical Sciences, Sari, Iran (grant No. 3191). The authors thank Dr. Masoud Azadbakht for plant identification.

### References


1. White ES and Mantovani AR. Inflammation, wound repair, and fibrosis: reassessing the spectrum of tissue injury and resolution. *J. Pathol.* 2013; 229(2): 141-144. doi: 10.1002/path.4126.
2. Rodrigues M, Kosaric N, Bonham CA and Gurtner GC. Wound healing: a cellular perspective. *Physiol. Rev.* 2019; 99(1): 665-706. doi: 10.1152/physrev.00067.2017.
3. Han G and Ceilley R. Chronic wound healing: a review of current management and treatments. *Adv. Ther.* 2017; 34(3): 599-610. doi: 10.1007/s12325-017-0478-y.
4. Qureshi MA, Khatoon F and Ahmed S. An overview on wounds, their issues and natural remedies for wound healing. *Biochem. Physiol.* 2015; 4(3): 2-9. doi: 10.4172/2168-9652.1000165.
5. Kelayeh TPS, Abedinzade M and Ghorbani A. A review on biological effects of *Lamium album* (white dead nettle) and its components. *J. Herbmed. Pharmacol.* 2018; 8(3): 185-193. doi: 10.15171/jhp.2019.28.
6. Moskova-Doumanova V, Miteva G, Dimitrova M, Topouzova-Hristova T and Kapchina V. Methanol and chloroform extracts from *Lamium album* L. affect cell properties of A549 cancer lung cell line. *Biotechnol. Equip.* 2012; 26(1): 120-125. doi: 10.5504/50YRTIMB.2011.0022.
7. Yordanova ZP, Zhiponova MK, Iakimova ET, Dimitrova MA and Kapchina-Toteva VM. Revealing the reviving secret of the white dead nettle (*Lamium album* L.). *Phytochem. Rev.* 2014; 13(2): 375-389. doi: 10.1007/s11101-014-9356-2.
8. Yalçın FN and Kaya D. Ethnobotany, pharmacology and phytochemistry of the genus *Lamium* (Lamiaceae). *FABAD J. Pharm. Sci.* 2006; 31(1): 43-53.
9. Salehi B, Armstrong L, Rescigno A, Yeskaliyeva B, Seitimova G and Beyatli A. *Lamium* plants—a comprehensive review on health benefits and biological activities. *Molecules.* 2019; 24(10): 1-23. doi: 10.3390/molecules24101913.
10. Miraldi E, Ferri S and Mostaghimi V. Botanical drugs and preparations in the traditional medicine of West Azerbaijan (Iran). *J. Ethnopharmacol.* 2001; 75(2-3): 77-87. doi: 10.1016/s0378-8741(00)00381-0.
11. Jivad N, Bahmani M and Asadi-Samani M. A review of the most important medicinal plants effective on wound healing on ethnobotany

- evidence of Iran. *Der Pharm. Lett.* 2016; 8(2): 353- 357.
12. Baharvand Ahmadi B, Bahmani M, Naghdi N, Saki K, Baharvand Ahmadi S and Rafieian Kopaei M. Medicinal plants used to treat infectious and non-infectious diseases of skin and skin appendages in city of Urmia, northwest Iran. *Der Pharm. Lett.* 2015; 7(11): 189-196.
13. Abbasi AM, Khan MA, Shah MH, Shah MM, Pervez A and Ahmad M. Ethnobotanical appraisal and cultural values of medicinally important wild edible vegetables of Lesser Himalayas-Pakistan. *J. Ethnobiol. Ethnomed.* 2013; 14; 9(1): 1-13. doi: 10.1186/1746-4269-9-66.
14. Paduch R and Woźniak A. The effect of *Lamium album* extract on cultivated human corneal epithelial cells (10.014 pRSV-T). *J. Ophthalmic. Vis. Res.* 2015; 10(3): 229-237. doi: 10.4103/2008-322X.170349.
15. Bubueanu C, Iuksel R and Panteli M. Haemostatic activity of butanolic extracts of *Lamium album* and *Lamium purpureum* aerial parts. *Acta. Pharm.* 2019; 69(3): 443-449. doi: 10.2478/acph-2019-0026.
16. Chipeva VA, Petrova DC, Geneva ME, Dimitrova MA, Moncheva PA and Kapchina-Toteva VM. Antimicrobial activity of extracts from in vivo and in vitro propagated *Lamium album* L. plants. *Afr. J. Tradit. Complement. Altern. Med.* 2013; 10(6): 569-580. doi: 10.4314/ajtcam.v10i6.30.
17. Paduch R, Matysik G, Wójciak-Kosior M, Kandefer-Szerszeń M, Skalska-Kamińska A, Nowak-Kryśka M, Niedziela P. *Lamium album* extracts express free radical scavenging and cytotoxic activities. *Polish. J. Environ. Stud.* 2008; 17(4): 69-75.
18. Botirov EK. Flavonoids and phenolcarboxylic acids from *Lamium album*. *Chem. Nat. Compd.* 2019; 55(6): 1159-1160. doi: 10.1007/s10600-019-02921-2.
19. Makkar HPS, Blummel M, Borowy NK, and Becker K. Gravimetric determination of tannins and their correlations with chemical and protein precipitation methods. *J. Sci. Food Agric.* 1993. 61(2): 161-165. doi: 10.1002/jsfa.2740610205.
20. Sembiring EN, Elya B and Sauriasari R. Phytochemical screening, total flavonoid and total phenolic content and antioxidant activity of different parts of *Caesalpinia bonduc* (L.) Roxb. *Pharmacogn. J.* 2018; 10(1): 123-127. doi: 10.5530/pj.2018.1.22.
21. Zadeh Gharaboghaz MN, Farahpour MR, Saghaie S. Topical co-administration of *Teucrium polium* hydroethanolic extract and *Aloe vera* gel triggered wound healing by accelerating cell proliferation in diabetic mouse model. *Biomed. Pharmacother.* 2020; 127: 110189. doi: 10.1016/j.biopha.2020.110189.
22. Amiri FT, Fathabadi FF, Rad MM, Piryaee A, Ghasemi A and Khalilian A. The effects of insulin-like growth factor-1 gene therapy and cell transplantation on rat acute wound model. *Iran. Red. Crescent. Med. J.* 2014; 16(10): e16323. doi: 10.5812/ircmj.16323.
23. Hanafi N, Shahani S, Enayatifard R, Talebpour Amiri F, Ghasemi M, Karimpour AA. Licorice cream promotes full-thickness wound healing in Guinea pigs. *Marmara. Pharm. J.* 2018; 22(3): 411-421. doi: 10.12991/jrp.2018.81.
24. Abramov Y, Golden B, Sullivan M, Botros SM, Miller JJR and Alshahrour A. Histologic characterization of vaginal vs. abdominal surgical wound healing in a rabbit model. *Wound. Repair. Regen.* 2007; 15(1): 80-86. doi: 10.1111/j.1524-475X.2006.00188.x.

- 25.** Raina R, Prawez S, Verma P and Pankaj N. Medicinal plants and their role in wound healing. *VetScan*. 2008; 3(1): 1-24.
- 26.** Shedoeva A, Leavesley D, Upton Z and Fan C. Wound healing and the use of medicinal plants. *Evid. Based. Complement. Alternat. Med*. 2019; 2684108. doi: 10.1155/2019/2684108.
- 27.** Karimzadeh S and Farahpour MR. Topical application of *Salvia officinalis* hydroethanolic leaf extract improves wound healing process. *Indian. G. Exp. Biol*. 2017; 55(2): 98-106.
- 28.** Güzel S, Özyay Y, Kumaş M, Uzun C, Özkorkmaz EG and Yıldırım Z. Wound healing properties, antimicrobial and antioxidant activities of *Salvia kronenburgii* Rech. f. and *Salvia euphratica* Montbret, Aucher & Rech. f. var. *euphratica* on excision and incision wound models in diabetic rats. *Biomed. Pharmacother*. 2019; 111: 1260-1276. doi: 10.1016/j.biopha.2019.01.038.
- 29.** Matkowski A and Piotrowska M. Antioxidant and free radical scavenging activities of some medicinal plants from the Lamiaceae. *Fitoterapia*. 2006; 77(5): 346-353. doi: 10.1016/j.fitote.2006.04.004.
- 30.** Erbil N, Alan Y and Diğrak M. Antimicrobial and antioxidant properties of *Lamium galactophyllum* Boiss & Reuter, *L. macrodon* Boiss & Huet and *L. amplexicaule* from Turkish Flora. *Asian. J. Chem*. 2014; 26(2): 549-554. doi: 10.14233/ajchem.2014.15748.
- 31.** Grujić SM, Džamić AM, Mitić VD, Stankov-Jovanović V, Marin PD and Stojanović GS. Effects of solvent extraction system on antioxidant activity of *Lamium purpureum* L. *Hem. Ind*. 2017; 71(5): 361-370. doi: 10.2298/HEMIND160518047G.
- 32.** Fathi H, Gholipur A, Ali Ebrahimzadeh M, Yasari E, Ahanjan M and Parsi B. In vitro evaluation of the antioxidant potential, total phenolic and flavonoid content and antibacterial activity of *Lamium album* extracts. *Int. J. Pharm. Sci*. 2018; 9(10): 4210-4219. doi: 10.13040/IJPSR.0975-8232.9(10).4210-19.
- 33.** Valyova M, Dimitrova M, Ganeva Y, Kapchina-Toteva VM and Yordanova ZP. Evaluation of antioxidant and free radical scavenging potential of *Lamium album* L. growing in Bulgaria. *J. Pharm. Res*. 2011; 4(4): 945-947.
- 34.** McDougall S, Dallon J, Sherratt J and Maini P. Fibroblast migration and collagen deposition during dermal wound healing: mathematical modelling and clinical implications. *Philos. Trans. A. Math. Phys. Eng. Si*. 2006; 364(1843): 1385-1405. doi: 10.1098/rsta.2006.1773.
- 35.** Rangaraj A, Harding K and Leaper D. Role of collagen in wound management. *Wounds Uk*. 2011; 7(2): 54-63.
- 36.** Khoshmohabat H, Dalfardi B, Dehghanian A, Rasouli HR, Mortazavi SMJ and Paydar S. The effect of CoolClot hemostatic agent on skin wound healing in rats. *J. Surg. Res*. 2016; 200(2): 732-737. doi: 10.1016/j.jss.2015.08.023.
- 37.** Czerwińska ME, Świerczewska A and Granica S. Bioactive constituents of *Lamium album* L. as inhibitors of cytokine secretion in human neutrophils. *Molecules*. 2018; 23(11): 1-15. doi: 10.3390/molecules23112770.
- 38.** Zhang Y, Wang J, Cheng X, Yi B, Zhang X and Li Q. Apigenin induces dermal collagen synthesis via smad2/3 signaling pathway. *Eur. J. Histochem*. 2015; 59(2): 98-106. doi: 10.4081/ejh.2015.2467.

39. Özay Y, Güzel S, Yumrutaş Ö, Pehlivanoğlu B, Erdoğan İH and Yildirim Z. Wound healing effect of kaempferol in diabetic and nondiabetic rats. *J. Surg. Res.* 2019; 233: 284-296. doi: 10.1016/j.jss.2018.08.009.
40. Taskan MM, Yuce HB, Karatas O and Gevrek F. Topical quercetin gel application improved wound healing in Wistar rats. *Ann. Med. Res.* 2019; 26(10): 2397-2404. doi: 10.5455/annalsmedres.2019.05.289.
41. Crivellari I, Vertuani S, Lim Y, Cervellati F, Baldisserotto A and Manfredini S. ES2 as a novel verbascoside-derived compound in the treatment of cutaneous wound healing. *Cosmetics.* 2018; 5(4): 1-9. doi: 10.3390/cosmetics5040065.
42. Vertuani S, Beghelli E, Scalambra E, Malisardi G, Copetti S and Toso RD. Activity and stability studies of verbascoside, a novel antioxidant, in dermo-cosmetic and pharmaceutical topical formulations. *Molecules.* 2011; 16(8): 7068-7080. doi: 10.3390/molecules16087068.

How to cite this article: Talebpour Amiri F, Mirzaee F, Hasanzadeh SN, Enayatifard R, Shahani S. Therapeutic potential of ointment containing methanol extract of *Lamium album* L. on cutaneous wound healing in rats. *Journal of Medicinal Plants* 2021; 20(79): 72-84.  
doi: 10.52547/jmp.20.79.72



## پتانسیل درمانی پماد حاوی عصاره متانولی گیاه گزنه سفید (*Lamium album* L.) بر ترمیم زخم پوستی در موش‌های صحرایی

فرشته طالب‌پور امیری<sup>۱</sup>، فاطمه میرزائی<sup>۲</sup>، سیده نساء حسن‌زاده<sup>۳</sup>، رضا عنایتی‌فرد<sup>۴</sup>، سمیه شاهانی<sup>۵\*</sup>

<sup>۱</sup> گروه آناتومی، مرکز تحقیقات سلولی و مولکولی، دانشکده پزشکی، دانشگاه علوم پزشکی مازندران، ساری، ایران

<sup>۲</sup> مرکز تحقیقات گیاهان دارویی، دانشگاه علوم پزشکی مازندران، ساری، ایران

<sup>۳</sup> کمیته تحقیقات دانشجویی، دانشگاه علوم پزشکی مازندران، ساری، ایران

<sup>۴</sup> گروه فارماسیوتیکس، دانشکده داروسازی، دانشگاه علوم پزشکی مازندران، ساری، ایران

<sup>۵</sup> گروه فارماکولوژی و بیوتکنولوژی، دانشکده داروسازی، دانشگاه علوم پزشکی مازندران، ساری، ایران

### چکیده

### اطلاعات مقاله

**مقدمه:** مدیریت مناسب زخم که کیفیت زندگی را بهبود بخشد و هزینه‌های درمانی بیماران را کاهش دهد، مورد نیاز است. گیاه گزنه سفید در طب سنتی جهت التیام زخم‌های پوستی استفاده می‌شود و مطالعات اخیر نشان‌دهنده اثرات ضد التهابی، هموستاتیک و ضد میکروبی این گیاه می‌باشد. **هدف:** اثر پماد حاوی عصاره متانولی از اندام هوایی گیاه گزنه سفید، بر ترمیم زخم تمام ضخامت حاد پوستی در مدل موش صحرایی بررسی شد. **روش بررسی:** از ۳۲ موش صحرایی ویستار (۲۵۰-۳۰۰ گرم) برای ایجاد زخم تمام ضخامت مربعی در ناحیه پشتی گردن استفاده شد و به طور تصادفی به چهار گروه تقسیم شدند: I: کنترل، II: پایه پماد، III: کرم ۱ درصد فنی توئین و IV: پماد ۵ درصد گزنه سفید. اندازه زخم جهت تعیین درصد ترمیم زخم در روزهای ۳، ۵، ۷ و ۱۲ از شروع آزمایش اندازه‌گیری شد. نمونه‌های بافتی برش داده شده از نظر هیستوپاتولوژیکی در روز ۱۲ درمان بر اساس روش Abramov score ارزیابی شدند. **نتایج:** پماد گیاهی به میزان قابل توجهی بلوغ فیبروبلاست، رسوب کلاژن و نورگزایی را در مقایسه با گروه کنترل افزایش داد. میزان ترمیم زخم در گروه تحت درمان با پماد گیاهی مشابه با گروه فنی توئین، به میزان قابل توجهی در روزهای ۳، ۷ و ۱۲ افزایش یافت. بر اساس آنالیز اسپکتروفوتومتری، عصاره گیاه حاوی ترکیبات فنولی و فلاونوئیدی می‌باشد. **نتیجه‌گیری:** به نظر می‌رسد گیاه گزنه سفید می‌تواند به عنوان یک کاندیدای جدید برای مطالعات بیشتر در زمینه ترمیم زخم مورد توجه قرار گیرد.

گل‌واژگان:

گزنه سفید

پماد

ترمیم زخم

فلاونوئید

موش صحرایی

مخفف‌ها: WHR، میزان ترمیم زخم؛ HPF، با بزرگنمایی بالا؛ LAO، پماد گزنه سفید

\* نویسنده مسؤول: [s.shahani@mazums.ac.ir](mailto:s.shahani@mazums.ac.ir)

تاریخ دریافت: ۶ تیر ۱۴۰۰؛ تاریخ دریافت اصلاحات: ۱۹ مرداد ۱۴۰۰؛ تاریخ پذیرش: ۲ شهریور ۱۴۰۰

doi: 10.52547/jmp.20.79.72

© 2020. Open access. This article is distributed under the terms of the Creative Commons Attribution-NonCommercial 4.0 International License (<https://creativecommons.org/licenses/by-nc/4.0/>)