

Research Article

The role of lecithin on topical anti-inflammatory activity of turmeric (*Curcuma longa* L.) ointment

Somayeh Esmaeili¹, Saleh Omid-Malayeri², Homa Hajimehdipoor^{1,*}, Hamid Reza Rasekh³, Hamid Reza Moghimi⁴, Soheil Omid-Malayeri⁵, Roya Yaraee⁶, Mohammad Reza Jalali Nadoushan⁷

¹Traditional Medicine and Materia Medica Research Center and Department of Traditional Pharmacy, School of Traditional Medicine, Shahid Beheshti University of Medical Sciences, Tehran, Iran

²Pharmaceutical Sciences Branch, Islamic Azad University, Tehran, Iran

³Department of Pharmacoecology & Administrative Pharmacy, School of Pharmacy, Shahid Beheshti University of Medical Sciences, Tehran, Iran

⁴Department of Pharmaceutics, School of Pharmacy, Shahid Beheshti University of Medical Sciences, Tehran, Iran

⁵Student Research Committee, School of Medicine, Shahed University, Tehran, Iran

⁶Department of Immunology, School of Medicine, Shahed University, Tehran, Iran

⁷Department of Pathology and Anatomy, School of Medicine, Shahed University, Tehran, Iran

ARTICLE INFO

Keywords:

Turmeric
Inflammation
Iranian folk medicine
Rat
Curcuma longa

ABSTRACT

Background: Turmeric (*Curcuma longa* L.) is widely used in traditional medicine. In Iranian folk medicine, turmeric and egg yolk mixture is used for inflammation due to dislocations and strains. Since lecithin (one of the component of egg yolk) is an absorption enhancer, it seems this phospholipid can increase turmeric absorption and its anti-inflammatory effect. **Objective:** In order to find the role of lecithin in the folklore formulation, anti-inflammatory effects of ointments containing turmeric extract and lecithin have been studied. **Methods:** Ointment base was prepared using bees wax, vaseline, liquid paraffin and eucerin. Then, hydroalcoholic turmeric extract (2.5 % and 5 %) with lecithin (5 % and 15 %) or without lecithin were added to the ointment base. Anti-inflammatory effect of the ointments was assessed in arthritis model in rat using complete Freund's adjuvant. Ointments were used daily on the inflamed joints for 20 days. Finally, arthritis index, TNF- α concentration and histopathological changes of joints were determined. **Results:** The results showed that arthritis index has decreased in all groups but it was significant in groups of turmeric 2.5 % and turmeric 5 % with lecithin 15 %. TNF- α was decreased in all samples but reduction was more significant in group turmeric 2.5 %. Histopathological changes were significantly less in turmeric groups compared to ointment base group. **Conclusion:** It seems that local healers use egg yolk as a binder in formulation. In other words, turmeric 2.5 % ointment is preferable compared to other formulations.

Abbreviations: C, *Curcuma longa*; L, Lecithin; TNF- α , Tumor Necrosis Factor-alpha; S.C., Subcutaneous; COX-2, Cyclooxygenase-2; iNOS, Inducible Nitric Oxide Synthase; IL, Interleukin; MCP, Monocyte Chemoattractant Protein

* Corresponding author: hajimehd@sbm.ac.ir

doi: 10.29252/jmp.19.76.89

Received 19 April 2020; Received in revised form 26 October 2020; Accepted 1 November 2020

© 2020. Open access. This article is distributed under the terms of the Creative Commons Attribution-NonCommercial 4.0 International License (<https://creativecommons.org/licenses/by-nc/4.0/>)

1. Introduction

Curcuma longa L. (turmeric), a perennial herb, is a member of Zingiberaceae family which has been used as an ethno-medicine from time memorial in traditional medicine of many countries especially Iranian traditional medicine, traditional Chinese medicine and Ayurveda system [1, 2]. It has a long traditional of use particularly as an anti-inflammatory agent and for the treatment of flatulence, jaundice, menstrual difficulties, hematuria, hemorrhage and colic orally. The rhizome of the plant is used extensively in foods for both flavor and color [1]. The biological activities of turmeric rhizome are mainly attributed to the presence of phenolic compounds (curcuminoids, yellow pigments) and the terpenoids (mono- and sesquiterpenoids). The β -dicarbonylic system in curcuminoids has the conjugated double bonds which provides anti-inflammatory power. Moreover, the presence of the diene ketone system provides lipophilicity to the compounds and thus probably better skin penetration [1]. Therefore, the plant is good candidate for usage as anti-inflammatory agent in topical dosage forms. In the Indian system of medicine, turmeric is a household remedy for reducing pain, swelling, wound injury and various types of inflammation [3]. Several topical preparations have been made from the plant especially in combination with other plants. In Iranian folk medicine, turmeric powder and egg yolk mixture is the common treatment for strains and dislocations which cause inflammation. Since, anti-inflammatory properties of turmeric have been established [4-6], egg yolk may play an especial role in the formulation. Lecithin is a major constituent of egg yolk which has phospholipid structure. It is a complex mixture of phosphatides, which mainly consist of phosphatidyl choline, phosphatidyl ethanolamine, phosphatidyl serine, and

phosphatidyl inositol along with other substances such as triglycerides and fatty acids. The main sources of lecithin are soya beans and egg yolk. Lecithin varies greatly in its physical form, from viscous semi-liquid to powder depending on the free fatty acid content. It's color maybe also different from brown to light yellow depending on whether it is bleached or unbleached. Lecithin acts as an enhancer for absorption of some compounds [7]. Therefore, the reason of egg yolk usage in the formulation may be increasing turmeric constituent's penetration and alleviating its efficacy. Despite of the wide folklore usage of turmeric/egg yolk in strains and dislocations, there is no academic study about this formulation, its efficacy and the role of egg yolk in the mixture. In the present investigation, turmeric ointment was prepared by using different concentrations of turmeric extract with and without lecithin and their efficacy was evaluated in arthritis model in rat.

2. Materials and Methods

2.1. Ethical consideration

Ethical Committee of Shahid Beheshti University of Medical Sciences approved this study with the code of 107-90/07/24.

2.2. Chemicals

Lecithin E80 (Egg lecithin) was purchased from lipoid Co, USA. All other chemicals and solvents were from Merck Co, Germany.

2.3. Plant materials

Rhizome of *Curcuma longa* L. was purchased from Tehran herbal market and identified in Herbarium of Traditional Medicine & Materia Medica Research Center, SBMU, Tehran, Iran. A sample with code of HMS 337 was kept in the Herbarium. Then the rhizomes were powdered.

2.4. Plant extraction

The plant powder was extracted by using ethanol 80% with maceration method (plant: solvent 1:5) for 4 days. Every 24 hours, the solvent was renewed. Combined extracts were concentrated under reduced pressure and freeze dried.

2.5. Quantitation of dicinnamoyl methane derivatives in turmeric extract

The spectroscopic method was used for quantitative determination of dicinnamoyl methane derivatives expressed as curcumin at 530 nm in the dried extract [8].

2.6. Preparation of turmeric/lecithin ointments

In order to prepare ointment base, bees wax, liquid paraffin, eucerin and vaseline were used. Regarding the usage of the ointment in strains and dislocations, the viscosity of the ointment is very important to stay on the injured area for long time. In order to obtain suitable viscosity of the ointment, different ointment bases with various concentrations of constituents were prepared and the best one was selected. Then two concentrations of turmeric extract (2.5 & 5 %) and lecithin (5 & 15 %) were added to the ointment base.

2.7. Anti-inflammatory investigation of the ointments in arthritis model in rat

Fifty four male Wistar rats, 150-200 g, were maintained under 12 hours light-dark cycle in a temperature and humidity controlled room. Rats were allowed free access to standard laboratory feed and water before experiment. The animals were divided to nine groups; each one contained six rats as the following: group 1, turmeric 2.5 % ointment; group 2, turmeric 5 % ointment; group 3, turmeric 2.5 % and lecithin 5 % ointment; group 4, turmeric 2.5 % and lecithin

15 % ointment; group 5, turmeric 5 % and lecithin 5 % ointment; group 6, turmeric 5 % and lecithin 15 % ointment; group 7, ointment base; group 8, Piroxicam gel; group 9, no arthritis was induced. One gram of each ointment/gel was used on right hind wrist joint of rats every day.

In order to induce arthritis, 0.05 ml complete Freund's adjuvant (CFA) was injected sub cutaneous (S.C.) in tibio-tarsal of right hind wrist joint of rats. Inflammation was started 3-4 days after injection and raised to maximum at day 14. On 15th day, the treatment was started. The ointments were used daily on inflamed joints for 20 days. Before starting treatment and on 20th day after treatment, arthritis index was determined in each group by using visual scoring system ranging from 0 to 4: 0, wrist with no swelling and focal redness; 1, redness without swelling; 2, redness with mild swelling; 3, redness with severe swelling; 4, redness with severe swelling and difficulty in movement. On 20th day after treatment, the serum was collected from peripheral blood. TNF- α in serum was measured using ELISA kit (Enzo Life, USA) at 450 nm. Each sample was assayed triplicate. For histopathology examination, hind wrist joints were amputated and were fixed in 10% neutral-buffered formalin, then decalcified in 5% formic acid and embedded in paraffin. The sections (5 μ m) were stained with haematoxylin and eosin (H & E) and examined microscopically. A blind observer evaluated the samples by synovial proliferation, cellular infiltration, pannus formation and cartilage erosion using following scoring system: synovial proliferation: grade 0, proliferation was absent; grade 1, proliferation was mild with two to four layers of reactive synoviocytes; grade 2, proliferation was moderate with four plus layers of reactive synoviocytes, increased mitotic activity and mild or absent synovial cell invasion of adjacent bone

and connective tissue; grade 3, proliferation was severe and characterized by invasion and effacement of joint space and adjacent cartilage, bone and connective tissue. Cellular infiltration: grade 0, no changes; grade 1, few focal infiltrates; grade 2, extensive focal infiltrates; grade 3, extensive infiltrates invading the capsule with aggregate formation. Cartilage erosion: grade 0, no changes; grade 1, superficial, localized cartilage degradation in more than one region; grade 2, localized deep cartilage degradation; grade 3, extensive deep cartilage degradation at several locations. Pannus formation: grade 0, no changes; grade 1, pannus formation at up to two sites; grade 2, pannus formation at up to four sites, with infiltration or flat overgrowth of joint surface; grade 3, pannus formation at more than four sites or extensive pannus formation at two sites [9].

2.8. Statistical analysis

Data were expressed as mean \pm SD. The analysis of variance (ANOVA) followed by Tukey post-test was used to determine significant difference between means of groups. T-test was used for determining difference of before and after treatment in each group. $P < 0.05$ was considered statistically significant.

3. Results

3.1. Dicinnamoyl methane derivatives content in turmeric extract

Dicinnamoyl methane derivatives content in dried turmeric extract was found 10.68 ± 0.75 %.

3.2. Preparation of the ointment

After using different proportion of ointment base constituents and determination of physical characteristics of the prepared bases, the

ointment base including beeswax 7 %, liquid paraffin 3.5 %, eucerin 14 % and vaseline 75.50 % was found as the best formulation. This formulation showed suitable appearance and viscosity. Then turmeric and lecithin were added to the ointment base.

3.3. Pharmacological experiment

The results of arthritis index showed that it has decreased in all groups but it was significant only in groups of turmeric 2.5 % and turmeric 5 % with lecithin 15 % ($P < 0.05$) (Fig. 1). The results of TNF- α assay have been shown in Fig. 2. It is obvious that TNF- α has decreased after treatment with all turmeric/lecithin ointments ($P < 0.05$). But reduction was more in group 1 which received turmeric 2.5 % ointment. This formulation was effective even more than Piroxicam which has been considered as positive control. No significant difference was observed between treatment groups ($P > 0.05$).

The results of histopathological examination have been demonstrated in Fig. 3. It shows total scoring of histological changes of joints including synovial proliferation, cellular infiltration, pannus formation and cartilage erosion. It is obvious that groups of turmeric 2.5 %, turmeric 5 %, turmeric 5 % plus lecithin 5 %, turmeric 5 % plus lecithin 15 % and Piroxicam had significant difference with ointment base group. But turmeric 5 % plus lecithin 15 % group was less effective than others. There was no significant difference between turmeric 2.5 %, turmeric 5 %, turmeric 5 % plus lecithin 5 % and Piroxicam groups. Therefore, mentioned groups could decrease histopathological changes as same as Piroxicam.

Fig. 4 shows the results of histopathology examination.

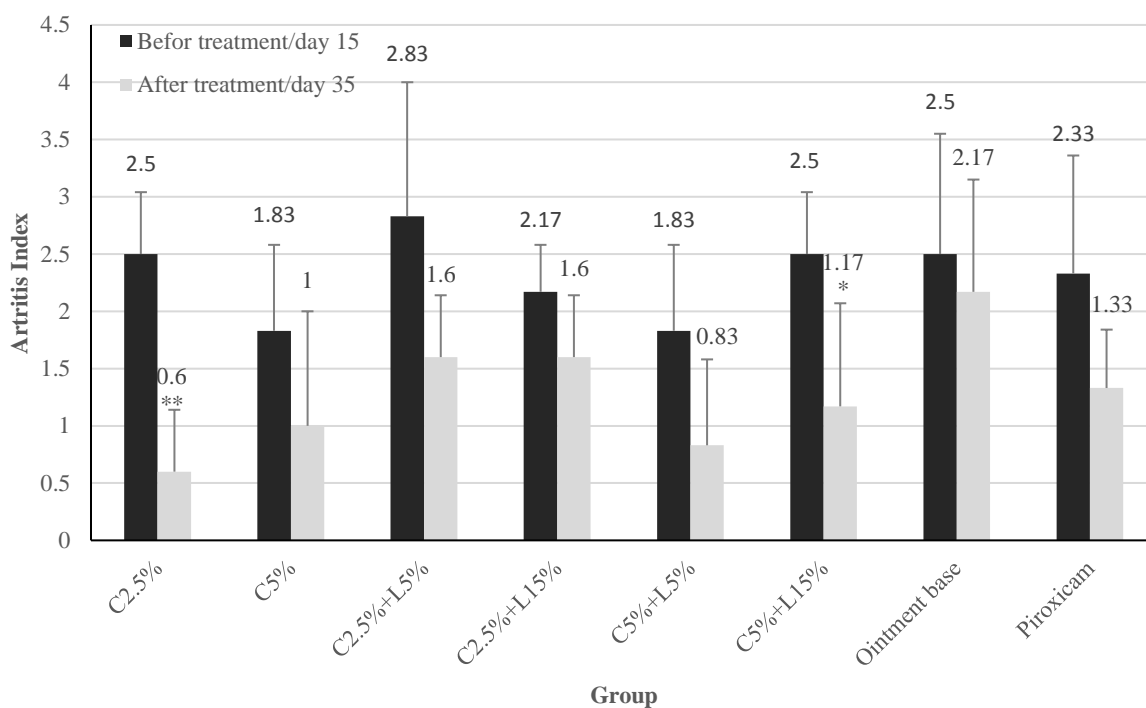


Fig. 1. Arthritis index in different groups receiving turmeric/lecithin ointment in arthritis model (C: *Curcuma longa*; L: Lecithin). The data are mean \pm SD of six rats. **: $P < 0.01$, *: $P < 0.05$ between before and after treatment in each group.

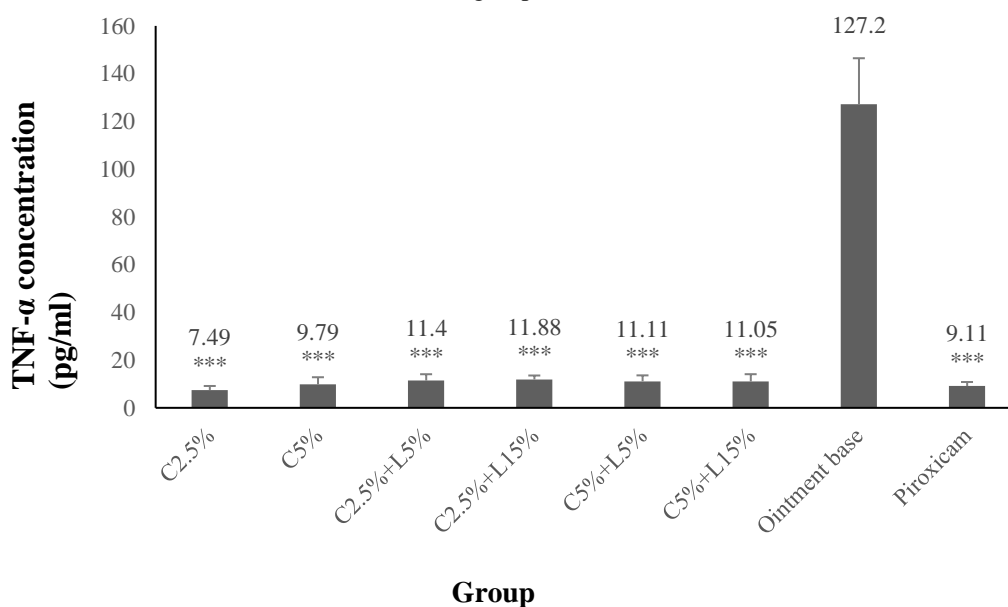


Fig. 2. TNF- α concentration in different groups receiving turmeric/lecithin ointment in arthritis model (C: *Curcuma longa*; L: Lecithin). The data are mean \pm SD of six rats. ***: significant difference ($P < 0.001$) compared to ointment base.

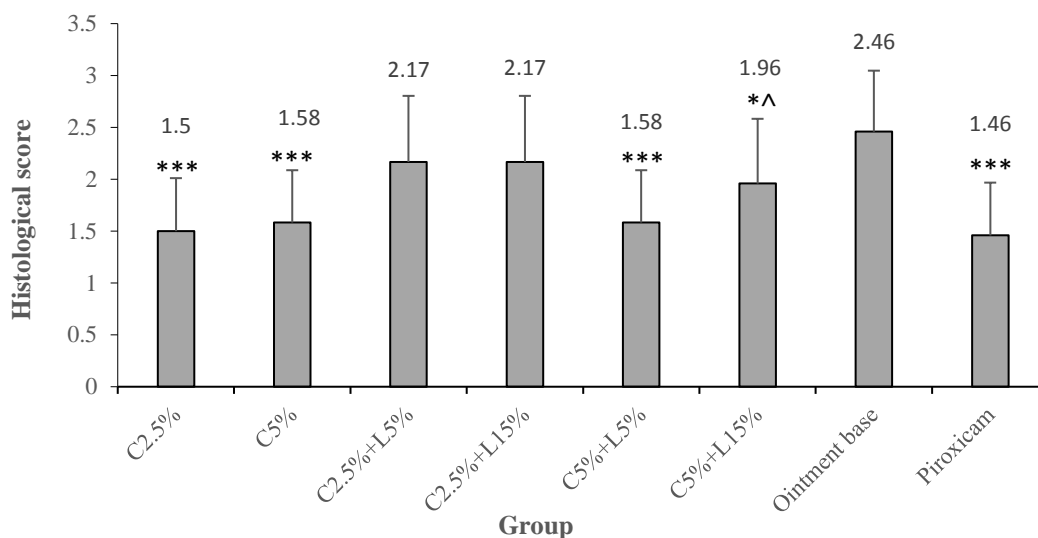


Fig. 3. Histological changes in different groups receiving turmeric/lecithin ointment in arthritis model (C: *Curcuma longa*; L: Lecithin). The data are mean ± SD of six rats. *: P < 0.05, ***: P < 0.001 compared to ointment base. ^: P < 0.05 compared to Piroxicam

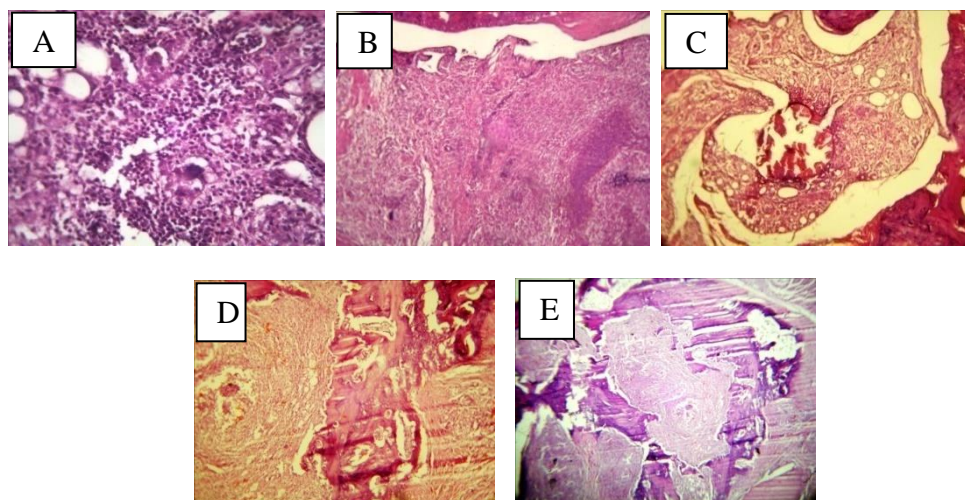


Fig. 4. Histopathological changes in different groups receiving turmeric/lecithin ointment; A: extensive focal infiltrates, B: extensive infiltrates invading the capsule with aggregate formation, C: pannus formation with surface destruction of joint, D: pannus formation with extensive destruction of joint, E: severe inflammation with extensive destruction of joint

4. Discussion

Turmeric has been used in traditional medicine for a long time. It is used in various disorders including rheumatism, fever, dyspepsia, intestinal parasites, hepatic failure, and skin disorders [1]. In Iranian folk medicine, mixture of turmeric powder and egg yolk is

externally used for strains and dislocations. Since strains and dislocations are followed by inflammation which causes joint pain and immobility, logic for using turmeric in this situation is its anti-inflammatory properties [10]; but, the role of egg yolk in this formulation has not been known. Egg yolk contains lecithin

which is a phospholipid [11]. Phospholipid-phytochemical complexes have been established to improve absorption of poorly water-soluble phytochemicals due to amphipathic effects of the phospholipid [12]. Researchers in an experiment on excised human skin mounted in Franz diffusion cell proved that lecithin acted as penetration enhancer for cutaneous absorption of two flavonoids (naringenin and hesperetin) and enhanced their photoprotective activity [13]. Several investigations have proved the effect of lecithin in increasing absorption of curcumin as the main active component of turmeric which has weak oral and percutaneous absorption [14-16]. Many turmeric formulations containing lecithin have been prepared for improving curcumin penetration via oral and topical usage. During an investigation, a curcumin-based lecithin tablet improved osteo-muscular pain in rugby players. In fact, lecithin ameliorates weak curcumin oral absorption [17]. It has also been used for preparing polymeric micellar drug delivery system for curcumin to overcome poor bioavailability of the compound [18]. During another study, in order to improve the poor curcumin penetration, nanoemulsion formulations with different enhancers including lecithin were prepared and the results showed that the nanoemulsions significantly enhanced curcumin penetration [19]. In study which was conducted on skin rat, curcumin absorption in presence of lecithin from turmeric gel was investigated. It was established that lecithin could increase curcumin absorption [20]; therefore, it is expected that lecithin increases turmeric absorption and enhances its anti-inflammatory effect. In the present investigation, herbal ointments were prepared using different concentrations of turmeric extract (2.5 & 5 %) with or without lecithin (5 & 15 %) and their effects on chronic inflammation of rat wrist joint

induced by complete Freund's adjuvant were assessed by determination of arthritis index, TNF- α concentration and histopathological changes of the joints. Comparing the results of the experiment demonstrated not only lecithin had no effect on anti-inflammatory properties of turmeric extract, but also turmeric 2.5 % ointment showed the best activity. In previous studies, turmeric formulations have been prepared with low concentrations of turmeric where lecithin was used to enhance the penetration and thus the drug efficacy; however in our study, the formulation was provided regarding the folklore knowledge which consisted of high concentrations of turmeric. The efficacy of this high concentration formulation was not enhanced by increasing the turmeric content showing that lecithin did not have a role of penetration enhancer but was used as a binder to keep the formulation on injury site for several hours. In folk medicine, the mixture is put on the cotton dress like a paste and attached on the inflamed area; therefore, turmeric alone acts as an anti-inflammation agent in the formulation which has been demonstrated during previous investigations [4-6]. It has been established that curcumin is the most responsible component for the plant activity and has a potent anti-inflammatory property. It is capable of interacting with numerous molecular targets involved in inflammation. Curcumin modulates the inflammatory response by down-regulating the activity of cyclooxygenase-2 (COX-2), lipoxygenase, and inducible nitric oxide synthase (iNOS) enzymes; inhibits the production of the inflammatory cytokines tumor necrosis factor-alpha (TNF- α), interleukin (IL) -1, -2, -6, -8, and -12, monocyte chemoattractant protein (MCP), and migration inhibitory protein; and down-regulates mitogen-activated and Janus kinases [21-25]. The results of the present study were in

agreement with the effect of curcumin on TNF- α which is a specific factor in inflammatory disorders such as Rheumatoid arthritis.

5. Conclusion

In summery, in order to prepare a dosage form as anti-inflammatory agent for strains and dislocation according to Iranian folk medicine in industrial scale, turmeric ointment 2.5 % is an ideal form because of good physical characteristics, better results compared to other formulations containing turmeric/lecithin, less concentration of turmeric making it cheaper which is economically important.

Author contributions

Homa Hajimehdipoor and Somayeh Esmaeili supervised formulation part and data analysis. They also edited the manuscript. Saleh Omid-Malayeri and Soheil Omid-Malayeri performed

the experimental studies. Saleh Omid-Malayeri prepared the manuscript. Hamid Reza Rasekh supervised pharmacological part. Hamid Reza Moghimi was involved in study design. Roya Yaraee and Mohammad Reza Jalali Nodoushan were involved in TNF- α analysis and pathology part, respectively.

Conflict of interest

The authors declare that there is no conflict of interest.

Acknowledgements

The results were obtained from Pharm.D. thesis (Saleh Omid-Malayeri) and was granted by School of Traditional Medicine, Shahid Beheshti University of Medical Sciences, Tehran, Iran (no: 114).

References

1. Watson RR and Preedy VR. Botanical medicine in clinical practice. Cabi. London. 2008, pp. 672-673.
2. Dei Cas M and Ghidoni R. Dietary curcumin: correlation between bioavailability and health potential. *Nutrients* 2019; 11: 1-14.
3. Singh A, Shekhar Ch, Varun Kumar Singh VK and Reddy KRC. Turmeric (*Curcuma longa*) an adaptable drug in ayurveda: a review. *Indian J. Agric. Allied Sci.* 2017; 3(1): 78-84.
4. Jacob A, Wu R, Zhou M and Wang P. Mechanism of the Anti-inflammatory Effect of Curcumin: PPAR- γ Activation. *PPAR Res.* 2007; 2007: 1-5.
5. Boroumand N, Samarghandian S and Hashemy SI. Immunomodulatory, anti-inflammatory, and antioxidant effects of curcumin. *J. Herbmed Pharmacol.* 2018; 7(4): 211-219.
6. Gan Y, Zheng Sh, Baak JPA, Zhao S, Zheng Y, Luo N, Liao W and Fu Ch. Prediction of the anti-inflammatory mechanisms of curcumin by module-based protein interaction network analysis. *Acta Pharm. Sinic. B* 2015; 5(6): 590-595.
7. Rauta S, Bhadoriyaa SS, Uplanchiwara V, Mishrab V, Gahanea A and Kumar S. Lecithin organogel: A unique micellar system for the delivery of bioactive agents in the treatment of skin aging. *Acta Pharm. Sinic. B.* 2012; 2(1): 8-15.
8. Editorial Board. British pharmacopeia. 7th ed. The Stationary Office. London. 2013. Turmeric monograph.
9. Chang Y, Wu Y, Wang D, Wei W, Qin Q, Wie G, Zhang L, Yan Sh, Chen J, Wang Q, Wu


- H, Xio F, Sun W, Jin J and Wang W. Therapeutic effects of TACI-Ig on rats with adjuvant-induced arthritis via attenuating inflammatory responses. *Rheumatology* 2011; 50(5): 862-870.
- 10.** Panahi Y, Fazlolahzadeh O, Atkin SL, Majeed M, Butler AE, Johnston TP and Sahebkar A. Evidence of curcumin and curcumin analogue effects in skin diseases: A narrative review. *J. Cell Physiol.* 2018; 1-14.
- 11.** Pichot R, Watson RL and Norton IT. Phospholipids at the interface: current trends and challenges. *Int. J. Mol. Sci.* 2013; 14: 11767-11794.
- 12.** Kidd PM. Bioavailability and activity of phytosome complexes from botanical polyphenols: the silymarin, curcumin, green tea and grape seed extracts. *Altern. Med. Rev.* 2009; 14: 226-246.
- 13.** Saija A, Tomaino A, Trombetta D, Giacchi M, De Pasquale A and Bonina F. Influence of different penetration enhancers on in vitro skin permeation and in vivo photoprotective effect of flavonoids. *Int. J. Pharmaceutics.* 1998; 175: 85-94.
- 14.** Kumar M, Ahuja M and Sharma SK. Hepatoprotective study of curcumin-soya lecithin complex. *Sci. Pharm.* 2008; 76: 761-774.
- 15.** Leeseon K and Ji YK. Chondroprotective effect of curcumin and lecithin complex in human chondrocytes stimulated by IL-1 β via an anti-inflammatory mechanism. *Food Sci. Biotechnol.* 2019; 28(2): 547-553.
- 16.** ZAmarioli CM, Martins RM, Carvalho EC and Freitas LAP. Nanoparticles containing curcuminoids (*Curcuma longa*): development of topical delivery formulation. *Rev. Bras. Farmacog.* 2015; 25: 53-60.
- 17.** Di Pierro F, Zacconi P, Bertuccioli A, Togni S, Eggenhoffner R, Giacomelli L and Scaltrini S. A naturally-inspired, curcumin-based lecithin formulation (Meriva formulated as the finished product Algocur) alleviates the osteo-muscular pain conditions in rugby players. *Eur. Rev. Med. Pharm. Sci.* 2017; 21: 4935-4940.
- 18.** Chen LC, Chen YC, Su CY, Wong WP, Sheu MT and Ho HO. Development and characterization of lecithin-based self-assembling mixed polymeric micellar (saMPMs) drug delivery systems for curcumin. *Sci. Rep.* 2016; 6: 37122-37132.
- 19.** Yousef SA, Mohammed YH, Namjoshi S, Grice JE, Benson HAE, Sakran W and Roberts MS. Mechanistic evaluation of enhanced curcumin delivery through human skin in vitro from optimized nanoemulsion formulations fabricated with different penetration enhancers. *Pharmaceutics* 2019; 11(12): 639-658.
- 20.** Shahmir B. Extraction of curcumin from *Curcuma amara* rhizome and investigating the effect of enhancers on percutaneous absorption of curcumin and total rhizome extract. Pharm D thesis. Shadid Beheshti University of Medical Sciences, Teran, Iran, 2001.
- 21.** Abe Y, Hashimoto S and Horie T. Curcumin inhibition of inflammatory cytokine production by human peripheral blood monocytes and alveolar macrophages. *Pharmacol. Res.* 1999; 39: 41-47.
- 22.** Surh YJ, Chun KS, Cha HH, Han SS, Keum YS, Park KK and Lee SS. Molecular mechanisms underlying chemopreventive activities of anti-inflammatory phytochemicals: down-regulation of COX-2 and iNOS through suppression of NFkappa B activation. *Mutat. Res.* 2001; 480-481: 243-268.

23. Jobin C, Bradham CA, Russo MP, Juma B, Narula AS, Brenner DA and Sartor RB. Curcumin blocks cytokine-mediated NF-kappa B activation and proinflammatory gene expression by inhibiting inhibitory factor I-kappa B kinase activity. *J. Immunol.* 1999; 163: 3474-3483.

24. Huang MT, Lysz T, Ferraro T, Abidi TF, Laskin JD and Conney AH. Inhibitory effects of curcumin on in vitro lipoxygenase and cyclooxygenase activities in mouse epidermis. *Cancer Res.* 1991; 51: 813-819.

25. Jurenka JS. Anti-inflammatory properties of curcumin, a major constituent of *Curcuma longa*: a review of preclinical and clinical research. *Altern. Med. Rev.* 2009; 14(2): 141-153.

How to cite this article: Esmaeili S, Omid-Malayeri S, Hajimehdipoor H, Rasekh HR, Moghimi HR, Omid-Malayeri S, Yaraee R, Jalali Nadoushan MR. The role of lecithin on topical anti-inflammatory activity of turmeric (*Curcuma longa* L.) ointment. *Journal of Medicinal Plants* 2020; 19(76): 89-98.
doi: 10.29252/jmp.19.76.89



فصلنامه گیاهان دارویی

Journal homepage: www.jmp.irپژوهشکده گیاهان دارویی
جهاد دانشگاهی

مقاله تحقیقاتی

نقش لسیتین در اثرات ضدالتهاب موضعی زردچوبه

سمیه اسماعیلی^۱، صالح امید ملایری^۲، هما حاجی مهدی پور^{۱*}، حمیدرضا راسخ^۳، حمیدرضا مقیمی^۴، سهیل امید ملایری^۵، رویا یارایی^۶، محمدرضا جلالی نودوشان^۷^۱ مرکز تحقیقات طب سنتی و مفردات پزشکی و گروه داروسازی سنتی، دانشکده طب سنتی، دانشگاه علوم پزشکی شهید بهشتی، تهران، ایران^۲ گروه فارماکوتکنولوژی، واحد علوم دارویی، دانشگاه آزاد اسلامی، تهران، ایران^۳ گروه اقتصاد و مدیریت دارویی، دانشکده داروسازی، دانشگاه علوم پزشکی شهید بهشتی، تهران، ایران^۴ گروه فارماسیوتیکس، دانشکده داروسازی، دانشگاه علوم پزشکی شهید بهشتی، تهران، ایران^۵ کمیته تحقیقات دانشجویی، دانشکده پزشکی، دانشگاه شاهد، تهران، ایران^۶ گروه ایمونولوژی، دانشکده پزشکی، دانشگاه شاهد، تهران، ایران^۷ گروه پاتولوژی و آناتومی، دانشکده پزشکی، دانشگاه شاهد، تهران، ایران

چکیده

اطلاعات مقاله

مقدمه: زردچوبه گیاهی است که در طب سنتی مصرف فراوان دارد. در طب مردمی ایرانی، مخلوط زردچوبه و زرده تخم مرغ برای رفع التهابات ناشی از دررفتگی و پیچ خوردگی مفاصل استفاده می شود. از آنجایی که لسیتین به عنوان یکی از اجزای زرده تخم مرغ، عاملی جذب افزا می باشد، به نظر می رسد علت استفاده از زرده تخم مرغ افزایش جذب زردچوبه و در نتیجه افزایش اثرات ضدالتهابی آن باشد. هدف: هدف از این تحقیق، یافتن نقش لسیتین در این فرمولاسیون طب مردمی ایرانی بوده است. روش بررسی: پایه پماد با استفاده از موم، وازلین، پارافین و اوسرین تهیه شد. عصاره هیدروالکلی زردچوبه (۲/۵ و ۵ درصد) با لسیتین (۵ و ۱۵ درصد) یا بدون لسیتین به پایه پماد اضافه شدند. اثر ضدالتهابی پمادها در آرتریت موش صحرایی بررسی شد. پمادها روزی یکبار به مدت ۲۰ روز روی مفاصل ملتهب مالیده شدند و اندیس آرتریت، $TNF-\alpha$ و تغییرات هیستوپاتولوژیکی مفاصل بررسی شدند. نتایج: اندیس آرتریت در همه گروهها کاهش یافت ولی در گروههای زردچوبه ۲/۵ درصد و زردچوبه ۵ درصد با لسیتین ۱۵ درصد تغییرات معنی دار بود. $TNF-\alpha$ در همه گروهها کاهش داشت، ولی کاهش آن در گروه زردچوبه ۲/۵ درصد بیشتر بود. تغییرات هیستوپاتولوژیک در گروههای زردچوبه در مقایسه با گروه پایه پماد کمتر مشاهده شد. نتیجه گیری: به نظر می رسد درمانگرهای محلی ایرانی، زرده تخم مرغ را به عنوان چسباننده در فرمول استفاده می کنند. به عبارت دیگر زردچوبه ۲/۵ درصد بدون لسیتین در فرم پماد نسبت به سایر فرمولاسیونها ارجحیت دارد.

گل واژگان:

زردچوبه

التهاب

طب مردمی ایرانی

موش صحرایی

مخففها: C، زردچوبه؛ L، لسیتین؛ $TNF-\alpha$ ، فاکتور نکروز توموری-آلفا؛ S.C، زیرجلدی؛ COX-2، سیکلواکسیژناز-۲؛ iNOS، نیتریک اکسید سنتاز القایی؛ IL، اینترلوکین؛ MCP، پروتئین جاذب شیمیایی مونوسیت

* نویسنده مسؤول: hajimehd@sbm.ac.ir

تاریخ دریافت: ۳۱ فروردین ۱۳۹۹؛ تاریخ دریافت اصلاحات: ۵ آبان ۱۳۹۹؛ تاریخ پذیرش: ۱۱ آبان ۱۳۹۹

doi: 10.29252/jmp.19.76.89

© 2020. Open access. This article is distributed under the terms of the Creative Commons Attribution-NonCommercial 4.0 International License (<https://creativecommons.org/licenses/by-nc/4.0/>)