

## Evaluation of Protective Effects of Nano-formulated Silymarin Against UV Radiation on Guinea Pig Skin

Ahmadi-Ashtiani HR (Ph.D. Student)<sup>1,2</sup>, Rezazadeh Sh (Ph.D.)<sup>2</sup>, Barkhordari E (M.D.)<sup>3</sup>, Hekmat-Nazemi N (D.V.M.)<sup>2</sup>, Baghaei M (Pharm.D.)<sup>4</sup>, Bokaie S (Ph.D.)<sup>5</sup>, Rastegar H (Ph.D.)<sup>6\*</sup>

1- Department of Clinical Biochemistry, School of Medical Science, Tarbiat-e-Modarres University, Tehran, Iran & Biochemistry and Nutrition Department, Zanjan University of Medical Sciences, Zanjan, Iran

2- Institute of Medicinal Plants, ACECR, Tehran, Iran

3- Tehran University of Medical Science, Tehran, Iran

4- Cosmetics Industry Researcher, Tehran, Iran

5- Faculty of Veterinary, University of Tehran, Tehran, Iran

6- Ministry of Health and Medical Education, Food & Drug Laboratory Research Center, Tehran, Iran

\*Corresponding author: Ministry of Health and Medical Education, Food & Drug Laboratory Research Center, Tehran, Iran

Tel & Fax: +98-21-66462876

Email: mh\_rastegar@yahoo.com

Receive: 15 Nov. 2009

Acceptance: 8 March 2010

### Abstract

**Background:** As increased outdoor activities of people, they are more exposed to UV radiation, which causes harmful effects on skin. Silymarin has protective potentials against DNA damage and non-melanoma skin cancers, and also it has anti-oxidant, anti-inflammatory, and immune regulation characteristics. Nano formulation of plant material showed to be more effective than common ones.

**Objective:** In present study, nano-formulated silymarin was used in a cream, and its effects were investigated against destructive effects of UV rays.

**Methods:** Silymarin standardized extract was prepared, nano formulated in cream base, and applied to skin of the animals. Four groups of animals (n=15) were examined; Group 1; without any treatment (control), Group 2; Vaseline, Group 3; nano-formulated silymarin extract cream, and Group 4; silymarin-carnosine. UV was radiated on the shaved area of the four groups for 45 minutes with dose of 180 mJ/cm<sup>2</sup>. Dermal scaling, skin irregularity, erythema, skin hyperpigmentation, and edema were evaluated in animals. Histopathological observation was done on the skin samples of the animals.

**Results:** silymarin nano-formulation was effective in decreasing both physical damages and histopathological injuries significantly.

**Conclusion:** from the observed results, it can be concluded that the cream containing nano-formulated silymarin can prevent UV radiation lesions better than pure silymarin.

**Keywords:** Nano-formulation, Silymarin, UV protection, Guinea Pig

## Introduction

Regarding the increase in people's activities, an increase in outdoor activities has become inevitable. Hence, people are more exposed to UV radiation, which has harmful effects on skin [7].

Along with the growth and development of pharmaceutical technology, use of plant-derived medicines has attracted more attention considering their lower costs and side-effects. Milk thistle (*Silybum marianum*) has been used since thousands of years ago for its different beneficial effects [5, 12]. Silymarin inhibits oxidative stress by collecting free oxygen radicals including hydroxyl anions, phenoxi radicals and hypochloric acid in different cells such as of platelets, fibroblasts, liver microsomes and mitochondria [15].

A common and suitable route for applying cosmetic and medicinal materials is using cream and gel formulations. However, the particles lay on the skin surface are vulnerable to be degraded by light. Different capsulation systems such as liposomes, micro-emulsions, multiple emulsions and solid lipid particles are used in cosmetics formulations. These capsulation systems can lead to controlled release of the capsulated particles, as well as protecting the capsulated substances partially; for instance, by reducing their contact with oxygen or other substances. Nevertheless, nanotechnology has some disadvantages, too. Histological studies in this field indicate that nanoparticles can damage DNA and cause cancer. Nanoparticles are very small, able to pass cell membrane and protection layer, and impair the cell activities. From another view, they are large enough to cause significant undesirable effects [1].

Considering the protective potentials of silymarin (prepared from milk thistle) against DNA damage and non-melanoma skin cancers,

and also its anti-oxidant, anti-inflammatory, and immune modulation characteristics, a nano-formulated sun screen cream was produced in which some components having synergism with silymarin properties. In this paper, we have covered the studies which were previously carried out on silymarin effects. For the first time, nano-formulated silymarin was used in a cream, and its effects against destructive effects of UV rays were investigated.

## Materials and Methods

### Plant materials

Seeds of cultivated *Silybum marianum* (a Chinese product, Hungarian accession, Plantarum Medicinarum Horticus Botanicum Institute) were collected from the field (Karadj City, Iran) after one year cultivation (August 2005).

### Extraction procedure from the seeds

Preparation of Silymarin extract was a two-step process, in which powdered seeds were first defatted. In order to defatten the seeds, about 1000 g of finely powdered seeds were weighted and its extract was obtained first with n-hexane for 4 hours and then with ethyl acetate for 8 hours in a Soxhlet extractor. Ethyl acetate solution was evaporated under reduced pressure on a rotary evaporator instrument at a temperature not exceeding 50°C and silymarin extract was obtained as a soft yellow powder.

Methanol solutions (1.2 mg/mL) of silymarin sample were used for HPLC analysis after filtration [9].

### Reference solutions

An accurately weighted quantity of standard silybinin (Sigma, USA) was

dissolved in and diluted with methanol to obtain solutions with known concentrations (0.004, 0.02 and 0.2 mg/mL). The calibration curve was plotted based on the areas of the sum of the silybinin A and silybinin B peaks versus the concentration of silybinin solution, and a regression line was obtained for calibration (correlation coefficient=1). The percentage of each relevant component of silymarin sample was calculated as silybinin and external standard method was used [9].

### Silymarin standard solution

Methanol solution of standard silymarin (Sigma, USA) (0.7 mg/mL) was used to understand the chromatographic behavior of the flavonolignan components of silymarin in analytical conditions.

### HPLC assay

The analysis of silymarin samples was carried out using a Knauer K2600A liquid chromatography (Germany), equipped with a Nucleosil C18 (150 × 4.6 mm I.D, 5 μm) column. A mixture of methanol water (50:50, v/v) served as the mobile phase. The elution has been made in an isocratic mode at a flow rate of 1mL/min and the detection made at 288 nm. Each analysis cycle required 20 min.

### Animals and Skin Test Method

In order to investigate topical effects of nano-formulated silymarin, 60 female Albino guinea pigs (Dukin Hartley race), with the same age (6 months old) (Pasteur Institute, Iran) were chosen. To get adapted to new conditions, they were kept in the same environmental and nutritional conditions (temperature 24°C ±1°C, relative humidity 40%-60%, and 12 hours in light and 12 hours in darkness cycles). At the beginning of the study, guinea pigs were randomly divided into 4 equal groups (no=15). First group did not

receive any treatment, the second group treated with Vaseline, the third group received nano-formulated silymarin and the fourth group received silymarin extract+ carnosine.

At the end of the adaptation phase, 2cm<sup>2</sup> of guinea pigs' back were shaved. In order to subside the possible inflammation caused by shaving, the pigs rested for 48 hours. 30 minutes before each round of UV radiation, nano-formulated silymarin cream and Vaseline were administered on the shaved area of the case and control groups, respectively. Then, UV was radiated on the shaved area of the four groups for 45 minutes with dose of 180 mJ/cm<sup>2</sup>. The dose is provided by a UV lamp with 90cm length, 220V, 30W, wavelength 280-340nm., and adjusted 23 cm far from the animal skin. This process was repeated for 50 days for the four groups. In this study, the animals shaved twice, and after each shave, rested for 48 hours and did not have UV exposure. At the end of the course, in order to carry out tissue pathology study, all guinea pigs were painlessly killed by chloroform and samples were taken from the shaved area for tissue pathology study. After performing the preparation steps, some cross-sections were prepared from each skin sample and studies by light microscope after staining with H&E.

In order to prepare microscopic cross-sections, the following steps were carried out in pathology department:

The samples were put in formalin buffer 10% for 5 days. Tissue dehydration was done by ethyl alcohol 30, 50, 70, 80, and 90 degrees to extract extra amounts of tissue water. Then, in order to remove tissue canescen, opacification was done by xylol. In the next step, tissues samples were laid into paraffin to be formed. Then, each sample was cut into 5 cross-sections with seven micronsthickness by a rotary microtome, and the cross-sections

were put on lamella by a forceps after being poured into water. Sample numbers were written down on lamellas by a diamond pen, and then, lamellas were put in a proper place to be dried. Lamellas staining were done using H&E and then pathology studies were carried out.

### Data analysis method

In order to analyze the data, Chi-square test was used, and in the cases where the expected frequency of more than 20% of table cells was less than 5, Fisher's exact test was used.

## Results

### Analyses of milk thistle extract (silymarin)

Figure 1 shows the chromatographic profile of methanol solutions of prepared silymarin extract sample as compared to that of standard silymarin. The quantitative data obtained from the sample analysis by HPLC are shown in Table 1.

Quantitative analyses showed that the amount of total silymarin extract was 57.78% w/w in comparison to standard one which was 69.82% w/w.

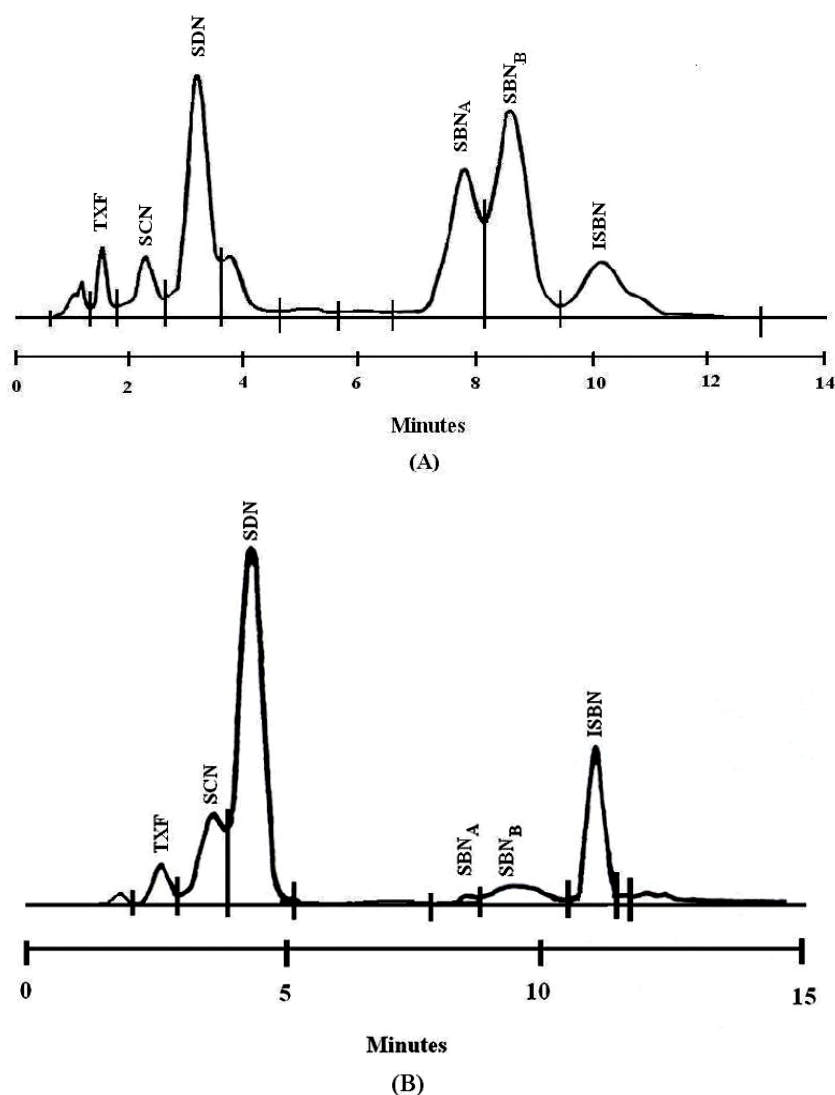


Fig. 1- Chromatograms of standard Silymarin (A) and extracted Silymarin sample (B)

**Table 1- Results of HPLC analysis of silymarin samples**

Silymarin samples	Content (g/100g DW)					Total Silymarin
	Taxifolin	Silychristin	Silydianin	Silybinin <sup>a</sup>	Isosilybinin <sup>b</sup>	
SM-S	3.14 ± 0.35	5.31 ± 1.65	16.76 ± 0.31	40.94 ± 1.5	3.67 ± 0.60	69.82
SM-C	0.59 ± 0.19	11.47 ± 1.83	2.78 ± 1.09	38.68 ± 2.61	4.26 ± 1.87	57.78

<sup>a</sup>Sum of silybinin diastereomers

<sup>b</sup>Sum of isosilybinin diastereomers

Abbreviations: SM-S, standard silymarin; SM-C, silymarin from cultivated plants; Values are expressed as means ± SD

### Clinical observations

Some clinical features such as skin scaling, skin irregularity, erythema, skin hyperpigmentation, and edema were evaluated in this study.

The clinical observations are as follows and abbreviated in table 2:

In group 1, who did not receive any treatments, all the features were observed at the highest level (100%).

In group 2, treated with Vaseline, dermal scaling, skin irregularity, erythema and hyperpigmentation, and edema were observed in 5 cases (33.33%), 8 cases (53.33%), 10 cases (66.66%), and 12 cases (80%), respectively.

In group 3, only dermal hyperpigmentation was observed in 5 cases (33.33%).

In group 4, which received topical silymarin extract, dermal scaling, and edema was not observed in any cases. In this group, skin irregularity and dermal hyperpigmentation were observed in 5 (33.33%) and 8 cases (53.33%), respectively.

Statistical analyses of clinical observations are as follows:

**Skin scaling:** group 1 had statistically significant difference with groups 2, 3, and 4 ( $p < 0.01$ ), and group 2 had a significant difference with group 3 and 4 ( $p < 0.05$ ). Group 3 and 4 were not statistically different ( $p = 1.000$ ).

**Skin irregularity:** Group 1 had significant statistical difference with groups 2, 3, and 4 ( $p < 0.01$ ), the difference between group 2 and group 3 was statistically significant, but not between group 2 and group 4 ( $p = 0.4611$ ). There was significant difference between group 3 and group 4 ( $p < 0.05$ ).

**Erythema:** Group 1 had statistically significant difference with group 2 ( $p < 0.05$ ), and group 3 and group 4 ( $p < 0.01$ ). Group 2 had not significant difference compared to both group 3 and group 4 ( $p = 0.1441$ ,  $p = 0.7094$ , respectively), as well as group 3 and group 4 ( $p = 0.4611$ ).

**Hyperpigmentation:** Groups 1 and 2, and also groups 3 and 4 had significant difference ( $p < 0.05$ ,  $p < 0.01$ , respectively). Groups 2 and 3, groups 2 and 4, and groups 3 and 4 were not significantly different ( $p = 0.1441$ ,  $p = 0.7094$ , and  $p = 0.4611$ , respectively).

**Table 2- Clinical features which observed on UV rayed guinea pig skin after treatment with formulations (silymarin and nano-formulated silymarin)**

Group	Group 1 (without any treatment)	Group 2 (Vaseline)	Group 3 (nano- formulated silymarin extract cream)	Group 4 (silymarin- carnosine)
<b>Clinical observation</b>				
Dermal scaling	All cases	33.33%	not observed	not observed
Skin irregularity	All cases	53.33%	not observed	33.33%
Erythema	All cases	66.66%	33.33%	53.33%
Skin hyperpigmentation	All cases	66.66%	33.33%	53.33%
Edema	All cases	80%	not observed	not observed

Edema: There was significant statistical difference between group 1 and groups 2, 3, and 4 ( $p < 0.01$  for groups 3 and 4). Group 2 was significantly different from groups 2 and 3 in this regard ( $p < 0.01$ ), and groups 3 and 4 were not significantly different ( $p = 1.000$ ).

#### Results of microscopic pathology studies:

These observations their comparisons are listed in tables 3 and 4 respectively.

In group 1; epidermal hyper keratosis, hyperpigmentation exocytosis, , chromatin discoloration in nucleus of epidermal squamous cells, perifolliculitis, dermal vascular hyperemia, edema and dermal thickness increase, infiltration of plasma cell lymphocytes and eosinophyls into dermis were observed in all cases. Epidermal vesicles and dermal vascular fibrinoid necrosis was not observed in any case. Epidermal keratin pearl, lymphocyte infiltration into sebaceous glands, and dermal vasculitis were observed in 3 cases (20%), 10 cases (66.66%), and 12 cases (80%), respectively.

In group 2; treated with Vaseline, exocytosis, epidermal Vesicles, chromatin discoloration of squamous cell nucleolus in

epidermis, and fibrinoid necrosis of dermis vasculature were not observed in any cases. In this group, epidermal hyperkeratosis, acanthosis, and dermal vasculitis was observed in 8 cases (53.33%), while epidermal hyperpigmentation, keratin pearl in epidermis, perifolliculitis, lymphocyte infiltration into sebaceous glands and dermal hyperemia, and increased dermal thickness and inflammatory cells infiltration into dermis were reported in 9 cases (60%), 2 cases (13.33%), 5 cases (33.33%), 6 cases (40%), 11 cases (73%), respectively.

In group 3 which received nano-formulated silymarin cream, only hyperemia was reported in 8 cases (53.33%).

In group 4, which received topical silymarin + carnosine, 8 cases of epidermal hyper pigmentation (53.33%), 12 cases of dermal hyperemia (80%), and 5 cases of edema and dermal thickness increase and inflammatory cell infiltration into dermis (33.33%) were reported. Other features were not observed in this group.

Some of pathological features can be seen in figure 2.

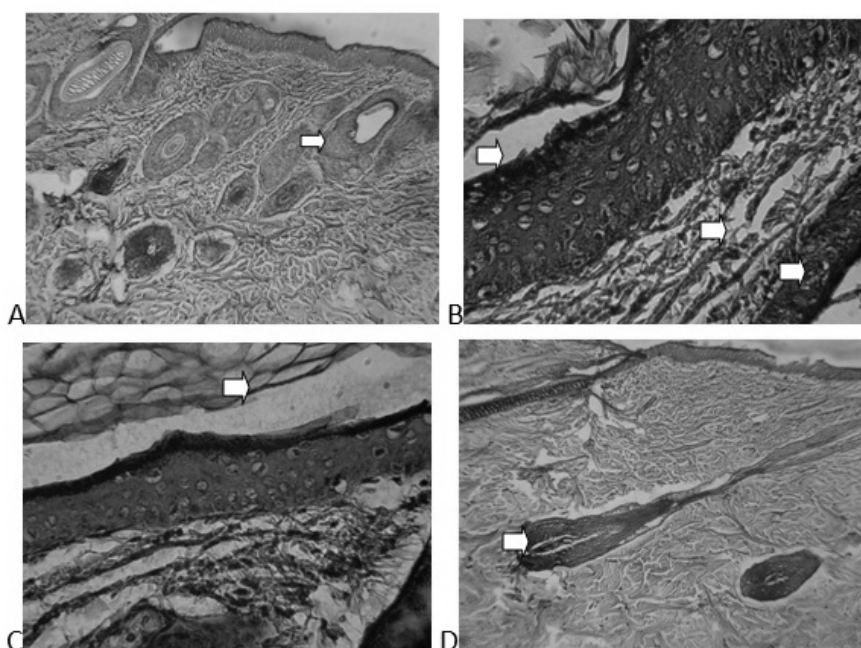
**Table 3- Results of microscopic pathology studies which observed on UV rayed guinea pig skin after treatment with formulations (silymarin and nano-formulated silymarin)**

Microscopic observation	Group			
	Group 1 (without any treatment)	Group 2 (Vaseline)	Group 3 (nano- formulated silymarin cream)	Group 4 (Silymarin + carnosine)
Epidermal hyperkeratosis	All cases	53.33%	not observed	not observed
Epidermal hyperpigmentation	All cases	60%	not observed	53.33%
lymphocyte infiltration into epidermis (exocytosis)	All cases	not observed	not observed	not observed
Keratin pearl in epidermis	20%	13.33%	not observed	not observed
Epidermal vesicle	not observed	not observed	not observed	not observed
squamous cell proliferation (acanthosis)	All cases	53.33%	not observed	not observed
Chromatin discoloration in the nucleus of epidermal squamous cells	All cases	not observed	not observed	not observed
perifolliculitis	All cases	33.33%	not observed	not observed
Lymphocyte infiltration into sebaceous glands	66.66%	40%	not observed	not observed
dermal vasculitis	80%	53.33%	not observed	not observed
Fibrinoid necrosis in dermal vasculature	not observed	not observed	not observed	not observed
Hyperemia	All cases	40%	53.33%	80%
Edema and dermal thickness increase	All cases	73.33%	not observed	33.33%
Infiltration of lymphocytes; plasma cells, and eosinophils into dermis	All cases	73.33%	not observed	33.33%

**Table 4-** Statistical relations of the data in pathologic features which observed on UV rayed guinea pig skin after treatment with formulations (silymarin and nano-formulated silymarin)

	Comparison of groups 1 and 2	Comparison of groups 1 and 3	Comparison of groups 1 and 4	Comparison of groups 2 and 4	Comparison of groups 2 and 3	Comparison of groups 4 and 3
Epidermal hyperkeratosis	0.01>	0.01>	0.01>	0.01>	0.01>	NS
Epidermal hyperpigmentation	0.05>	0.01>	0.01>	0.01>	0.01>	0.01>
lymphocyte infiltration into epidermis (exocytosis)	0.01>	0.01>	0.01>	NS	NS	NS
Keratin pearl in epidermis	NS	NS	NS	NS	NS	NS
Epidermal vesicle	NS	NS	NS	NS	NS	NS
squamous cell proliferation (acanthosis)	0.01>	0.01>	0.01>	0.01>	0.01>	NS
Chromatin discoloration in the nucleus of epidermal squamous cells	0.01>	0.01>	0.01>	NS	NS	NS
perifolliculitis	0.01>	0.01>	0.01>	0.05>	0.05>	NS
Lymphocyte infiltration into sebaceous glands	NS	0.01>	0.01>	0.05>	0.05>	NS
dermal vasculitis	NS	0.01>	0.01>	0.01>	0.01>	NS
Fibrinoid necrosis in dermal vasculature	NS	NS	NS	NS	NS	NS
Hyperemia	0.01>	0.01>	NS	0.05>	NS	NS
Edema and dermal thickness increase	NS	0.01>	0.01>	0.05>	0.01>	0.05>
Infiltration of lymphocytes; plasma cells, and eosinophils into dermis	NS	0.01>	0.01>	0.05>	0.01>	0.05>





**Fig. 2-** Some of the microscopic images from pathological features of injured skin; A) in this image, keratin pearls can be observed. B) Epidermal hyperplasia, hyperemia, and dermis edema can be observed. C) Hyperkeratosis is seen in this image. D) Folliculitis and perifolliculitis can be observed in this image

## Discussion

Bradley et al. evaluated the effect of silymarin on myeloperoxidase enzyme in dermal and epidermal cells. After two weeks of UV radiation, silymarin decreased the enzyme level 71% and 51% in epidermal and dermal cell, respectively, and consequently reduced inflammation [2].

In other studies carried out by Danneberg (1994) and Mukhtar (2001), the potential of silymarin in inhibition of NO and H<sub>2</sub>O<sub>2</sub> production in intracellular fluid. The results obtained in these studies showed the ability of silymarin in reducing the production of these factors [13].

Hammerberg et al (1996) considered infiltration of CD11b as the index of presences of macrophage and neutrophil cells in inflammatory region. They reported a significant decrease in CD11b (59%) [6].

Katiyar et al. (2001) evaluated the silymarin effect on interleukin 10 decrease in dermal and epidermis using ELISA. The results showed a 58% and 72% decrease in interleukin 10 level in dermis and epidermis ( $p < 0.001$ ), respectively [10].

Katiyar et al (2002) produced inflation by UV radiation at dose of 900 mj/cm<sup>2</sup> for 48 hours in case and control groups. The group treated with silymarin had a 71% decrease in occurrence ( $p < 0.001$ ) and significant decrease in the severity of lesions [11].

In the study carried out by Chatterjee et al. (1999), myeloperoxidase level was evaluated in dermis and epidermis. The group received topical silymarin had a 68% and 54% decrease in the enzyme level in epidermis and dermis, respectively, and a 47% and 41% decrease in epidermal and dermal layers, respectively, in the group received oral silymarin [3].

In the current study, chronic inflammation was produced in the shaved area of skin using UV-B radiation ( $180 \text{ mJ/cm}^2$ ) for 50 days. The lesion observed in the control group (who did not receive silymarin treatment) were hyperkeratosis, hyperpigmentation, exocytosis, chromatin discoloration in the nucleus of squamous cells in epidermis, perifolliculitis, lymphocyte infiltration into sebaceous glands, dermal vasculitis, dermal hyperemia, edema and infiltration of lymphocytes, plasma cells, and eosinophils into dermal region.

As can be observed, the statistical comparison of group 1 (without any treatment) and group 3 (treated by nano-formulated silymarin) shows statistically significant difference in all indices except keratin pearls, epidermal vesicles, and fibrinoid vascular necrosis. Considering microscopic and clinical indices, group 3 was significantly different from group 1, and showed only small percentages of vascular hyperemia.

Statistical comparison of group 3 (treated with nano-formulated silymarin) and group 4 (treated with silymarin extract) showed although the two groups were not significantly different for most indices, there were statistically significant differences in epidermal and dermal hyperpigmentation, increased dermal thickness, and infiltration of inflammatory cells. The findings indicate that the cream containing nano-formulated silymarin performed better than silymarin extract.

It should be noted that a combination of silymarin and carnosine was used in group 4. Carnosine is dipeptide consisted of histidine and beta alanine. Group 3 received silymarin, nano-formulated by carnosine. In order to

confirm that the anti-inflammatory effect of the cream does not rise from carnosine, group 4 received simple combination of carnosine and silymarin to evaluate the effect of carnosine. The results demonstrate that simple combination of silymarin and carnosine is much less effective than silymarin nano-formulated by carnosine in preventing the harmful effects of UV.

Comparison of group 2 (treated with Vaseline as a physical barrier) and group 3 demonstrate that the highest significant statistical difference is present between these two groups, and the two groups were not significantly different only in terms of lymphocyte infiltration into epidermis, keratin pearls, epidermal vesicles, chromatin discoloration, vascular fibrinoid necrosis, and vascular hyperemia. In clinical and microscopic studies, it was demonstrated that group 3 performed much better than group 2 in preventing UV harmful effects, which indicates that the chemical performance of nano-formulated silymarin is more effective than a physical barrier.

Skin lesions caused by UV radiation are due to the formation of oxygen and peroxy radicals and superoxide anions and radicals [8, 9]. Antioxidant characteristics of silymarin led to the positive results observed in the study in preventing UV radiation lesions [4, 14].

Contrary to other studies, this study used clinical and histological methods, but the results were consistent with that of other studies. Comparing the results of this study with those of other studies, it can be concluded that the cream containing nano-formulated silymarin can prevent UV radiation lesions better than pure silymarin.

## References

1. Available from: <http://www.nano.ir>
2. Bradley PP, Pribat DA, Christense RD. Measurement of coetaneous inflammation estimation of neutrophil content with an enzyme marker. *J. Invest Dermatol.* 1982; 78 (3): 206 – 9.
3. Chatterjee ML, Katiyar SK, Mohan RR, Agarwal R. A Flavonoid antioxidant, silymarin, affords exceptionally high protection against tumor promotion in SENCAR mouse skin tumorigenesis model. *Cancer Res.* 1999; 59: 622 – 32.
4. Dragsted LO. Natural antioxidants in chemoprevention. *Arch Toxicol Suppl.* 1998; 20: 209 - 26.
5. Fintelmann V. Modern phytotherapy and its uses in gastrointestinal conditions. *Planta Med.* 1991; 57: 48-52
6. Hammerberg C, Duraiswamy N and Cooper KD: Reversal of immunosuppression inducible through ultraviolet-exposed skin by *in vivo* anti- CD11b treatment. *J. Immunol.* 1996; 157: 5254 - 61.
7. Harrison D. Harrison's principle of internal medicine. By Dennis K, Bickers D, R, Photosensitivity and other reactions to light. 16th E. 2005, pp: 1238 - 50.
8. Huang RP, Wu JX, Fan Y, Adamson ED. UV activates growth factor receptors via reactive oxygen intermediates. *J. Cell Biol.* 1996; 133 (1): 211 - 20.
9. Katiyar SK, Afaq F, Azizuddin K, Mukhtar H. Inhibition of UVB-induced oxidative stress-mediated phosphorylation of mitogen-activated protein kinase signaling pathways in cultured human epidermal keratinocytes by green tea polyphenol (-)- epigallocatechin-3-gallate. *Toxicol Appl Pharmacol.* 2001; 176: 110 – 7.
10. Katiyar SK, Afaq F, Azizuddin K, Mukhtar H. Inhibition of UVB-induced oxidative stress-mediated phosphorylation of mitogen-activated protein kinase signaling pathways in cultured human epidermal keratinocytes by green tea polyphenol (-)-epigallocatechin-3-gallate. *Toxicol. Appl Pharmacol.* 2001; 176 (2): 110 - 7.
11. Katiyar SK. Treatment of silymarin, a plant flavonoid, prevents ultraviolet light-induced immune suppression and oxidative stress in mouse skin. *Int. J. Oncol.* 2002; 21: 1213 - 22.
12. Luper S. A review of plants used in treatment of liver disease. part1. *Altern. Med. Rev.* 1998; 12: 410 - 21.
13. Mukhtar H. Green tea polyphenol-epigallocatechin-3-gallate treatment to mouse skin prevent UV-B induced infiltration of leukocytes, depletion of antigen-presenting cells, and oxidative stress. *J. Leukoc. Biol.* 2001; 69: 719 - 26.
14. Santosh k katiyar. Silymarin and skin cancer prevention: Anti-inflammatory, antioxidant and immunomodulatory effects (Review). 2004; 18: 101 – 12.
15. WHO monographs on selected medicinal plants. World Health Organisation. *Geneva.* 2002; V: 2 pp: 306 - 17.