

## Evaluation Effects of Quercetin on Liver Apoptosis in Streptozotocin-induced Diabetic Rat

Khaki AA (Ph.D.)<sup>1\*</sup>, Khaki A (D.V.M,Ph.D.)<sup>2</sup>, Nouri M (Ph.D.)<sup>3</sup>, Ahmadi-Ashtiani HR (Ph.D. student)<sup>4</sup>, Rastegar H (Ph.D.)<sup>5</sup>, Rezazadeh Sh (Ph.D.)<sup>6</sup>, Fathiazad F (Ph.D.)<sup>7</sup>, Ghanbari M (M.D.)<sup>8</sup>

1- Department of Anatomy, Islamic Azad University, Branch Bonab, Iran

2- Department of Veterinary Pathology Islamic Azad University, Branch Tabriz, Tabriz, Iran

3- Department of Biochemistry, Tabriz Medical Sciences University, Tabriz, Iran

4- Biochemistry & Nutrition Department of Zanzan Medical University, Clinical Biochemistry, Tarbiat-e-Modarres University, School of Medical Science, Department of Clinical Biochemistry, Tehran, Iran

5- Ministry of Health and Medical Education, Food & drug laboratory Research Center, FDLRC, Tehran, Iran

6- Institute of Medical Plants, ACECR, Tehran, Iran

7- Department of Pharmacognosy. Tabriz Medical Sciences University, Tabriz, Iran

8- Medical student, Tabriz Medical Sciences University

\*Corresponding author: Islamic Azad University, Branch Tabriz, Iran

E-mail: arashkhaki@yao.com

Receive: 21 Nov. 2008

Acceptance: 23 Feb. 2009

### Abstract

**Background:** Quercetin is a strong antioxidant and long-term treatment of STZ-diabetic animals and it has been shown to reduce oxidative stress.

**Objective:** Antioxidants have essential effect on spermatogenesis and sperm parameters. Enhanced oxidative stress and changes in antioxidant capacity are considered to play an important role in the pathogenesis of chronic diabetes mellitus.

**Methods:** Wistar male rat (n=40) were allocated into three groups, control group (n=10) and Quercetin (QR) group that received 15mg/kg (IP) QR, (n=10), and Diabetic group that received 55mg/kg (IP) streptozotocin (STZ) (n=20) which was subdivided to two groups of 10; STZ group and treatment group. Treatment group received 55mg/kg (IP) STZ plus 15mg/kg QR, daily for 4 weeks, respectively; however, the control group just received an equal volume of distilled water daily (IP). Diabetes was induced by a single (IP) injection of streptozotocin (55mg/kg). Animals were kept in standard condition. In 28 days after inducing diabetic 5cc blood were collected for TAC, MDA and Ox-LDL levels and Liver tissues of Rat in whole groups were removed then prepared for Apoptosis analysis by Tunel method.

**Results:** Apoptotic cells significantly decreased in group that has received 15mg/kg (IP) Quercetin ( $P<0.05$ ) in comparison to experimental groups ( $P<0.05$ ).

**Conclusion:** Since in our study 15mg/kg (IP) Quercetin have significantly Preventive effect on liver cells damages by reducing number of Apoptotic cells in liver, so it seems that using it can be effective for treatment in Diabetic Rat.

**Keywords:** Apoptosis, Diabetic, Quercetin, Streptozotocin, Liver, Rat



## Introduction

Diabetes is a chronic disease that due to hyperglycemic. Hyperglycemic in long time have side effect in other tissues especially in liver. Liver dysfunctional has seen in Diabetic patients especially in patients with uncontrolled blood sugars level. Liver do regulative effects on blood sugar level with glycconeogenesis and glycogen's ways, disorders in this ways due to disorder in carbohydrate metabolism. Due attention has been paid to the search of effective drugs in the field of traditional Chinese medicine (TCM). Diabetes mellitus is a group of syndromes characterized by hyperglycemia, altered metabolism of lipids, carbohydrates and proteins and an increased risk of complications from vascular diseases [1,2,3]. Enhanced oxidative stress and changes in antioxidant capacity are considered to play an important role in the pathogenesis of chronic diabetes mellitus [4, 5]. Although the mechanisms underlying the alterations associated with diabetes mellitus are presently not well understood, hyperglycemia leads patients to increased oxidative stress because the production of several reducing sugars (through glycolysis and the polyol pathway) is enhanced [6]. These reducing sugars can easily react with lipids and proteins (nonenzymatic glycation reaction), increasing the production of reactive oxygen species (ROS) (6). Diabetes is the most common endocrine disease that leads to metabolic abnormalities involving regulation of carbohydrate metabolism. In addition to imbalanced carbohydrate metabolism, yet another major concern in diabetes is increased oxidative stress.increaesd production of free radicals or ROS formation may induce oxidized LDL (Ox-LDL), which is key step in the sequence of events leading to atherosclerosis Sustained hyperglycemia and

increased oxidative stress, are the major players in the development of secondary complications in diabetes. These abnormalities produce pathologies including vasculopathies, neuropathies, ophthalmopathies and nephropathies, among many other medical derangements [7]. The balance of ROS and antioxidant is a major mechanism in preventing damage by oxidative stress. Therefore, the dietary supplement of antioxidants such as vitamins, flavonoids has been used to prevent the occurrence of many chronic diseases [8, 9]. Many herbal such as: Barberry, Estragon, Rhus coriaria, Cinnamomum zelanicum, *Hypericum perforatum* and onion known anti diabetic effects and use to patient treatment. Quercetin is a well-known flavonoid and a strong antioxidant and long-term treatment of STZ-diabetic animals and it has been shown to reduce oxidative stress [10, 11].we plant to study the effect of Quercetin as a protective on liver cells apoptosis .

## Material and Methods

### Animals

Forty adult Wistar albino male rats were 8 weeks old and weighing  $250 \pm 10$ g, they were obtained from animal facility of pasture institute of Iran. Male rats were housed in temperature controlled rooms ( $25^{\circ}\text{C}$ ) with constant humidity (40-70%) and 12h/12h light/dark cycle prior to use in experimental protocols. All animals were treated in accordance to the Principles of Laboratory Animal Care. The experimental protocol was approved by the Animal Ethical Committee in accordance with the guide for the care and use of laboratory animals prepared by Tabriz medical University.All Rats were fed a standard diet and water. The daily intake of animal water was monitored at least one week

prior to start of treatments in order to determine the amount of water needed per experimental animal. Thereafter, the rats were randomly selected and divided into control (n=10) and Quercetin (QR) group that received 15mg/kg QR (IP), (n=10), and Diabetic group that received 55mg/kg (IP) streptozotocin (STZ) (n=20) which was subdivided to two groups of 10; STZ group and treatment group. Treatment group received 55mg/kg (IP) STZ plus 15mg/kg QR (IP). the control group just received an equal volume of 1cc distilled water daily (IP). Diabetes was induced by a single intra peritoneal (I.P) injection of streptozotocin (STZ, Sigma- U.S.A.) in 0.1 M citrate buffer (pH 4.0) at a dose of 55 mg/kg body weight. Quercetin (QR) injections were continued to the end of the study (for 4 weeks), [12].

### Induction of experimental type 1, Diabetes

Experimental type 1 diabetes was induced in rats by intra peritoneal (I.P) injection of 55 mg/kg streptozotocin (STZ) in distilled water. Control rats were received distilled water, only.

### Blood glucose determination

Blood samples were collected from the tail vein. Basal glucose levels were determined prior to STZ injection, using an automated blood glucose analyzer (Glucometer Elite XL). Sample collections were then made 48 h after STZ injection and blood glucose concentrations were determined and compared between groups. Rats with blood glucose concentrations above 300 mg/dl were declared diabetic and were used in the experimental group. One week after the induction of experimental diabetes, protocol was started.

### Quercetin preparation:

Quercetin powder was obtained from Sigma Chemical Company (St. Louis, MO, USA). It was dissolved and diluted with 20% glycerol in 0.9% normal saline, mixed vigorously and stored in a dark bottle at 4°C. The quercetin solution was freshly prepared each week.

### Surgical Procedure:

In the 28th day, (at the end of the treatment period), the rats were killed with diethyl ether, and liver tissues in control & experimental groups were immediately removed.

### TUNEL analysis of apoptosis

The *in-situ* DNA fragmentation was visualized by TUNEL method (16). Briefly, dewaxed tissue sections were predigested with 20 mg/ml proteinase K for 20 min and incubated in phosphate buffered saline solution (PBS) containing 3 % H<sub>2</sub>O<sub>2</sub> for 10 min to block the endogenous peroxidase activity. The sections were incubated with the TUNEL reaction mixture, fluorescein-dUTP (*in situ* Cell Death Detection, POD kit, Roche, Germany), for 60 min at 37°C. The slides were then rinsed three times with PBS and incubated with secondary anti fluorescein-POD-conjugate for 30 min. After washing three times in PBS, diaminobenzidine-H<sub>2</sub>O<sub>2</sub> (DAB, Roche, Germany) chromogenic reaction was added on sections and counterstained with hematoxylin. As a control for method specificity, the step using the TUNEL reaction mixture was omitted in negative control serial sections, and nucleotide mixture in reaction buffer was used instead. Apoptotic germ cells were quantified by counting the number of TUNEL stained nuclei

per liver tissues cross sections. Cross sections of 100 liver tissues per specimen were assessed and the mean number of TUNEL positive apoptotic cells per cross- section was calculated [13].

#### **Measurement of Serum Total Antioxidant capacity (TAS)**

TAS was measured in serum by means of a commercial kit (Randox Co-England). The assay is based on the incubation of 2, 2'-azino-di-(3-ethylbenzthiazoline sulphonate) (ABTS) with a peroxidase (methmyoglobin) and hydrogen peroxide to produce the radical cation ABTS<sup>+</sup>, which has a relatively stable blue-green color, measured at 600 nm. The suppression of the color is compared with that of the Trolox, which is widely used as a traditional standard for TAS measurement assays, and the assay results are expressed as Trolox equivalent (mmol/L) [14].

#### **Measurement of Serum MDA**

Tissue MDA levels were determined by the thiobarbituric acid (TBA) method and expressed as nmol MDA formed/mL. Plasma MDA concentrations were determined with spectrophotometer. A calibration curve was prepared by using 1,1',3,3'-tetramethoxypropane as the standard [15].

#### **Measurement of Ox-LDL**

Oxidized LDL level was measured by using a Mercodia Oxidized LDL ELISA kit (Lot No. 15904; Mercodia, Uppsala, Sweden). Mercodia Oxidized LDL Competitive ELISA is based on the monoclonal antibody 4E6.

#### **Statistical analysis**

Statistical analysis was done using the ANOVA and test for comparison of data in the control group with the experimental groups. The results were expressed as mean  $\pm$  S.E.M

(standard error of means). P-value less than 0.05 were considered significant and are written in the parentheses.

#### **Amount of apoptotic cells among liver cells**

Number of apoptotic cells colored brown, in diabetic group was ( $12.25 \pm 1.14$ ) and in Quercetin received diabetic group and control group was ( $6.15 \pm 8.17$ ) and ( $1.05 \pm 0.41$ ) respectively. These changes was significant as p value less than 0.05 ( $p < 0.05$ ).

#### **Results of total blood anti oxidant capacity**

Amount of total blood anti oxidant capacity in control group was ( $0.70 \pm 0.03$  mmol/ml) and in experimental groups was  $0.75 \pm 0.03$ ,  $0.32 \pm 0.04$  and  $0.61 \pm 0.05$  mmol/ml respectively. Statistic analysis Dunnett (one side) shows significant differences between experimental groups in comparison to control group ( $p < 0.05$ ) (Table 1).

#### **Results of MDA (malondi aldehyde) level in blood**

MDA level in control group was  $0.25 \pm 0.04$  mmol/L and in experimental groups was  $0.30 \pm 0.212$ ,  $4.1 \pm 0.06$ ,  $1.1 \pm 0.08$  mmol/L respectively.

Statistic analysis Dunnett (one side) shows significant differences between experimental groups in comparison to control group ( $p < 0.05$ ) (Table 1).

#### **Results of OX-LDL (aldehyde oxidase) level in blood**

OX-LDL level in control group was  $3.1 \pm 0.05$  u/l and in experimental groups was  $3.0 \pm 0.45$ ,  $5.6 \pm 0.85$ ,  $4.9 \pm 0.80$  u/l respectively.

Statistic analysis Dunnett (one side) shows significant differences between experimental groups in comparison to control group ( $p < 0.05$ ) (Table 1).

Table 1

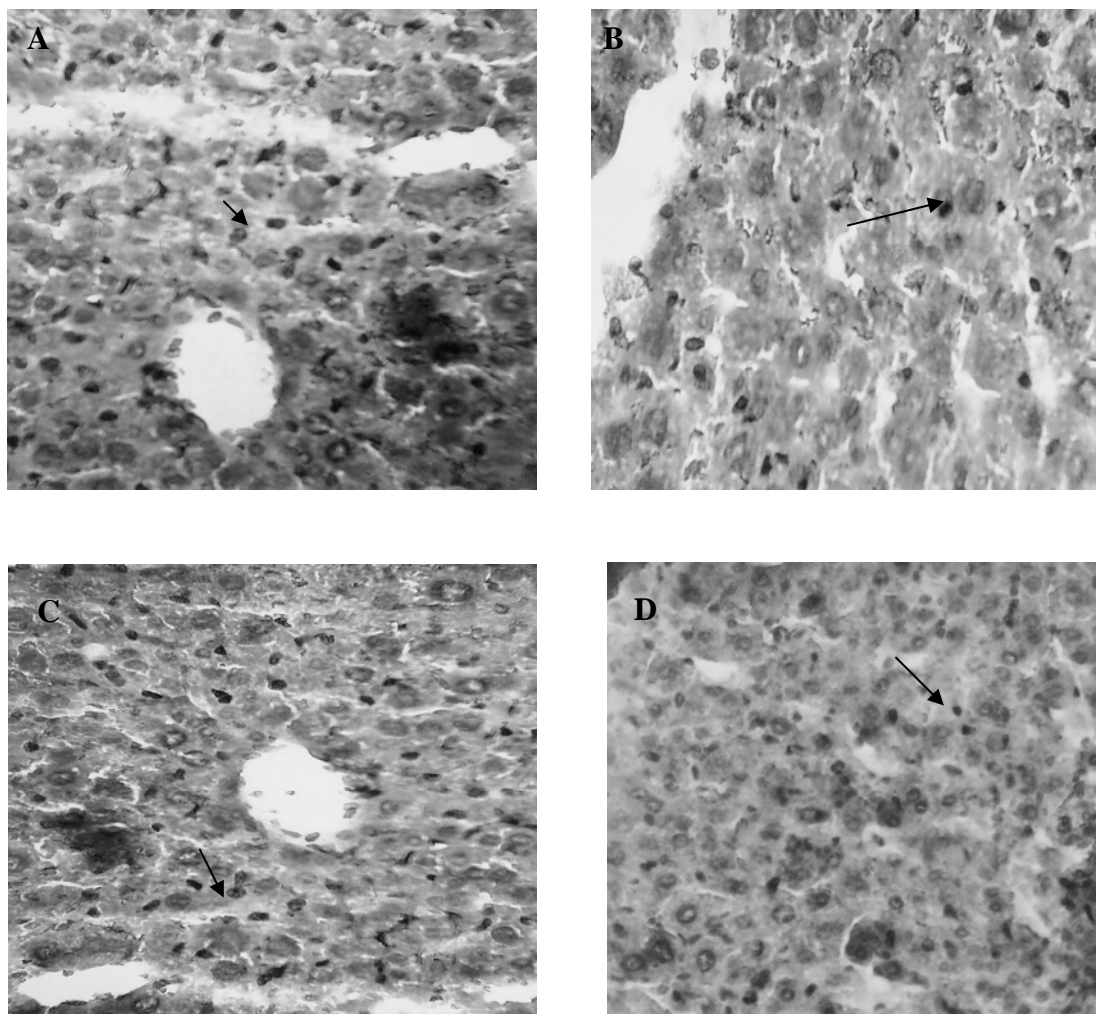
Groups	control  (n=10)	Quercetin (15mg/kg(IP))  (n=10)	STZ (55mg/kg (IP))  (n=10)	Quercetin +Stz 55mg/kg (IP) streptozotocin plus15mg/kg Quercetin (n=10)
Apoptotic cells	1.05±0.41	1.01±8.17	12.25±1.14* (0.006)	6.15±8.17* (0.004)
(TAC) (nmol/ml)	0.70±0.03	0.75±0.03 * (0.006)	0.32±0.04 * (0.003)	0.61±0.05 * (0.004)
(MDA) (nmol/ml)	0.25±0.04	0.30±0.212 * (0.004)	4.1±0.06 * (0.008)	1.1±0.08 * (0.005)
OX-LDL (aldehyde oxidase (u/l)	3.1±0.05	3.0±0.45 (0.108)	5.6±0.85 (0.061)	4.9±0.80 (0.055)

Data are presented as mean ± SE.  
\* P-value less than 0.05 were considered significant and are writing in the parentheses, (compared with the control group).

Discussion and conclusion

Worldwide studies have been done to make use of herbal medicine in different fields of medicine. Base on ancient Persians traditional books Use of herbal medicine has positive effect on treatment of different diseases especially on diabetes mellitus [1]. Numbers of plants which have effect on sexual stimulation are: barberry, tarragon, sumac, cinnamon, some tea specious and onion. Investigation into chemical compounds of onion and ginger shows these plants contain antioxidant agent [2, 11].Onion contains A, B, C vitamins, flavonoids and selenium which their antioxidant role has been proved. Make use of onion and Quercetin in diabetic patient treatment has been experimented [16, 17]. Investigations show onion and Quercetin decrease serum glucose level [18] but this reduction with onion has been significant [18,19]. Also Quercetin decreases oxidative stress and blood vessels damage in diabetic rats [20, 21]. Other investigations show Quercetin increases the level of blood insulin and serum Ca<sup>2+</sup> and Mg<sup>2+</sup> [20, 21, 22]. Investigations show liver has an important role

in carbohydrate metabolism since it is responsible for the balance of blood glucose level by means of glycogen sis and glycogenolysis therefore impaired hepatic function impairs metabolic homeostasis of glucose [2, 3]. In the presence of impaired glucose metabolism and occurrence of hyperglycemia, genes involved in fatty acid storage were activated [4]. On the other hand, liver diseases can induce diabetes mellitus. This type of diabetes mellitus is clinically different from that of type II diabetes mellitus since it is less frequently associated with microangiopathy [22]. Insulin resistance occurs in muscular and adipose tissues combined with hyper insulinemia are pathophysiological bases of diabetes in liver disease [23]. The etiology of liver disease is important in the incidence of diabetes mellitus since non alcoholic fatty liver disease (NALFD), alcohol, hepatitis C virus (HCV) and hemachromatosis are frequently associated with diabetes mellitus [22]. Investigations show liver tissue damage and apoptosis induced by diabetes mellitus increase active



#### Photographs:

- A) All liver cells are seen in normal group, Apoptotic cells (dark brown) are limited to diss area TUNEL staining. ( $\times 400$ )
- B) All liver cells are seen in Quercetin group, Apoptotic cells (dark brown) are limited to diss area TUNEL staining. ( $\times 400$ )
- C) Increase Apoptotic cells (dark brown) in diabetic group TUNEL staining. ( $\times 400$ )
- D) Decreased Apoptotic cells (dark brown) in diabetic group which receive Quercetin. TUNEL staining. ( $\times 400$ )

O<sub>2</sub> species. Flavonoids as an antioxidant factor found in nutrient such as fruit, vegetables, tea and black burgundy grape [24]. Flavonoids value in daily mail varies from 16 mg to 1000 mg. Quercetin as an important and

main flavonoids found in human mail [25]. Investigations show Quercetin absorbs in small bowel. Useful effect of Quercetin in human health involves prevention of diabetes induced cataract, reduced blood vessels

fragility, anti microbial, anti viral, anti allergy, and anti inflammatory effects and prevention of platelet aggregation [25, 26, 27, 28]. One of the Quercetin anti oxidant mechanism is removal of free radical such as xanthine superoxide and xanthine oxidase [29]. Investigations show Quercetin in the chicken spermatogonial cell culture not only doesn't have harmful effects but also increases amount of spermatogonial cells and decreases oxidative effects. In this study like pervious investigations Quercetin decreases malondy aldeid and increases serum anti oxidant capacity [30, 31]. Pervious investigations show O<sub>2</sub> lacked specious cause body tissue

damage in diabetic rats [32, 33]. Studies had been done on serum surface of glutathione, catalase, superoxide dismutase, and fat per oxidation in liver, brain, kidney tissue show Quercetin as an antioxidant agent not only decreases free O<sub>2</sub> specious and LDL oxidase in diabetic rats but also has therapeutic potential [34]. Therefore suggested, increased use of herbal medicine, fruit, vegetables, onion, tea and black burgundy grape which are full of flavonoids and Quercetin can decrease side effects of diabetes mellitus on liver tissue in diabetic patient complicated with hepatic diseases.

## References

1. Jiang GY. Practical Diabetes 1st Edition. Beijing: *People's Health Publishing House*: 1996: 295.
2. Holstein A, Hinze S, Thiessen E, Plaschke A, Egberts EH. Clinical implications of hepatogenous diabetes in liver irrhosis. *J. of Gastroenterol Hepatol*. 2002; 17: 677- 68.
3. Tappy L, Minehira K. New data and new concepts on the role of the liver in glucose homeostasis. *J. of Curr Opin Clin. Nutr. Metab Care* 2001; 4: 273 – 7.
4. Baynes JW, Thorpe SR Role of oxidative stress in diabetic complications: a new perspective on an old paradigm. *J. of Diabetes* 1999; 48: 1 - 9.
5. Wolff SP, Jiang ZY, Hunt JV. Protein glycation and oxidative stress in diabetes mellitus and ageing. *J. of Free Radic. Biol. Med*. 1991; 10: 339 - 52.
6. Palmeira CM, Santos DL, Seica R, Moreno AJ, Santos MS. Enhanced mitochondrial testicular antioxidant capacity in Goto-Kakizaki diabetic rats: role of coenzyme Q. *Am. J. Physiol. Cell Physiol*. 2001; 281: C1023 - 8.
7. Sexton WJ, Jarow JP. Effect of diabetes mellitus upon male reproductive function. *J. of Urology* 1997; 49: 508 - 13.
8. Peluso MR. Flavonoids attenuate cardiovascular disease, inhibit phosphodiesterase, and modulate lipid homeostasis in adipose tissue and liver. *J. of Exp Biol. Med.* (Maywood). 2006; 231 (8): 1287 - 99.
9. Mahesh T, Menon VP. Quercetin alleviates oxidative stress in streptozotocin-induced diabetic rats. *J. of Phototherapy Res*. 2004; 18: 123 – 7.
10. Shrilatha B, Muralidhara early oxidative stress in testis and epididymal sperm in streptozotocin-induced diabetic mice: its progression and genotoxic consequences. *J. of Reprod Toxicol*. 2007; 23 (4): 578 - 87.



11. Khaki A, Fathiazad F, Nouri M, Khaki AA, Jabarikh H, Hammadeh M. Evaluation of Androgenic Activity of *Allium cepa* on Spermatogenesis in Rat. *J. of Folia Morphol. (Warsz)*. 2009; 68: 45 - 51.
12. Coskun O, Kanter M, Korkmaz A, Oter S. Quercetin, a flavonoid antioxidant, prevents and protects streptozotocin-induced oxidative stress and beta-cell damage in rat pancreas. *J. of Pharmacol. Res.* 2005; 51 (2): 117 - 23.
13. Khaki A, Novin MG, Khaki AA, Nouri M, Sanati E, Nikmanesh M. Comparative study of the effects of gentamicin, neomycin, streptomycin and ofloxacin antibiotics on sperm parameters and testis apoptosis in rats. *Pak J. Biol. Sci.* 2008; 11 (13): 1683 - 9.
14. Feng R, He W, Ochi H. A new murine oxidative stress model associated with senescence. *J. of Mech Ageing Dev.* 2001; 122: 547 - 9.
15. Quintanilha AT, Packer L, Davies JM, Racanelli TL, Davies KJ. Membrane effects of vitamin E deficiency: bioenergetics and surface charge density studies of skeletal muscle and liver mitochondria. *J. of Ann. NY Acad. Sci.* 1982; 393: 32 - 47.
16. Huang HFS, Linsenmeyer TA, Li MT, Giglio W, Anesetti R, von Hagen J, Ottenweller JE, Pogach L. Acute effects of spinal cord injury on the pituitary-testicular hormone axis and Sertoli cell functions: a time course study. *J. of Androl.* 1995; 16: 148 - 57.
17. Ajay Machha, Francis I. Achike, Ali Mohd Mustafa, nd Mohd Rais Mustafa. Quercetin, a flavonoid antioxidant, modulates endothelium-derived nitric oxide bioavailability in diabetic rat aortas. *J. of Nitric Oxide.* 2007; (16): 442 - 7.
18. Cunha WR, Arantes GM, Ferreira DS, Lucarini R, Silva MLA, Furtado NAJC, da Silva Filho AA, Crottiand AEM, Araújo ARB. Hypoglycemic effect of *Leandra lacunosa* in normal and alloxan-induced diabetic rats. *J. of Fitoterapia.* 2008; 79: 356 - 60.
19. Kanter M, Altan MF, Donmez S, Ocakci A, Kartal ME. The effects of quercetin on bone minerals, biomechanical behavior, and structure in streptozotocin-induced diabetic rats. *J. of Cell Biochem. and Function.* 2007: 747 - 52.
20. Kato A, Minoshima Y, Yamamoto J, Adachi I, Watson AA, Nash RJ. Protective Effects of Dietary Chamomile Tea on Diabetic Complications. *J. of Agric Food Chem.* 2008; 56 (17): 8206 - 11.
21. Custro N, Carroccio A, Ganci A, Scafidi V, Campagna P, Di Prima L, Montalto G. Glycemic homeostasis in chronic viral hepatitis and liver cirrhosis. *J. of Diabetes Metab.* 2001; 27: 476 - 81.
22. Lecube A, Hernandez C, Genesca J, Esteban JI, Jardi R, Simo R. High prevalence of glucose abnormalities in patients with hepatitis C virus infection: a multivariate analysis Considering the liver injury. *J. of Diabetes Care* 2004; 27: 1171 - 5.
23. Skibola CF, Smith MT. Potential health impacts of excessive flavonoid intake. *J. of Free Radi. Biol. Med.* 2000; 29: 375 - 83.
24. Manach C, Morand C, Crespy V, Demigne C, Texier O, Regeat F, Remesy C. Quercetin is recovered in human plasma as conjugated derivatives which retain antioxidant properties. *J. of FEBS Lett.* 1998; 426: 331 - 6.
25. Formica JV, Regelson W. Review of the biology of Quercetin and related bioflavonoids. *Food Chem. J. of Toxicol.* 1995; 33: 1061 - 80.



26. Hertog MG, Hollman PC. Potential health effects of the dietary flavonol quercetin. *Eur. J. of Clin. Nutr.* 1996; 50: 63 – 71.
27. Bors W, Michel C, Stettmaier K. Antioxidant effects of flavonoids. *J. of Biofactors* 1977; 6: 399 – 402.
28. Dok-Go H, Lee KH, Kim HJ, Lee EH, Lee J, Song YS, Lee YH, Jin C, Lee YS, Cho J. Neuroprotective effects of antioxidative flavonoids, quercetin, (1)-dihydroquercetin and quercetin 3-methyl ether, isolated from *Opuntia ficus-indica* var. *saboten*. *J. of Brain. Res.* 2003; 965: 130 – 6.
29. Mi Y, Zhang C. Protective Effect of Quercetin on Aroclor 1254–Induced Oxidative Damage in Cultured Chicken Spermatogonial Cells. *J. of Toxicological Sci.* 2005; 88 (2): 545 – 50.
30. Mi Y, Zhang C, Taya K. Quercetin protects spermatogonial cells from 2, 4-d-induced Oxidative damage in embryonic chickens. *J. Reprod Dev.* 2007; 53 (4): 749 – 54.
31. Chandel A, Dhindsa S, Topiwala S, Chaudhuri A, Dandona P. Testosterone concentration in young patients with diabetes. *J. of Diabetes Care.* 2008; 31 (10): 2013 – 7.
32. Naziroğlu M. Enhanced testicular antioxidant capacity in streptozotocin-induced diabetic rats: protective role of vitamins C and E and selenium. *J. of Biol. Trace Elem. Res.* 2003; 94 (1): 61 – 72.
33. Sanders RA, Rauscher FM, Watkins JB 3rd. Effects of quercetin on antioxidant defense in streptozotocin-induced diabetic rats. *J. of Biochem. Mol. Toxicol.* 2001; 15 (3): 143 – 9.
34. Drobiova H, Thomson M, Al-Qattan K, Peltonen-Shalaby R, Al-Amin Z, Ali M. Garlic Increases Antioxidant Levels in Diabetic and Hypertensive Rats Determined by a Modified Peroxidase Method. *J. of Evid. Based Complement Alternat Med.* 2009; 1 – 7.