

Research Article

Evaluation acute and sub-chronic toxicity assessments of Oleo-gum Resin of *Ferula assa-foetida* L. in Wistar rats

Zahra Tofighi^{1,2}, Razieh Mohammad Jafari³, Masoud Besati⁴, Mostafa Pirali Hamedani², Abbas Hadjiakhoondi^{1,2}, Zahra Baharipour⁵, Ahmad Jariani², Zahra Moiin², Saeed Tavakoli⁶, Saied Goodarzi^{1,*}

¹ Medicinal Plants Research Center, Faculty of Pharmacy, Tehran University of Medical Sciences, Tehran, Iran

² Department of Pharmacognosy, Faculty of Pharmacy, Tehran University of Medical Sciences, Tehran, Iran

³ Experimental Medicine Research Center, Tehran University of Medical Sciences, Tehran, Iran

⁴ Department of Medicinal Chemistry, Medicinal Plants and Drugs Research Institute, Shahid Beheshti University, Tehran, Iran

⁵ School of Pharmacy, International Campus, Tehran University of Medical Sciences, Tehran, Iran

⁶ Medicinal Plants Research Center, Institute of Medicinal Plants, ACECR, Karaj, Iran

ARTICLE INFO

Keywords:

Ferula assa-foetida

Acute toxicity

Sub-chronic toxicity

Essential Oil

ABSTRACT

Background: *Ferula assa-foetida* is an herbaceous plant from Apiaceae family. Several pharmacological effects of oleo-gum resin of this plant were introduced in modern and traditional medicines such as digestive, antimicrobial, anti-diabetic, appetizing, insecticidal, and etc. **Objectives:** This study aimed to acute and sub-chronic toxicity of chloroform fraction of oleo-gum extract of *Ferula* in Wistar rats. The safety of this can guarantee its use in treatment and various industries. **Methods:** Rats in six groups including male and female (kept separately) at different doses (50 mg/kg, 500 mg/kg, and 2000 mg/kg) and two control groups (control and DMSO) were selected to evaluate the acute toxicity of chloroform fraction of *Ferula*. For 30 days, 50 mg/kg and 250 mg/kg of sample was administrated to male and female rats. Mortality, appearance and behavioral changes, food intake, the weight of rats, and hematological, biochemical variables and histopathological changes were examined. **Results:** Physical and behavioral changes were not observed in acute and sub-chronic toxicity conditions. Food intake significantly differed between male and female DMSO control and other groups. In biochemical variables study, only SGOT (AST) showed a significant difference from the control group (DMSO) in acute toxicity and BUN, ALP and SGOT (AST) in sub-chronic toxicity. Also, any histopathological change was observed in spleen, liver, and kidney organs. **Conclusion:** Oleo-gum resin of *F. assa-foetida* has not toxic effects, so it should be used with caution in the long term.

Abbreviations: F: *Ferula*, LD: Lethal Dose, GST: Glutathione S-Transferases, DMSO: Dimethylsulfoxide, GC: Gas Chromatography, MS: Mass Spectroscopy, Na: Sodium, K: Potassium, SGOT (AST): Aspartate aminotransferase, SGPT (ALT): Alanine aminotransferase, ALP: Alkaline Phosphatase, EDTA: Ethylenediaminetetraacetic acid, BUN: Blood Urea Nitrogen, Hb: Hemoglobin, HCT: Hematocrit, PT: Prothrombin Time, WBC: White Blood Cell, RBC: Red Blood Cell, FBS: Fasting Blood Sugar, Ca: Calcium, TBIL: Total Bilirubin, Alb: Albumin

*Corresponding author: goodarzi_s@sina.tums.ac.ir

doi: [10.61186/jmp.22.88.23](https://doi.org/10.61186/jmp.22.88.23)

Received 9 January 2024; Received in revised form 5 May 2024; Accepted 8 May 2024

© 2023. Open access. This article is distributed under the terms of the Creative Commons Attribution-NonCommercial 4.0 International License (<https://creativecommons.org/licenses/by-nc/4.0/>)

1. Introduction

One of the essential and extensive families with food and medicinal uses, of which many genera and species are found in different parts of Iran, is the Apiaceae family (Umbelliferae). The Apiaceae family is one of the most prominent families of herbaceous plants. The extracts and essential oils of plants of this family are rich in extensive chemical compounds. They have numerous genera that have had high medicinal and economic value in the past. This family has about 34 genera and 344 species [1, 2].

One of genus in this family that have most important and widely used, is the genus *Ferula* (Apiaceae), which has more than 154 species and it is native to Central Asia. Among the species of this plant, 53 species are grown in Iran and they are used as food as well as traditional medicine [3, 4]. *Ferula assa-foetida* L., *F. gummosa* Boiss. and *F. persica* Willd are most famous species among the native species of *Ferula* from Iran. The origin of *Ferula* is the steppe ecozone of Iran and parts of Afghanistan [5, 6]. This plant grows in the barren areas of dry sand containing calcareous compounds in hot regions at altitude of 1900-2400 meters above sea level and in areas with high altitude and lowlands on slopes of 15-70 % with rainfall of about 250-350 ml. The soil of *Ferula* habitats is usually shallow and eroded. This plant turns green in the middle of March and tolerates low temperatures and soil salinity [5, 7, 8].

Ferula genus was demonstrated several protective effects in previous studies such as antioxidant, anti-inflammatory, immunomodulatory [9], neuroprotectivity [10], and hepatoprotectivity [11].

Also, the oleo-gum resin of this plant was demonstrated various effects in medicine especially traditional medicine. The ole-gum resin of *Ferula* was effective on gastrointestinal

disorders, nervous disorders, respiratory disorders, and etc. [12].

Despite several studies on effectiveness of different species of *Ferula*, there is lack of information about toxicity of oleo-gum resin of these plants.

Different species of rats or laboratory mice are usually used, which are economical. The changes between animals are less in them, but they are more similar to humans [13].

The simplest method to determine the approximate lethal dose is to use six animals. Each animal receives an amount of the substance whose concentration is 50% higher than the concentration prescribed in the previous animal. With such an interval in doses, the animal receiving the higher dose and the smallest lethal dose that may be close to the concentration that 50% of population was died (LD₅₀) can be determined. This method is repeated for high and low doses, and in this way, the highest tolerable dose and the lowest lethal dose are determined. A newer method for the acute toxicity test is the Fixed Dose method. In this method, the animal's death is not used as the endpoint, and substances are classified based on toxicity effects. The selected dose range is the fixed doses of 5, 50, 500, and 2000 mg/kg. This method requires fewer animals and allows the classification of substances. This test is performed on young and adult animals, and if one gender is used, the female is used because the female show signs of toxicity better and more than the male [14]. Sub-chronic toxicity tests are performed when no toxicity is observed during the acute toxicity studies. A substance is used more often than a critical period, which is why it is necessary to conduct a long-term test such as chronic or sub-chronic tests to check for non-fatal, non-acute side effects. In these types of tests, toxicity takes time to appear. The responses observed in low-

dose, repeated-dose toxicity studies differ significantly from those in acute and high-dose studies. Sub-chronic tests give information about the target tissues and the organ in which the chemical is accumulated. Due to work problems, it is sometimes impossible to conduct chronic tests, so sub-chronic tests are designed [15]. Sub-chronic studies include: evaluation of the side effects of a substance that may occur during repeated daily doses. Studies should not take more than 10-15% of the animal's lifetime. Therefore, the study is considered within 30-90 days in rats and equivalent to the same period in humans [15].

2. Materials and methods

2.1. Plant collection and identification

The oleo-gum resin of *F. assa-foetida* L. was collected from Dasht-e-Lar region Fars province, Iran and voucher specimen with herbarium code PMP-1816 was registered in herbarium of Faculty of Pharmacy of Tehran University of Medical Sciences.

2.2. Extraction and Fractionation

About 200 grams of *Ferula* were weighed with a scale (Feller, Germany) and transferred into a round bottom flask and 2 L of ethanol 80% was added. By magnetic stirrer heater mantle, the extraction process was performed at 40-50 °C and 150 rpm for 3 hrs. After the end of extraction process, the total extract was filtered and dried by rotary evaporator. To eliminate residual solvent, total extract was kept under laboratory fume hood until to dry.

For fractionation process, the total extract was dispersed in water and 500 ml of chloroform solvent was added to them in separatory funnel. This process was repeated for 5 times and lower layer was separated as chloroform fraction. After filtering chloroform fraction, it was concentrated

by rotary evaporator and concentrated chloroform fraction was refrigerated.

2.3. Acute Toxicity Investigation

Thirty two male and female Wistar rats with an average age of 6-8 weeks (16 males and 16 females) with 180 g were prepared from animal house of the Faculty of Pharmacy, Tehran University of Medical Sciences, Tehran, Iran. The rats were kept in special cages and all ethics considerations were follows. The number of rats in total extract groups (50 mg/kg, 500 mg/kg, 2000 mg/kg) was four males and four females for each dose and four males and four females for DMSO 0.8 % control group. A single dose of these samples were given orally (gavage) on the first day of the study. During ten days of the study, the mortality rate in rats was investigated and behaviors of rats, such as teeth grinding and possible changes in the appearance of their body, such as reddening of skin lips, and etc. were followed. The daily amount of water and food consumed were measured [16, 17]. Also, the weight of rats was measured by digital scale (Feller, Germany) on the last day. After sacrificing the rats, blood sample was taken from heart and biochemical tests including Na⁺ and K⁺ ions and liver enzymes, including SGOT (AST), SGPT (ALT), and Alkaline phosphatase was performed and analyzed.

2.4. Sub-chronic toxicity investigation

Twenty six male and female Wistar rats (13 males and 13 females) with an average age of 6-8 weeks with 180 g were prepared from the animal house of faculty of Pharmacy of Tehran University of Medical Sciences, Tehran, Iran. The rats were kept in special cages and all ethics considerations were follows based on previous studies on toxicity of *Ferula* species, doses of 50 and 250 mg/kg were determined. Sample groups

(50 and 250 mg/kg), weight control group, and DMSO (0.8 %) control group included four, four, three, and two males and females rat, respectively and food was given daily. Male and female weight control groups did not receive the same substances and only consumed water and food, and the amount of water and food consumed, and their weight was measured. The behavior of the rat, such as teeth grinding, possible changes in the rat's body, such as reddening of the skin, reddening of the lips, and etc., were investigated and followed up during a month of study.

The weight of rats was measured on the designated days (3rd, 7th, 14th, 21st, 28th, and 30th). At the end of study, rats were anesthetized by ether, ketamine, and xylazine, and blood sample was taken from their hearts. The blood samples were transferred into test tubes with EDTA and normal and hematological tests were performed. The biochemical tests were analyzed at the pathobiology and genetics laboratory [16, 18, 19, 20, 21].

The organs were separated from rats and they were poured with 10 % formalin and were refrigerated for histopathology tests.

2.5. Statistical Analyses

Achieved data were analyzed with one-way ANOVA and two-way ANOVA tests with $P < 0.05$ and for statistical comparison between groups, post-hoc Tukey's was performed.

3. Results

3.1. Acute toxicity

3.1.1. Evaluation of water and food consumption

The evaluation of amount of water consumed in 6 days were analyzed by two-way ANOVA test ($P < 0.05$) in figure 1.

Also, amount of food consumed in 6 days were analyzed by two-way ANOVA test ($P < 0.05$) in figure 2.

3.1.2. Investigation of weight changes

The initial weight for each rat was considered to be 180 g and rats were re-weighted on the final day was shown in the table 1.

3.1.3. Evaluation of biochemical factor changes

The investigation of biochemical factors after the ten days of acute toxicity study were summarized in table 2.

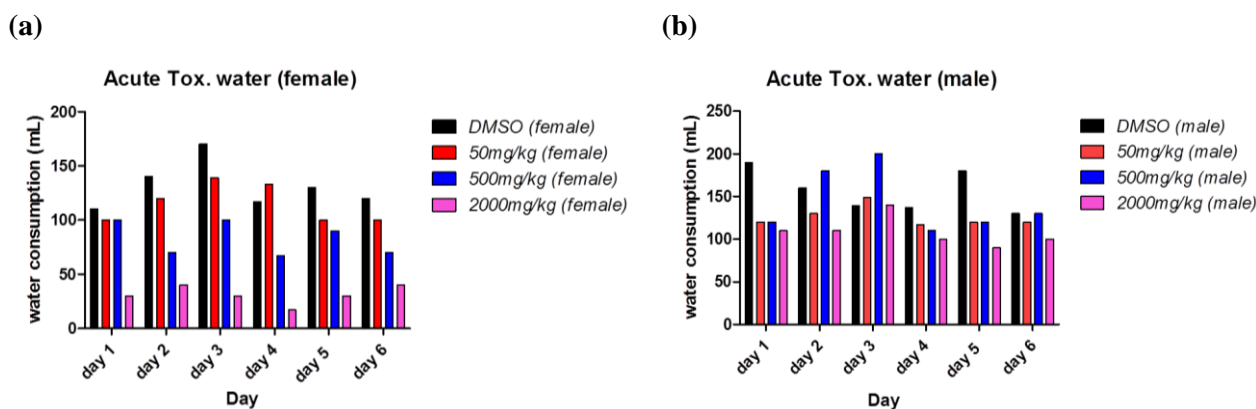


Fig. 1. The consumed amount of water of *F. assa-foetida* L. (a) the amount of consumed water by different groups in the female rats during six days. (b) The amount of water consumed by different groups in males during six days.

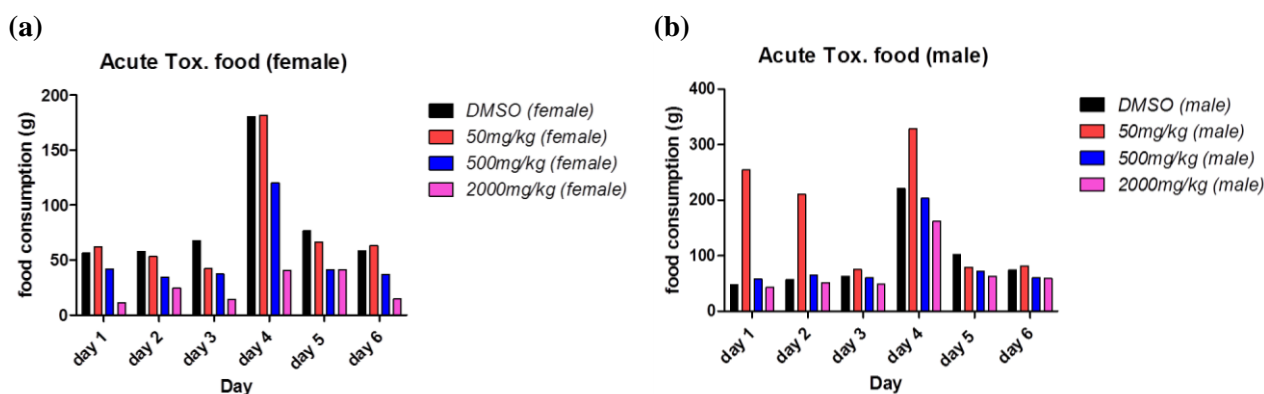


Fig. 2. The amount of consumed food of *F. assa-foetida* L. (a) the amount of consumed food by different groups in the female rats during six days. (b) The amount of water consumed by different groups in males during six days.

Table 1. The weight changes of rats on the sixth day in the acute toxicity of *F. assa-foetida* L.

Rat	Female DMSO (Control)	Male DMSO (Control)	Female 2000 mg/kg	Male 2000 mg/kg	Female 500 mg/kg	Male 500 mg/kg	Female 50 mg/kg	Male 50 mg/kg
No. 1	11	11	14	49	16	32	36	28
No. 2	15	18	-	16	27	30	30	32
No. 3	21	14	-	19	-	28	18	31
No. 4	16	13	-	-	-	41	19	35
Average	15.75	14	14	28	21.5	32.75	25.75	31.5

Table 2. The results of the biochemical factors after the study of acute toxicity of *F. assa-foetida* L.

	Male rats				Female rats			
	(DMSO)	(50 mg /kg)	(500 mg/kg)	(2000 mg/kg)	(DMSO)	(50 mg/kg)	(500 mg/kg)	(2000 mg/kg)
Na ⁺ (mmol/L)	143 ± 1.4	140.5 ± 0.7	142.5 ± 2.1	144.5 ± 0.7	143.5 ± 0.7	145 ± 2.8	143.0 ± 0.0	145.0 ± 0.0
K ⁺ (mEq/L)	5 ± 0.8	5.9 ± 0.3	4.65 ± 0.2	5.45 ± 0.3	4.7 ± 0.6	6.8 ± 1.6	5.5 ± 0.1	6.1 ± 0.0
SGOT (IU/L)	136.5 ± 14.8	218.5 ± 46.0	123.5 ± 13.4	206.5 ± 44.5	119.5 ± 12.0	267 ± 26.9**	196.0 ± 11.3	234.0 ± 0.0*
SGPT (IU/L)	40.5 ± 0.7	48.5 ± 0.7	41 ± 8.5	41.5 ± 3.5	48.0 ± 2.8	41.5 ± 2.1	52.5 ± 10.6	46.0 ± 0.0
ALP (IU/L)	800 ± 226.3	935.0 ± 82.0	612.5 ± 289.2	698 ± 56.6	1037.5 ± 323.1	702.5 ± 88.4	827.0 ± 193.7	536.0 ± 0.0

*significant difference with DMSO control group in female.

The results of acute toxicity tests were demonstrated any changes in all biochemical parameters in all groups with control group except SGOT in female groups (50, 2000 mg/kg).

3.2. Sub-chronic toxicity

3.2.1. Evaluation of water and food consumption

The evaluation of amount of water consumed in 30 days were analyzed by two-way ANOVA test ($P < 0.05$) in figure 3.

Also, amount of food consumed in 14 days were analyzed by two-way ANOVA test ($P < 0.05$) in figure 4.

3.2.2. Investigation of the weight change

The weight of rats was measured on the 0, 3, 7, 14, 21, 28, and 31 days after starting of the study. The weight change profile was shown in figure 5 and data were analyzed by a two-way ANOVA test ($P < 0.05$).

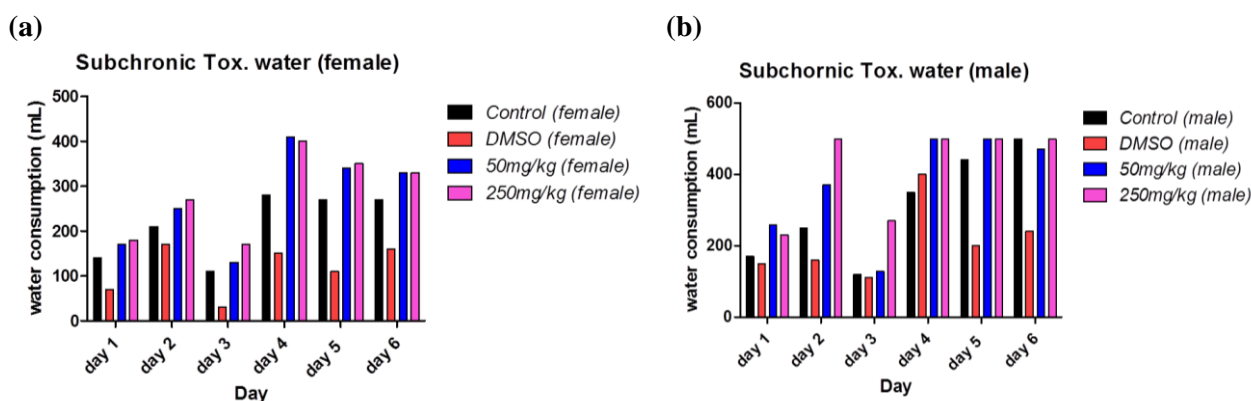


Fig. 3. The consumed amount of water of *F. assa-foetida* L. (a) the amount of consumed water by different groups in the female rats during 30 days. (b) The amount of water consumed by different groups in males during 30 days. * A significant difference between DMSO control group and other groups in several days.

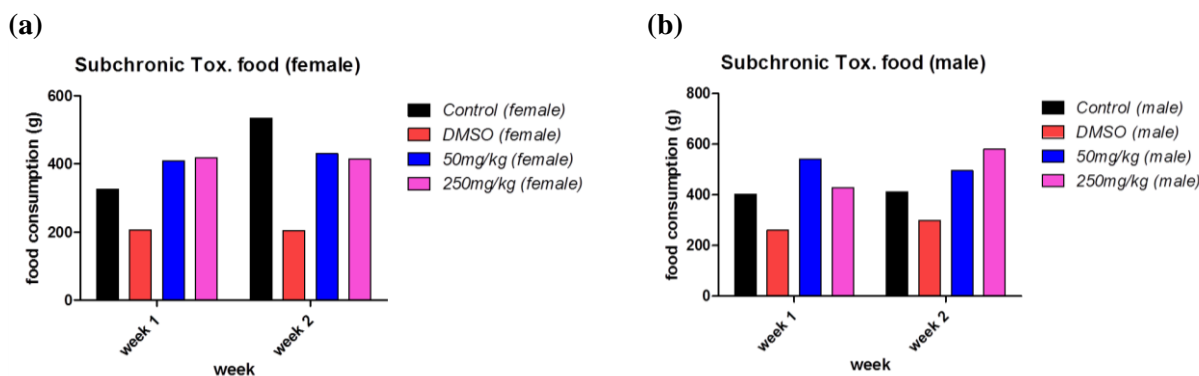


Fig. 4. The amount of consumed food of *F. assa-foetida* L. (a) the amount of consumed food by different groups in the female rats during 14 days. (b) The amount of water consumed by different groups in males during 14 days. * A significant difference between DMSO control group and other groups in several days.

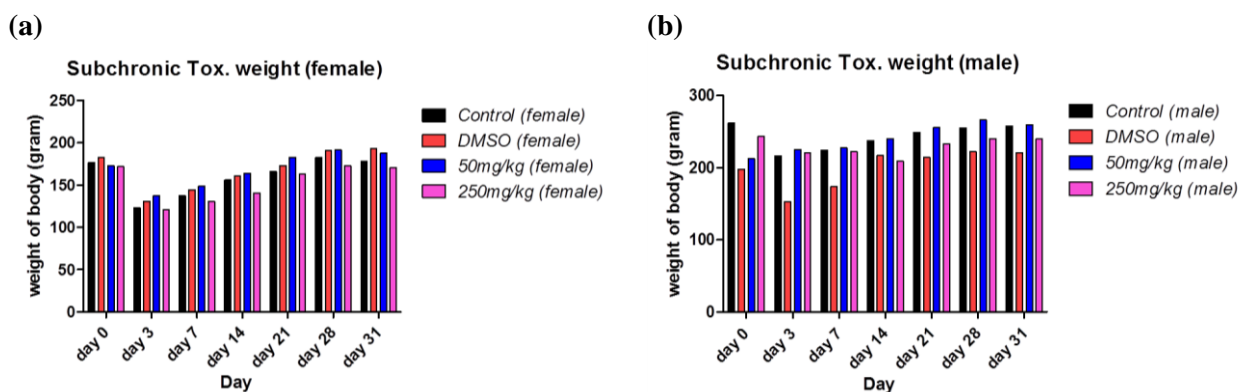


Fig. 5. Effect of *F. assa-foetida* L. on weight change of rats. (a) The weight of female rats on specific days during 30 days of sub-chronic toxicity study, (b) The weight of male rats on specific days during 30 days of sub-chronic toxicity study

3.3. Evaluation of biochemical factor changes

3.3.1. Investigation of hematological factors changes

The hematological factors of animals were evaluated after 30 days of the sub-chronic toxicity study (Table 3).

3.3.2. Evaluation of biochemical factors changes

The changes in biochemical factors during the 30 days in sub-chronic toxicity study are summarized in Table 4.

Table 3. Hematological factors of rats after 30 days of sub-chronic toxicity study of *F. assa-foetida* L.

	Male rats				Female rats			
	(Control)	(DMSO)	(50 mg/kg)	(250 mg/kg)	(Control)	(DMSO)	(50 mg/kg)	(250 mg/kg)
WBC	13.7±2.5	13.2±1.2	12.7±3.2	12.1±1.9	12.3±1.3	14.1±2.6	13.2±0.8	14.9±1.6
RBC	9.5±0.3	9.6±0.1	9.4±0.2	9.6±0.2	8.1±0.5	8.2±0.7	8.5±0.4	8.4±0.1
Hb (g/dL)	15.3±0.2	14.8±0.3	15.8±0.8	15.5±0.5	15.5±1.4	15.3±0.6	15.9±0.4	15.4±0.2
HCT	49.2±0.5	46.6±1.2	50.7±3.9	49.2±2.2	49.2±3.8	49.4±1.70	50.9±1.5	49.6±0.7
PT	739.3±149.8	602.0±143.2	794.7±113.7	821.6±54.6	720.0±55.7	833.0±152.7	824.7±63.1	664.3±212.4

Table 4. The results of the biochemical factors changes after the study of sub-chronic toxicity of *F. assa-foetida* L.

	Male rats				Female rats			
	(Control)	(DMSO)	(50 mg/kg)	(250 mg/kg)	(Control)	(DMSO)	(50 mg/kg)	(250 mg/kg)
FBS (mg/dL)	106.3±13.3	74.0±21.7	79.0±27.5	79.6±11.1	90.7±21.7	60.5±4.9	82.7±38.6	77.3±7.6
BUN (mg/dL)	43.0±5.2	41.0±6.3	44.7±2.5	44.0±11.3	58.0±3.6	36.5±4.9*	41.0±2.6*	43.3±6.1
Creatinine (mg/dL)	0.5±0.2	0.4±0.0	0.4±0.1	0.4±0.0	0.4±0.0	0.4±0.0	0.4±0.0	0.4±0.0
Cholesterol (mg/dL)	65.0±7.6	53.0±5.9	58.7±2.3	67.3±13.6	71.0±10.4	79.5±17.7	70.7±10.6	78.0±6.1
Triglycerides (mg/dL)	37.3±18.3	52.0±14.1	82.3±32.2	66.0±11.4	56.7±11.5	88.5±6.4	84.0±26.2	59.0±6.1
Ca²⁺ (mg/dL)	8.3±3.7	9.4±0.1	10.4±0.9	9.8±0.6	10.2±0.2	9.7±0.1	10.5±0.5	10.5±0.2
Na⁺ (mmol/L)	145.0±1.0	142.0±1.3	141.7±2.5	142.3±0.6	143.7±0.6	143.5±0.7	143.3±1.5	142.7±1.5
K⁺ (mEq/L)	6.3±2.8	4.6±0.2	4.8±0.4	5.4±0.4	5.3±0.4	4.3±0.3	5.1±0.2	4.9±0.2
TBIL (mg/dL)	0.07±0.0	0.08±0.0	0.06±0.0	0.06±0.0	0.07±0.0	0.08±0.0	0.06±0.0	0.05±0.0
Bilirun (mg/dL)	0.03±0.0	0.04±0.0	0.03±0.0	0.03±0.0	0.03±0.0	0.04±0.0	0.03±0.0	0.04±0.0
SGOT (AST) (IU/L)	140.6±24.8	121.0±17.8	167.0±10.5	163.0±21.1	205.0±5.2	154.0±18.4	141.0±22.3**	130.0±13.1**
SGPT (ALT) (IU/L)	45.3±6.0	32.0±4.2	40.0±19.0	48.0±2.0	58.0±19.9	31.5±12.0	31.3±8.7	32.3±8.6
ALP (IU/L)	291.0±82.9	494.0±64.7*	438.3±98.6	403.33±44.0	235.0±14.0	230.0±0.0	266.3±34.5	163.7±27.8
Alb (g/dL)	3.5±0.2	3.1±0.1	3.2±0.3	3.1±0.4	4.2±0.5	4.1±0.5	3.8±0.1	3.9±0.1

*significant difference with each DMSO control group.

The amount of blood urea (50 mg/kg), the level of aspartate aminotransferase enzyme (50, and 250 mg/kg) in female group, and level of

alkaline phosphatase enzyme in male group were demonstrated significant difference with their DMSO control groups.

3.3.3. The ratio of organs to whole body weight

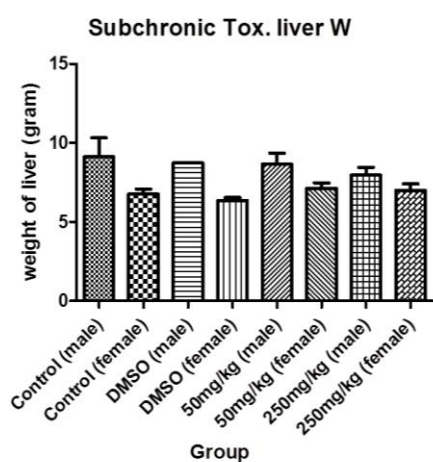
According to ethics consideration, the animals were sacrificed on the last day of study and liver, kidney, and spleen were removed, weight of them was measured, and the ratio of organ weight to body weight was calculated. The results were demonstrated in figure 6.

3.4. Mortality rate

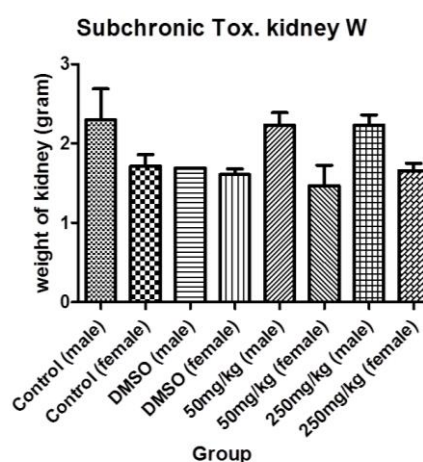
The mortality rate of animals in acute toxicity test was 60% in ten days. Four animals in 2000 mg/kg group and two rats were died in 1000 mg/kg group. Also, no death was observed in 500 mg/kg group and the calculated LD50 was 2000 mg/kg.

During sub chronic toxicity test in 30 days, death was not observed at any administered doses (50 mg/kg and 250 mg/kg).

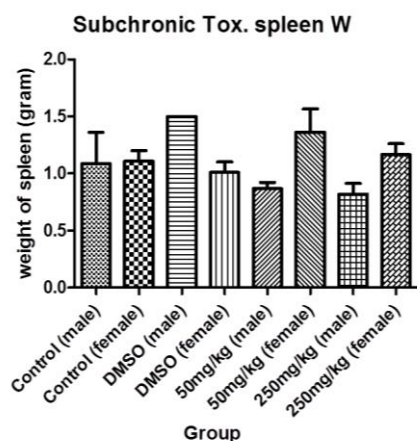
(a)



(b)



(c)



(d)

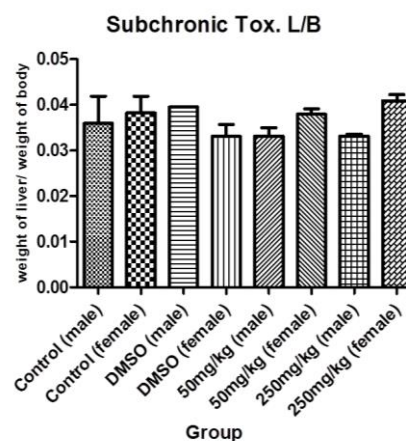


Figure 6. The weight variation of organs in sub-chronic toxicity of *F. assa-foetida* L. oleo-gum resin study. (a) The weight of liver, (b) The weight of kidney, (c) The weight of spleen, (d) The ratio of liver to body weight,

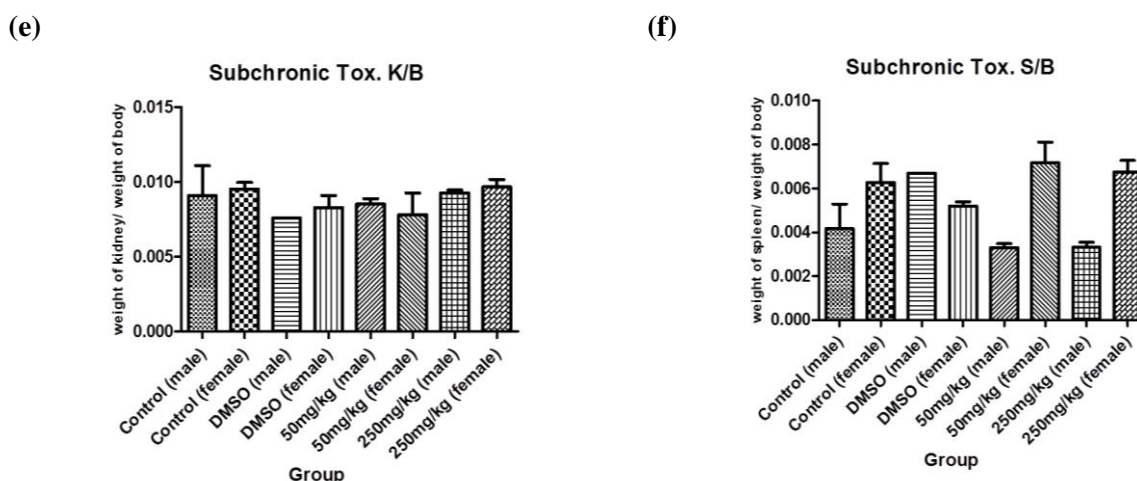


Figure 6. The weight variation of organs in sub-chronic toxicity of *F. assa-foetida* L. oleo-gum resin study. (e) The ratio of kidney to body weight, and (f) The ratio of spleen to body weight.

3.5. Histopathological changes investigation in sub-chronic toxicity study

3.5.1. Liver

The cross-sectional images of liver tissue were shown hepatocytes are indistinct with mild focal feather-like degeneration. There is no sign of converging or focal fibrosis or necrosis (Figure 7).

3.5.2. Kidney

The cross-sectional images of kidney tissue were demonstrated both medulla and cortical parts. Indistinct glomeruli and tubules are present in the cortical and medulla parts. The interstitium and kidney capsule does not show specific pathological changes (Figure 8).

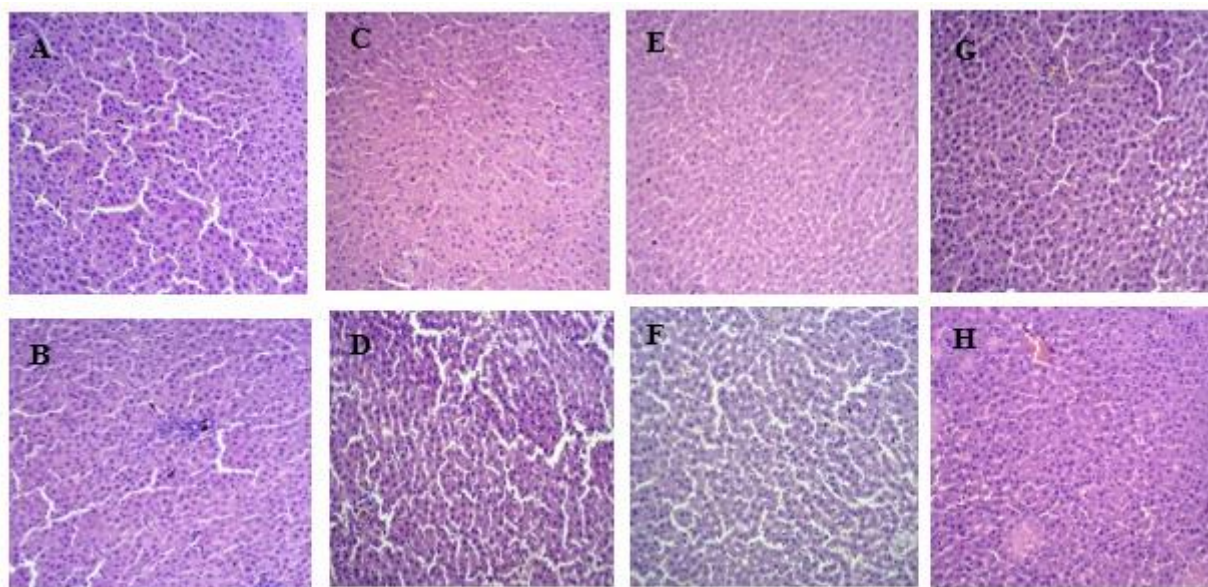


Fig. 7. Histological determinations of Liver in DMSO (A-Male, B- Female), control (C-Male, D- Female), chloroform fraction of oleo-gum resin of *F. assa-foetida* L. (50 mg/kg) [E -Male, F-Female], chloroform fraction of oleo-gum resin of *F. assa-foetida* L. (250 mg/kg) [G -Male, H-Female] Hematoxylin and eosin (H&E) stain (100 μm).

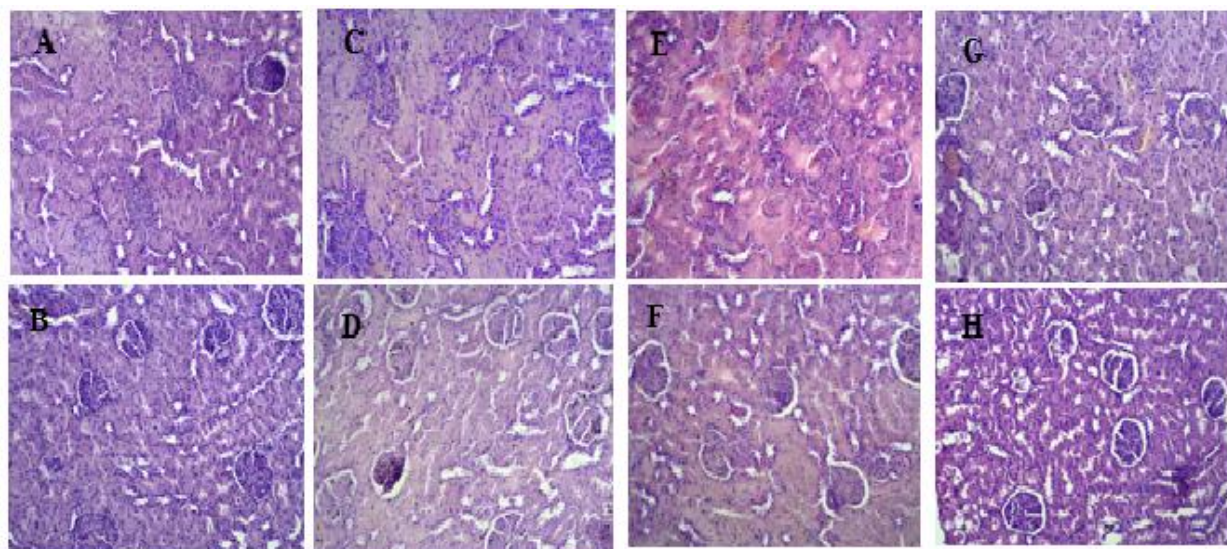


Fig. 8. Histological determinations of Kidney in DMSO (A-Male, B- Female), control (C-Male, D- Female), chloroform fraction of oleo-gum resin of *F. assa-foetida* L. (50 mg/kg) [E -Male, F-Female], chloroform fraction of oleo-gum resin of *F. assa-foetida* L. (250 mg/kg) [G -Male, H-Female]. Hematoxylin and eosin (H&E) stain (100 μ m).

3.5.3. Spleen

Also, the cross-sectional images of spleen tissue were shown a healthy structure, which

includes white and red pulps. The sinusoidal structures are also open, and the splenic capsule is healthy (Figure 9).

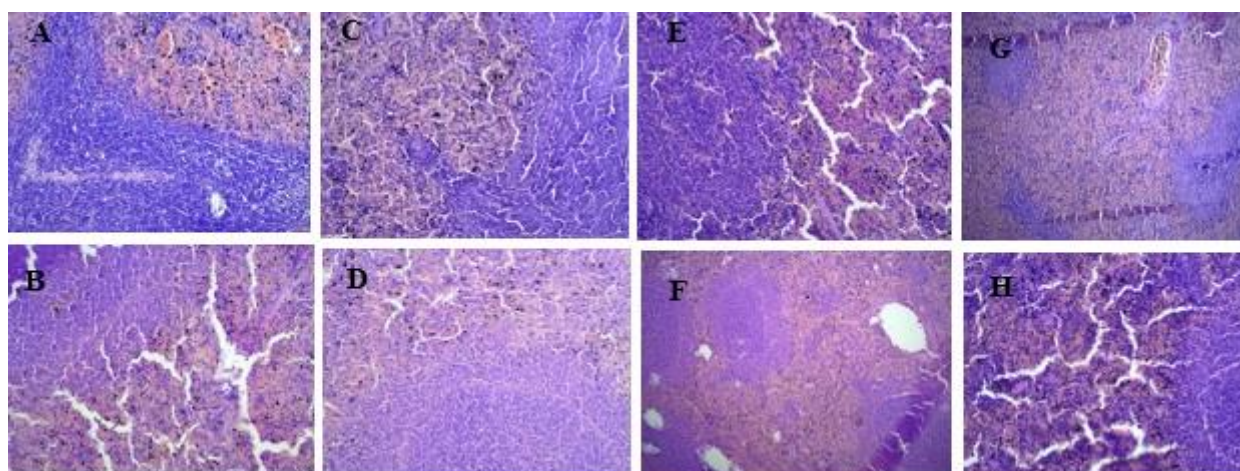


Fig. 9. Histological determinations of Spleen in DMSO (A-Male, B- Female), control (C-Male, D- Female), chloroform fraction of oleo-gum resin of *F. assa-foetida* L. (50 mg/kg) [E -Male, F-Female], chloroform fraction of oleo-gum resin of *F. assa-foetida* L. (250 mg/kg) [G -Male, H-Female]. Hematoxylin and eosin (H&E) stain (100 μ m).

4. Discussion

Analyzing the results in acute toxicity study were shown that the number of deaths (6 rats) in the dose of 500 mg/kg, two rats from the female group and 2000 mg/kg, one rat from the male

group, and three rats from the gender group was female, and $LD_{50} = 2000$ mg/kg was calculated. A significant difference was observed in water consumption between the female DMSO control group and other female gender groups. Only a

significant difference was seen in food consumption between the male DMSO control group and other male gender groups. In biochemical study, the SGOT (AST) in chloroform fraction in female group was shown significant difference with control group that received DMSO. Therefore, consuming the chloroform fraction of oleo-gum resin extract of *F. assa-foetida* in male rats has toxic effects, but acute toxicity is not seen. Examining the results in the study of sub-chronic toxicity were shown no significant changes and differences in the appearance of behavior, the amount of water and food consumed, the weight of rats, and hematological variables between the groups receiving the chloroform fraction and control groups.

Furthermore, DMSO control was not established, only in the case of biochemical variables. In three variables, BUN, SGOT, and ALP, a significant difference can be seen between the groups receiving the chloroform fraction of the extract and the weight control and DMSO control groups. There is no significant difference in the weight of the organs and the ratio of the weight of the organs to the body weight between the groups receiving the extract fraction and the control. In histopathological examinations, significant and noticeable changes are not observed between the groups receiving the chloroform fraction of the extract and the control. Meanwhile, totally there are no significant differences between male and female groups in biochemical and histopathological results. So, it was seen that the consumption of

chloroform fraction with doses of 50 mg/kg and 250 mg/kg for 30 days does not cause toxic effects in male and female rats and is considered safe.

5. Conclusion

F. assa-foetida is one of the important strategic plants of Iran, which has not found proper clinical and commercial value due to incomplete biochemical and pharmacognostic studies. In this study, it was found that the chloroform fraction of this oleo-gum resin does not have acute and sub-chronic toxicity. Certainly, this important toxicological finding opens the way for clinical use and more research works on the products obtained from this plant.

Author contributions

MB, MPH, ZB, AJ and ZM searched for the articles, and wrote the first draft. ST and AH designed the study and contributed to the writing process and analysis. SG was the study supervisor, contributed to all aspect of the study, and provided the final manuscript. ZT and RMJ contributed to the study process. All authors read and approved the paper.

Conflicts of interest

The authors of this study hereby declare that they no conflicts of interest to disclose.

Acknowledgment

This research was supported by a grant of Tehran University of Medical Sciences, Tehran, Iran (No. 49165).

References

1. Evans WC. Trease and Evans Pharmacognosy: Edited by Trease and Evans. 13th ed. London : Bailliere Tindall; 2016.
2. Goodarzi S, Mofasseri M, Tofighi Z, Pirali Hamedani M, Hadjiakhoondi A, Tavakoli S, Moein Z and Baharipour Z. Remarkable variation in phytochemicals of *Ferula gummosa* Bioss. essential oils collected from different parts of Iran. *RJP*. 2022; 9(4): 29-38. doi: 10.22127/rjp.2022.345563.1917.

3. Soleimani Far M, Mojab F and Arbabi Bidgoli S. Acute and subchronic toxicity assessment of aerial parts of *Ferula persica* in female mice. *J. Med. Plants* 2019; 18(69): 47-58.
4. Iranshahi M, Mojarab M, Sadeghian H, Hanafi-Bojd MY and Schneider B. Polar secondary metabolites of *Ferula persica* roots. *Phytochem.* 2008; 69(2): 473-78. doi: 10.1016/j.phytochem.2007.08.001.
5. Ross IA. Medicinal plants of the world, volume 3: Chemical constituents, traditional and modern medicinal uses. Springer Science & Business Media; 2007.
6. Leaman DJ. Medicinal Plant Conservation, Newsletter of the Medicinal Plant Specialist Group of the IUCN Species Survival Commission: 2006.
7. Khosravi H and Mehrabi A. Economic study of *Ferula* harvesting in Tabass region. *Iran. J. Natur. Res.* 2006. 58(4): 933-943.
8. Zare AR, Omid M, Fallah Hoseini H, Yazdani D, Rezazadeh Sh, Irvani N and Oladzad A. A Review on Pharmacological Effects of *Ferula assa-foetida* L.:A Systematic Review. *J. Med. Plants.* 2011; 10(40): 17-25.
9. Ghasemi Z, Rezaee R, Aslani MR, Boskabady MH. Anti-inflammatory, anti-oxidant, and immunomodulatory activities of the genus *Ferula* and their constituents: A review. *Iran. J. Basic Med. Sci.* 202; 24(12): 1613-1623. doi: 10.22038/IJBMS.2021.59473.13204.
10. Topdas EF, Sengul M, Taghizadehghalehjoughi A and Hacimuftuoglu A. Neuroprotective potential and antioxidant activity of various solvent extracts and essential oil of *Ferula orientalis* L. *J. Essen. Oil Bearing Plants.* 2020; 23(1): 121-38. doi: 10.1080/0972060X.2020.1729247.
11. Deniz GY, Laloglu E, Koc K and Geyikoglu F. Hepatoprotective potential of *Ferula communis* extract for carbon tetrachloride induced hepatotoxicity and oxidative damage in rats. *Biotech. Histochem.* 2019; 94(5): 334-40. doi: 10.1080/10520295.2019.1566831.
12. Iranshahy M and Iranshahi M. Traditional uses, phytochemistry and pharmacology of asafoetida (*Ferula assa-foetida* oleo-gum-resin)-A review. *J. Ethnopharmacol.* 2011; 134(1): 1-10. doi: 10.1016/j.jep.2010.11.067.
13. Rasheed RA, Ali BH and Bashir AK. Effect of *Teucrium stocksianum* on paracetamol-induced hepatotoxicity in mice. *General Pharmacol.* 1995; 26(2): 297-301. doi: 10.1016/0306-3623(94)00208-5.
14. Ecobichon DJ. The Basis of Toxicity Testing. CRC press. 1997.
15. Pfaller W, Balls M, Clothier R, Coecke S, Dierickx P, Ekwall B, Hanley BA, Hartung T, Prieto P, Ryan MP, Schmuck G, Sladowski D, Vericat JA, Wendel A, Wolf A and Zimmer J. Novel advanced *in vitro* methods for long-term toxicity testing. *Alternatives to Laboratory Animals.* 2001; 29(4): 393-426. doi.org/10.1177/026119290102900407.
16. Tchoumtchoua J, Mouchili OR, Ateba S, Zingue S, Halabalaki M, Mbanya J, Skeltsounis A and Njamen S. Safety assessment of the methanol extract of the stem bark of amphimas pterocarpoides harms: Acute and subchronic oral toxicity studies in Wistar rats. *Toxicology Reports* 2014; 877-84. doi: 10.1016/j.toxrep.2014.10.003.
17. Procházková D, Boušová I and Wilhelmová N. Antioxidant and prooxidant properties of flavonoids. *Fitoterapia.* 2011; 82(4): 513-23. doi: 10.1016/j.fitote.2011.01.018.
18. Development, Organisation for Economic Co-operation and. Test No. 407: Repeated Dose 28-Day Oral Toxicity Study in Rodents. OECD Publishing: 2008.
19. Agyigra IA, Ejiofor JI and Magaji MG. Acute and subchronic toxicity evaluation of


methanol stem-Bark extract of *Ximenia americana* Linn (Olacaceae) in Wistar rats. *Bulletin of Faculty of Pharmacy, Cairo University*. 2017; 55(2): 263-67. doi: 10.1016/j.bfopcu.2017.08.004.

20. Lee, JS, Kim YH, Kim DB, Shin GH, Lee JH, Cho JH, Lee BY and Lee OH. Acute and subchronic (28 Days) oral toxicity studies of *Codonopsis lanceolata* extract in Sprague–Dawley rats. *Regul. Toxicol. Pharmacol.* 2015; 71(3): 491-97. doi: 10.1016/j.yrtph.2015.02.014.

21. Atsamo AD, Nguelefack TB, Datté JY and Kamanyi A. Acute and subchronic oral toxicity assessment of the aqueous extract from the stem

bark of *Erythrina senegalensis* DC (Fabaceae) in rodents. *J. Ethnopharmacol.* 2011; 134(3): 697-702. doi: 10.1016/j.jep.2011.01.023.

How to cite this article: Tofighi Z, Mohammad Jafari R, Besati M, Pirali Hamedani M, Hadjiakhoondi A, Baharipour Z, Jariani A, Moiin Z, Tavakoli S, Goodarzi S. Evaluation acute and sub-chronic toxicity assessments of Oleo-gum Resin of *Ferula assa-foetida* L. in Wistar rats. *Journal of Medicinal Plants* 2023; 22(88): 23-35. doi: [10.61186/jmp.22.88.23](https://doi.org/10.61186/jmp.22.88.23)



فصلنامه گیاهان دارویی

Journal homepage: www.jmp.ir

مقاله تحقیقاتی

ارزیابی سمیت حاد و تحت مزمن اولئوگام رزین آنغوزه (*Ferula assa-foetida* L.) در موش صحرایی نژاد Wistar

زهرا توفیقی^{۱،۲}، راضیه محمد جعفری^۳، مسعود بساطی^۴، مصطفی پیرعلی همدانی^۲، عباس حاجی آخوندی^{۱،۲}، زهرا بهاری پور^۵، احمد جاریانی^۲، زهرا معین^۲، سعید توکلی^۶، سعید گودرزی^{۱*}

^۱ مرکز تحقیقات گیاهان دارویی، دانشکده داروسازی، دانشگاه علوم پزشکی تهران، تهران، ایران

^۲ گروه فارماکوتکنوزی، دانشکده داروسازی، دانشگاه علوم پزشکی تهران، تهران، ایران

^۳ مرکز تحقیقات طب تجربی، دانشگاه علوم پزشکی تهران، تهران، ایران

^۴ گروه شیمی دارویی، پژوهشکده گیاهان دارویی و مواد اولیه دارویی، دانشگاه شهید بهشتی، تهران، ایران

^۵ دانشکده داروسازی، پردیس بین‌الملل، دانشگاه علوم پزشکی تهران، تهران، ایران

^۶ مرکز تحقیقات گیاهان دارویی، پژوهشکده گیاهان دارویی جهاد دانشگاهی، کرج، ایران

چکیده

اطلاعات مقاله

مقدمه: گیاه آنغوزه (<i>Ferula assa-foetida</i>) گیاهی علفی از خانواده چتریان (Apiaceae) است. اثرات دارویی متعددی از اولئو رزین این گیاه در طب مدرن و سنتی مانند بهبود مشکلات گوارشی، اثرات ضد میکروبی، ضد دیابتی، اشتهاآور، حشره کش و ... معرفی شده است. هدف: این مطالعه با هدف بررسی سمیت حاد و تحت مزمن فراکشن کلروفومی عصاره اولئوگام رزین آنغوزه در موش صحرایی انجام شد. عدم بروز سمیت این فراکشن می‌تواند تضمین کننده استفاده از آن در درمان و صنایع مختلف از جمله صنایع دارویی باشد. روش بررسی: موش‌های صحرایی در شش گروه نر و ماده (به طور جداگانه) در دوزهای مختلف (۵۰، ۵۰۰ و ۲۰۰۰ میلی‌گرم بر کیلوگرم) و دو گروه کنترل (شاهد و DMSO) برای ارزیابی سمیت حاد انتخاب شدند. برای تست سمیت تحت مزمن به مدت ۳۰ روز دوزهای ۵۰ و ۲۵۰ میلی‌گرم بر کیلوگرم از فراکشن مذکور به موش‌های صحرایی نر و ماده داده شد. سپس تغییرات هیستوپاتولوژیک مورد بررسی قرار گرفت. نتایج: تغییرات فیزیکی و رفتاری در شرایط سمیت حاد و تحت مزمن مشاهده نشد. دریافت غذا بین جنس نر و ماده گروه شاهد و DMSO با سایر گروه‌ها تفاوت معناداری داشت. در مطالعه متغیرهای بیوشیمیایی، تنها SGOT (AST) تفاوت معناداری با گروه کنترل (DMSO) در سمیت حاد و BUN، ALP، و SGOT (AST) در سمیت تحت مزمن نشان داد. همچنین هرگونه تغییر هیستوپاتولوژیک در اندام‌های طحال، کبد و کلیه مشاهده نشد. نتیجه‌گیری: اولئوگام رزین گیاه آنغوزه دارای اثرات سمی نیست و در تست سمیت حاد و تحت مزمن اثرات سمی از خود بروز نداد اما با این حال باید در دراز مدت با احتیاط مصرف شود.	گل‌واژگان: آنغوزه سمیت حاد سمیت تحت مزمن صمغ
---	--

مخفف‌ها: F: فرولا؛ LD: دوز کشنده؛ GST: گلو تاتیون؛ DMSO: دی متیل سولفوکسید؛ GC: کروماتوگرافی گازی؛ MS: طیف سنجی جرمی؛ Na: سدیم؛ K: پتاسیم؛ SGOT (AST): آسپاراتات آمینوترانسفراز؛ SGPT (ALT): آلانین آمینوترانسفراز؛ ALP: آلکالین فسفاتاز؛ EDTA: اتیلن دی آمین تترا استیک اسید؛ BUN: اوره؛ Hb: هموگلوبین؛ HCT: هماتوکریت؛ PT: زمان انعقاد خون؛ WBC: گلبول سفید؛ RBC: گلبول قرمز؛ FBS: قند خون ناشتا؛ Ca: کلسیم؛ TBIL: بیلی روبین تام؛ Alb: آلبومین

* نویسنده مسؤول: goodarzi_s@sina.tums.ac.ir

تاریخ دریافت: ۱۹ دی ۱۴۰۲؛ تاریخ دریافت اصلاحات: ۱۶ اردیبهشت ۱۴۰۳؛ تاریخ پذیرش: ۱۹ اردیبهشت ۱۴۰۳

doi: [10.61186/jmp.22.88.23](https://doi.org/10.61186/jmp.22.88.23)

© 2023. Open access. This article is distributed under the terms of the Creative Commons Attribution-NonCommercial 4.0 International License (<https://creativecommons.org/licenses/by-nc/4.0/>)