




Institute of  
Medicinal Plants

## Journal of Medicinal Plants

Journal homepage: [www.jmp.ir](http://www.jmp.ir)



### Short Communication

## Scolicidal effects of the *Nicotiana tabacum* L. extract at various concentrations and exposure times

Roya Latifi<sup>1</sup>, Abbas Azadmehr<sup>2,3,\*</sup>, Sahar Mosalla<sup>1</sup>, Kiarash Saleki<sup>4,5</sup>, Reza Hajiaghache<sup>6</sup>

<sup>1</sup> Parasitology Department, Qazvin University of Medical Sciences, Qazvin, Iran

<sup>2</sup> Immunology Department, Babol University of Medical Sciences, Babol, Iran

<sup>3</sup> Immunology Department, Qazvin University of Medical Sciences, Qazvin, Iran

<sup>4</sup> Student Research Committee, Babol University of Medical Sciences, Babol, Iran

<sup>5</sup> USERN Office, Babol University of Medical Sciences, Babol, Iran

<sup>6</sup> Medicinal Plants Research Center, Institute of Medicinal Plants, ACECR, Karaj, Iran

### ARTICLE INFO

#### Keywords:

Herbal medicine

Tobacco

Hydatid cyst

Scolicidal treatment

Immunotoxicity

### ABSTRACT

**Background:** Tobacco is a plant that has anti-nematode and anti-inflammatory properties, due to that it contains compounds such as nicotine sulfate. It is utilized as a medicinal plant in the therapy of infectious diseases; also, it has been used to kill insects' larvae and plant pests. **Objective:** The goal of this work was the evaluation of tobacco extract effects on the scolices of hydatid cysts. **Methods:** Hydatid cysts of the infected sheep livers were gathered from the Qazvin abattoir and their protoscolices were isolated under sterile conditions. Fertility and viability of protoscolices were confirmed before the experiments. The protoscolices were exposed to the ethanolic extract of *Nicotiana tabacum*, at different concentrations (3, 5, 10, 25, 50, and 100 mg/ml) and various exposure times (10, 20, 30, 40, 50 and 60 min). Sodium chloride 0.9 % was selected as negative control. The viability of protoscolices was evaluated by staining via 0.1 % eosin. **Results:** At 100 mg/ml, the tobacco extract caused the death of 91.19 % of protoscolices after 10 minutes of contact, and other exposure times (20 to 60 minutes) resulted in the death of 100 % of protoscolices. **Conclusion:** This medicinal plant showed a good scolicidal effect and it may be used for improving the procedure of hydatid cyst surgery. But, further studies are required.

### 1. Introduction

Human echinococcosis (also called hydatidosis and hydatid disease) results from the larval phases of cestodes (tapeworms) of the genus *Echinococcus*. Hydatidosis is one of the most crucial zoonotic illnesses and is prevalent in

various regions of the globe. At present, surgery is the standard treatment for hydatid disorder [1-3]. One of the most notable risks of hydatid cyst surgery is the leakage of cyst contents and relapsing [4].

**Abbreviations:** ANOVA, Analysis of Variance; mg, Milligram; ml, Milliliter

\*Corresponding author: [a.azadmehr@mubabol.ac.ir](mailto:a.azadmehr@mubabol.ac.ir)

doi: 10.52547/jmp.21.82.111

Received 4 April 2022; Received in revised form 14 May 2022; Accepted 24 May 2022

© 2020. Open access. This article is distributed under the terms of the Creative Commons Attribution-NonCommercial 4.0 International License (<https://creativecommons.org/licenses/by-nc/4.0/>)

Discovery of efficient and safe scolicidal candidates and administration of them into cysts can attenuate the dissemination risk of viable protoscolices. Different scolicidal candidates have been utilized for deactivation of the cyst ingredients, however, most produce adverse side effects [1, 5, 6]. Formalin, hydrogen peroxide, setrimide, pure alcohol, hypertonic saline, and silver nitrate have been utilized as protoscolicidal substances, however, their adverse effects have limited the applicability of these substances [5, 6]. Currently, the use of natural medications including *Allium sativum* L., *Zataria multiflora* Boiss., *Trachyspermum ammi* (L.) Sprague, *Zingiber officinale* Roscoe, *Coriandrum sativum* L., *Mentha pulegium* L., *Satureja khuzestanica* Jamzad, *Ziziphora Tenuior* L. extracts and *Olea europaea* L. have been considered as alternatives to the mentioned synthetic substances. Nonetheless, to ensure that they are harmless to the human, more research is needed [6-13].

Some herbals can provide immunomodulatory and anti-inflammatory effects and are therefore useful for treatment of a wide array of diseases [14-17]. Inflammation is the basis for many diseases, and reducing the inflammation while killing pathogens may provide an optimal approach [18, 19]. Tobacco extract can exert anti-worm, anti-inflammatory, anti-insect, and anti-fungal effects, mainly because of its chemical ingredients, such as resin, gum, potassium salts, various organic acids, and nicotine sulfate. In the present study, it was tested as a protoscolicidal substance [17, 20-25].

## 2. Materials and Methods

### 2.1. Preparation of *Nicotiana tabacum* L. plant extract and hydatid cyst samples

*Nicotiana tabacum* L. plant was purchased from a medicinal plants shop and its authenticity was confirmed by a botanist. A small sample of

this plant was kept in the Institute of Medicinal Plants Herbarium with the herbarium code: 001 (IMPHM). Different parts of the dried plant including leaves, stems, and branches were crushed by a milling machine. In short, to prepare the plant extract, after drying and grinding them (half a kilogram), it was first extracted by ethanol and percolator. This process was repeated three times and then the resulting extracts were concentrated by vacuum distillation. The amount of dried extract was calculated; then, it was stored in a sealed plate in the refrigerator at 4 °C until the experiment.

The liver containing hydatid cysts was prepared from Qazvin abattoir, transferred to the parasitology department, and the contents of the cysts were suctioned in sterile settings and poured into sterile tubes separately. Calcified and purulent cysts were eliminated from this study. After disinfecting the surface of the cysts with betadine, the contents of the cysts were drained through 5 or 10 ml syringes and transferred into sterile test tubes. Cysts were examined for fertility by light microscopy. In the case of cyst fertility, the viability of protoscolices was evaluated through staining by 0.1 % eosin and movement assessment of candle flame cells. Cysts with a viability of more than 90 % were used for testing. [26, 27].

### 2.2. Evaluation of the protoscolicidal influence of plant extract

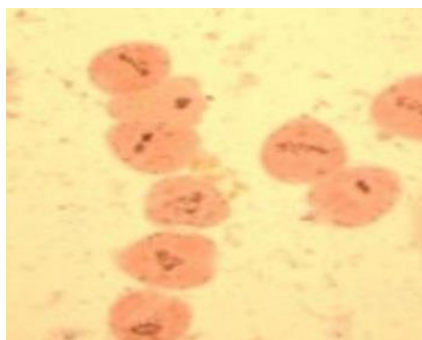
In this study, 6 concentrations of tested plant extracts (3, 5, 10, 25, 50 and 100 mg/ml) were exposed to protoscolices for 10, 20, 30, 40, 50 and 60 minutes. To prepare the mentioned concentrations, 30, 50, 100, 250, 500, and 1000 mg of plant extract were mixed with about 9 ml of normal saline in separate tubes and to facilitate the dissolution of the plant extract in normal saline, 0.3 ml of DMSO was transferred

to each tube and the tubes were stirred with a magnet, and finally the volume of the mixture with normal saline reached 10 ml. 2.5 ml of the mixture was poured into each test tube, and 100 µl of the samples was added that contained about 1000 protoscolices. The ingredients of the tubes were incubated for 10, 20, 30, 40, 50 and 60 minutes at 37 °C. After the incubation period, we removed the superior part of the tubes.

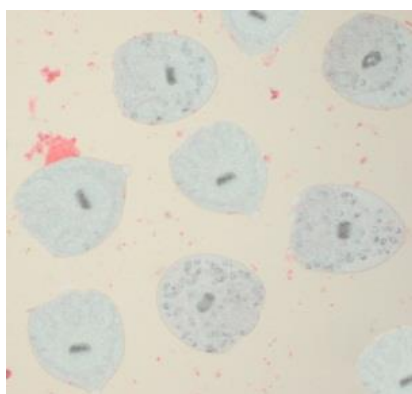
1 ml of 0.1 % eosin was transferred into the precipitate obtained in each tube and mixed well. After 15 minutes of incubation, the surface was removed and the remaining sediment was layed on a slide and evaluated under a light

microscope. By counting about 700 protoscolices, stained (dead) and unstained (live) protoscolices, percentage of dead protoscolices was determined. The control group (without plant extract) was used to ensure the accuracy of the experiments. The experiments were repeated three times [6, 12, 28, 29]. Examples of dead and live protoscolices are provided in Fig. 1 and 2, respectively.

Data were entered into the computer using Statistical Packages for Social Sciences (SPSS), (SPSS Inc., Chicago, USA) and the results were analyzed using one-way analysis of variance (ANOVA).



**Fig. 1.** Dead protoscolices after exposure to plant extract



**Fig. 2.** Live protoscolices before exposure to plant extract

### 3. Results

Tobacco extract had little effect on protoscolices at all administered concentrations except for 100 mg/ml at all exposure times. At a concentration of 100 mg/ml, tobacco extract led

to the death of 91.19 % of protoscolices following 10 minutes of contact. Moreover, longer exposure times (20 to 60 minutes) resulted in the elimination of 100 % of protoscolices (Table 1).

**Table 1.** Protoscolicidal effects of various concentrations of *Nicotiana tabacum* L. extract in different exposure times

Concentrations		% Mean of mortality rates (dead/total) after exposure					
(mg/ml)	Experiments	10 (min)	20 (min)	30 (min)	40 (min)	50 (min)	60 (min)
3	1	8.02 (56/698)	8.31 (74/890)	8.98 (69/768)	11 (90/818)	10.47 (90/860)	11.84 (114/963)
	2	8.61 (72/836)	8.63 (66/765)	9.40 (82/872)	11.76 (108/918)	12.40 (122/984)	12.00 (90/750)
	3	5.49 (40/728)	5.73 (45/786)	7.86 (72/916)	9.44 (85/900)	11.00 (93/836)	10.53 (96/912)
	Total	7.43 (168/2262)	7.58 (185/2441)	8.72 (223/2556)	10.74 (283/2636)	11.34 (304/2680)	11.43 (300/2625)
5	1	8.79 (53/603)	11.36 (108/951)	11.54 (78/676)	12.03 (102/848)	12.90 (106/822)	12.87 (132/1026)
	2	9.27 (72/777)	11.73 (114/972)	11.85 (100/844)	12.98 (128/986)	13.21 (112/848)	13.89 (120/864)
	3	7.94 (68/856)	9.47 (90/950)	9.76 (80/820)	10.87 (90/828)	11.51 (96/834)	10.98 (84/765)
	Total	8.63 (193/2236)	10.86 (312/2873)	11.03 (258/2340)	12.02 (320/2662)	12.54 (314/2504)	12.66 (336/2655)
10	1	9.24 (90/974)	11.49 (116/1010)	11.55 (105/909)	13.99 (110/786)	14.07 (110/782)	13.90 (108/777)
	2	9.48 (92/970)	11.76 (100/850)	12.18 (94/772)	14.25 (132/926)	14.29 (110/770)	14.92 (134/898)
	3	8.47 (63/744)	9.94 (80/805)	11.32 (96/848)	12.59 (90/715)	12.00 (96/800)	11.64 (88/756)
	Total	9.11 (245/2688)	11.11 (296/2665)	11.66 (295/2529)	13.68 (332/2427)	13.44 (316/2352)	13.57 (330/2431)
25	1	17.73 (150/846)	18.29 (150/820)	19.88 (206/1036)	19.70 (160/812)	19.22 (158/822)	20.38 (214/1050)
	2	17.93 (156/870)	18.89 (190/1006)	20.15 (165/819)	20.16 (200/992)	21.05 (168/798)	21.14 (208/984)
	3	17.39 (160/920)	17.59 (152/864)	17.45 (156/894)	17.81 (176/988)	17.81 (171/960)	18.73 (130/694)
	Total	17.68 (466/2636)	18.29 (492/2690)	19.17 (527/2749)	19.20 (536/2792)	19.26 (497/2580)	20.23 (552/2728)
50	1	18.30 (172/940)	21.01 (166/790)	24.94 (216/866)	25.90 (216/834)	26.94 (222/824)	28.65 (204/712)
	2	18.68 (130/696)	23.01 (168/730)	26.60 (225/846)	28.97 (288/994)	27.44 (219/798)	29.54 (296/1002)
	3	17.44 (136/780)	18.40 (159/864)	24.82 (210/846)	25.69 (224/872)	26.27 (248/944)	27.93 (200/716)
	Total	18.13 (438/2416)	20.68 (493/2384)	25.45 (651/2558)	26.96 (728/2700)	26.85 (689/2566)	28.81 (700/2430)
100	1	90.95 (764/840)	100 (962/962)	100 (828/828)	100 (918/918)	100 (735/735)	100 (982/982)
	2	92.93 (644/693)	100 (984/984)	100 (992/992)	100 (984/984)	100 (982/982)	100 (950/950)
	3	89.94 (715/795)	100 (861/861)	100 (930/930)	100 (714/714)	100 (952/952)	100 (800/800)
	Total	91.19 (2123/2328)	100 (2807/2807)	100 (2750/2750)	100 (2616/2616)	100 (2669/2669)	100 (2732/2732)

**Table 1.** Protoscolicidal effects of various concentrations of *Nicotiana tabacum* L. extract in different exposure times (Continued)

Concentrations		% Mean of mortality rates (dead/total) after exposure					
(mg/ml)	Experiments	10 (min)	20 (min)	30 (min)	40 (min)	50 (min)	60 (min)
Control	1	7.10 (72/1014)	8.02 (56/698)	8.62 (60/696)	8.96 (90/1004)	9.33 (84/900)	10.47 (84/802)
	2	7.96 (78/980)	8.33 (70/840)	8.90 (78/876)	9.55 (102/1068)	10.28 (96/934)	10.99 (82/746)
	3	4.90 (40/816)	4.55 (36/792)	5.65 (46/814)	5.91 (44/744)	6.28 (60/955)	6.67 (46/690)
	Total	6.76 (190/2810)	6.95 (162/2330)	7.71 (184/2386)	8.38 (236/2816)	8.61 (240/2789)	9.47 (212/2238)

#### 4. Discussion

Hydatidosis is widespread worldwide and causes the death of many patients. Surgery is currently considered the best method, but unfortunately, leakage of cyst contents is the most common cause of recurrence during surgery [2, 3, 5].

So far, several protoscolicidal chemicals have been proposed to solve this problem, but many of them have shown side effects that limit their use [1, 6, 30]. According to previous research, exposure with hypertonic salts, formalin, hydrogen peroxide, setrimide, pure alcohol, hypertonic saline, as well as silver nitrate can induce the death of protoscolices [5, 6, 31-34]. The presence of a substance with a rapid and complete protoscoliotoxic effect without any side effects and good cost-efficiency is regarded as part of the features of the best scolical solution; but, no perfect protoscoliotoxic solution has yet been explained. [35, 36]. Tobacco has been used as an herbal medicine, as an anti-worm, anti-inflammatory, anti-insect and anti-fungal [20-24].

In the present work, the efficiency of ethanolic extract of tobacco was explored on protoscolices. According to our findings, at a concentration of 100 mg/ml, 10 minutes of exposure resulted in the death of 91.19 % of protoscolices and longer

exposure times (20 to 60 minutes) resulted in the death of 100 % of protoscolices. The findings of the current study showed that the ethanolic extract of tobacco comprises an efficient protoscolicidal candidate. Although according to this study and previous research, it seems that tobacco, due to its substances such as various organic acids and nicotine sulfate has protoscolicidal effects, it also affects the human immune system, nevertheless, the effects of tobacco scoliosis need further research [35]. We also suggest that the scolical effect of different fractions of tobacco as well as different plant extracts like aqueous extracts, hydroglycolic extracts, glycerin extract, hydroalcoholic extract, be investigated to compare and find the most effective extract on protoscolices [37].

#### 5. Conclusion

We showed a significant scolical capability for *Nicotiana tabacum* L. extract. This may help advance hydatid cyst surgery protocols and resolve shortcomings in the treatment of hydatosis, such as recurrence. Furthermore, we do not have enough information about the effect of this extract on different genomic variants of *Echinococcus granulosus*, which is an area that may need future experiments. In addition, it may

be useful to evaluate the protoscolicidal actions of the alcoholic extract *in vivo*.

### Author contributions

R.L., A.A., S.M., K.S., and R.H. drafted the manuscript. A.A. and R.H. conceptualized and supervised the study. R.L. and S.M. performed the experiments and analyzed the data. A.A. and K.S. analyzed the data. A.A. and K.S. critically appraised the manuscript.

### References

1. Adas G, Arikan S, Kemik O, Oner A, Sahip N and Karatepe O. Use of albendazole sulfoxide, albendazole sulfone, and combined solutions as scolicidal agents on hydatid cysts (in vitro study). *World Journal of Gastroenterology: WJG*. 2009; 15(1): 112. doi: 10.3748/wjg.15.112.
2. Eckert J and Deplazes P. Biological, epidemiological, and clinical aspects of echinococcosis, a zoonosis of increasing concern. *Clin. Microbiol Rev*. 2004; 17(1): 107-135. doi: 10.1128/CMR.17.1.107-135.2004.
3. McManus DP, Zhang W, Li J and Bartley PB. Echinococcosis. *The lancet*. 2003; 362(9392): 1295-1304. doi: 10.1016/S0140-6736(03)14573-4.
4. Prousalidis J, Kosmidis C, Anthimidis G, Kapoutzis K, Karamanlis E and Fachantidis E. Postoperative recurrence of cystic hydatidosis. *Can. J. Surg*. 2012; 55(1): 15-20. doi: 10.1503/cjs.013010.
5. Rajabi MA. Fatal reactions and methaemoglobinaemia after silver nitrate irrigation of hydatid cyst. *Surg. Pract. Practice*. 2009; 13(1): 2-7. doi: 10.1111/j.1744-1633.2008.00427.x.
6. Moazeni M, Saharkhiz MJ and Hosseini AA. In vitro lethal effect of ajowan (*Trachyspermum ammi* L.) essential oil on hydatid cyst

### Conflict of interest

The authors declare that there is no conflict of interest.

### Acknowledgements

We thank the deputy of research and technology of Qazvin University of Medical Sciences and Academic Center for Education, Culture and Research. Also, we appreciate the assistance of Dr. Mahmoud Alipour in statistical analysis.


- protoscoleces. *Vet. Parasitol*. 2012; 187(1-2): 203-208. doi: 10.1016/j.vetpar.2011.12.025.
7. Harris JC, Plummer S, Turner MP and Lloyd D. The microaerophilic flagellate *Giardia intestinalis*: *Allium sativum* (garlic) is an effective anti-giardial. *Microbiology*. 2000; 146(12): 3119-3127. doi: 10.1099/00221287-146-12-3119.
8. Moazeni M and Nazer A. In vitro effectiveness of garlic (*Allium sativum*) extract on scolices of hydatid cyst. *World J. Surg*. 2010; 34(11): 2677-2681. doi: 10.1007/s00268-010-0718-7.
9. Zibaei M, Sarlak A, Delfan B, Ezatpour B and Azargoon A. Scolicidal effects of *Olea europaea* and *Satureja khuzestanica* extracts on protoscolices of hydatid cysts. *Korean. J. Parasitol*. 2012; 50(1): 53. doi: 10.3347/kjp.2012.50.1.53.
10. Shahnazi M, Azadmehr A, Latifi R, Hajiaghache R, Saraei M and Alipour M. In vitro protoscolicidal effects of various concentrations of *Ziziphora tenuior* L. extract at different exposure times. *Avicenna J. Phytomed*. 2016; 6(4): 376. doi: 10.22038/AJP.2016.5961.
11. Moazeni M and Roozitalab A. High scolicidal effect of *Zataria multiflora* on protoscoleces of hydatid cyst: an in vitro study.

- Comparative Clinical Pathology*. 2012; 21(1): 99-104. doi: 10.1007/s00580-010-1069-3.
12. Maggiore MA, Albanese AA, Gende LB, Eguaras MJ, Denegri GM and Elissondo MC. Anthelmintic effect of *Mentha* spp. essential oils on *Echinococcus granulosus* protoscoleces and metacestodes. *Parasitol. Res.* 2012; 110(3): 1103-1112. doi: 10.1007/s00436-011-2595-x.
13. Dawwas A. Investigation of biochemical effect of phenols extract isolated from *Coriandrum sativum* seeds against *Echinococcus granulosus* parasite in vitro. *Univ. Thi-Qar J. Sci.* 2008; 1(1): 2-9.
14. Saleki K, Banazadeh M, Saghazadeh A and Rezaei N. The involvement of the central nervous system in patients with COVID-19. *Rev. Neurosci.* 2020; 31(4): 453-456. doi: 10.1515/revneuro-2020-0026.
15. Saleki K, Banazadeh M, Miri NS and Azadmehr A. Triangle of cytokine storm, central nervous system involvement, and viral infection in COVID-19: the role of sFasL and neuropilin-1. *Rev. Neurosci.* 2022; 33(2): 147-160. doi: 10.1515/revneuro-2021-0047.
16. Amirghofran Z, Bahmani M, Azadmehr A and Javidnia K. Anticancer effects of various Iranian native medicinal plants on human tumor cell lines. *Neoplasma*. 2006; 53(5): 428-433.
17. Amirghofran Z, Azadmehr A and Javidnia K. *Haussknechtia Elymatica*: A Plant with Immunomodulatory Effects. *Iran. J. Immunol.* 2007; 4(1): 26-31.
18. Saleki K, Yaribash S, Banazadeh M, Hajihosseini E, Gouravani M, Saghazadeh A and Rezaei N. Interferon therapy in patients with SARS, MERS, and COVID-19: A systematic review and meta-analysis of clinical studies. *Eur. J. Pharmacol.* 2021; 906: 174248. doi: 10.1016/j.ejphar.2021.174248.
19. Díaz Á. Immunology of cystic echinococcosis (hydatid disease). *Br Med Bull.* 2017; 1-13. doi: 10.1093/bmb/ldx033.
20. Zaman MA, Iqbal Z, Abbas RZ, Khan MN, Muhammad G, Younus M and Ahmed S. *In vitro* and *in vivo* acaricidal activity of a herbal extract. *Vet. Parasitol.* 2012; 186(3-4): 431-436. doi: 10.1016/j.vetpar.2011.11.018.
21. Shaddel TA, Maheri SN, Agha JGA, Asaadi DA and Ahmadzadeh A. The study on the effect of tobacco, harmel and thymus plants on varroa, a honey bee parasite. *Agroecol. J.* 2008; 10(4): 67-72.
22. Mehta R and Anita A. A review on anthelmintic plants. *Natural Product. Radiance.* 2008; 7(5): 466-475.
23. Iqbal Z, Lateef M, Jabbar A, Ghayur MN and Gilani AH. *In vitro* and *in vivo* anthelmintic activity of *Nicotiana tabacum* L. leaves against gastrointestinal nematodes of sheep. *Phytother Res.* 2006; 20(1): 46-48. doi: 10.1002/ptr.1800.
24. Bahmani M, Hosseini S, Avijgan M and Qorbani M. Evaluating the anti-leech effects of tobacco methanolic extract compared with succinyle choline and some other anti-parasite drugs. *Journal of Shahrekord University of Medical Sciences.* 2010; 12(3): 53-59.
25. Amirghofran Z, Bahmani M, Azadmehr A, Ashouri E and Javidnia K. Antitumor Activity and Apoptosis Induction in Human Cancer Cell Lines by *Dionysia termedia*. *Cancer Invest.* 2007; 25(7): 550-554. doi: 10.1080/07357900701518487.
26. Tariku Y, Hymete A, Hailu A and Rohloff J. *In vitro* evaluation of antileishmanial activity and toxicity of essential oils of *Artemisia absinthium* and *Echinops kebericho*. *Chem. Biodivers.* 2011; 8(4): 614-623.
27. Sooudi S, Hashemi S, Zavaran HA, Ghaemi A and Asghari JM. Antileishmanial effect of *Echinacea purpurea* root extract cultivated in

- Iran. *IJPR* 2007; 6(2): 147-149. doi: 10.22037/ijpr.2010.713.
- 28.** Smyth J and Barrett N. Procedures for testing the viability of human hydatid cysts following surgical removal, especially after chemotherapy. *Trans. R. Soc. Trop. Med. Hyg.* 1980; 74(5): 649-652. doi: 10.1016/0035-9203(80)90157-1.
- 29.** Dalimi A, Motamedi G, Hosseini M, Mohammadian B, Malaki H, Ghamari Z and Far FG. Echinococcosis/hydatidosis in western Iran. *Vet. Parasitol.* 2002; 105(2): 161-171. doi: 10.1016/s0304-4017(02)00005-5.
- 30.** Puryan K, Karadayi K, Topcu O, Canbay E, Sumer Z, Turan M, Karayalcin K and Sen M. Chlorhexidine gluconate: an ideal scolicidal agent in the treatment of intraperitoneal hydatidosis? *World J. Surg.* 2005; 29(2): 227-230. doi: 10.1007/s00268-004-7587-x.
- 31.** Kayaalp C, Balkan M, Aydin C, Ozgurtas T, Tanyuksel M, Kirimlioglu V, Akoglu M, Oner K and Pekcan M. Hypertonic Saline in Hydatid Disease. *World J. Surg.* 2001; 25(8): 975-979. doi: 10.1007/s00268-001-0065-9.
- 32.** Erzurumlu K, Hokelek M, Baris S, Sahin M, Birinci A, Amanvermez R and Tac K. Effect of Albendazole sulfoxide solution on the scolices and the hepatobiliary system. *Eur. Surg. Res.* 1998; 30(6): 433-438. doi: 10.1159/000008610.
- 33.** Caglar R, Yuzbasioglu MF, Bulbuloglu E, Gul M, Ezberci F and Kale IT. *In vitro* effectiveness of different chemical agents on scolices of hydatid cyst. *J. Invest. Surg.* 2008; 21(2): 71-75. doi: 10.1080/08941930701883640.
- 34.** Besim H, Karayalçin K, Hamamci O, Güngör C and Korkmaz A. Scolicidal agents in hydatid cyst surgery. *HPB Surg.* 1998; 10(6): 347-351. doi: 10.1155/1998/78170.
- 35.** Rouhani S, Salehi N, Kamalinejad M and Zayeri F. Efficacy of *Berberis vulgaris* aqueous extract on viability of *Echinococcus Granulosus* protoscolices. *J. Invest. Surg.* 2013; 26(6): 347-351. doi: 10.3109/08941939.2013.818746.
- 36.** Adas G, Arikan S, Kemik O, Oner A, Sahip N and Karatepe O. Use of albendazole sulfoxide, albendazole sulfone, and combined solutions as scolicidal agents on hydatid cysts (*in vitro* study). *World J. Gastroenterol.* 2009; 15(1): 112-116. doi: 10.3748/wjg.15.112.
- 37.** Srivastava P, Singh M, Devi G and Chaturvedi R. Herbal Medicine and Biotechnology for the Benefit of Human Health. Animal Biotechnology Seventh Ed., Academic Press, Elsevier 2020; pp: 613-629.

How to cite this article: Latifi R, Azadmehr A, Mosalla S, Saleki K, Hajiaghache R. Scolicidal effects of the *Nicotiana tabacum* L. extract at various concentrations and exposure times. *Journal of Medicinal Plants* 2022; 21(82): 111-118.  
doi: 10.52547/jmp.21.82.111





## فصلنامه گیاهان دارویی

Journal homepage: [www.jmp.ir](http://www.jmp.ir)پژوهشکده گیاهان دارویی  
جهاد دانشگاهی

## مقاله تحقیقاتی کوتاه

## اثرات اسکولیسیدال عصاره گیاه تنباکو در غلظت‌ها و زمان‌های مختلف

رویا لطیفی<sup>۱</sup>، عباس آزادمهر<sup>۲،۳\*</sup>، سحر مصلی<sup>۱</sup>، کیارش سالکی<sup>۴</sup>، رضا حاجی آقایی<sup>۶</sup><sup>۱</sup> گروه انگل‌شناسی، دانشگاه علوم پزشکی قزوین، قزوین، ایران<sup>۲</sup> گروه ایمنولوژی، دانشگاه علوم پزشکی بابل، بابل، ایران<sup>۳</sup> گروه ایمنولوژی، دانشگاه علوم پزشکی قزوین، قزوین، ایران<sup>۴</sup> کمیته تحقیقات دانشجویی، دانشگاه علوم پزشکی بابل، بابل، ایران<sup>۵</sup> دفتر یوسرن، دانشگاه علوم پزشکی بابل، بابل، ایران<sup>۶</sup> مرکز تحقیقات گیاهان دارویی، پژوهشکده گیاهان دارویی جهاد دانشگاهی، کرج، ایران

اطلاعات مقاله	چکیده
گل‌واژگان:	مقدمه: تنباکو گیاهی است که به دلیل داشتن ترکیباتی از قبیل نیکوتین سولفات دارای خواص ضد نماتودی و ضد التهابی است. از این گیاه به عنوان دارو در درمان بیماری‌های عفونی و همچنین برای کشتن لارو حشرات و آفات گیاهی استفاده می‌شود. هدف: هدف از این مطالعه ارزیابی اثر عصاره گیاه تنباکو بر روی اسکولکس‌های کیست هیداتیک بود. روش بررسی: کیست‌های هیداتیک از کبد گوسفندان آلوده در کشتارگاه قزوین جمع‌آوری شد و پروتو اسکولکس‌ها در شرایط استریل از این کیست‌ها جدا شدند. زنده بودن پروتواسکولکس‌ها با روش‌های آزمایشگاهی تأیید شد. پروتواسکولکس‌های زنده با غلظت‌های مختلف عصاره اتانولی گیاه تنباکو (۱، ۵، ۱۰، ۲۵، ۵۰ و ۱۰۰ میلی‌گرم در میلی‌لیتر) در مدت زمان‌های مختلف (۱۰، ۲۰، ۳۰، ۴۰، ۵۰ و ۶۰ دقیقه) مواجه شدند. از کلرید سدیم ۰/۹ درصد به عنوان کنترل منفی استفاده شد. میزان زنده بودن پروتواسکولکس‌ها پس از مواجهه با رنگ‌آمیزی اتوزین ارزیابی شد. نتایج: عصاره تنباکو در غلظت ۱۰۰ میلی‌گرم در میلی‌لیتر در ۱۰ دقیقه باعث کشته شدن ۹۱/۱۹ درصد از پروتواسکولکس‌ها شد در حالی که در باقی زمان‌ها (۲۰ تا ۶۰ دقیقه) منجر به کشته شدن ۱۰۰٪ پروتواسکولکس‌ها شد. نتیجه‌گیری: این گیاه دارویی اثرات ضد پروتواسکولکسی خوبی نشان داد و احتمالاً می‌تواند در جراحی کیست هیداتیک کمک کننده باشد. البته برای مشخص شدن هر چه بهتر نیاز به انجام تحقیقات بیشتر است.

مخفف‌ها: ANOVA، آنالیز واریانس؛ mg، میلی‌گرم؛ ml، میلی‌لیتر

\* نویسنده مسؤول: [a.azadmehr@mubabol.ac.ir](mailto:a.azadmehr@mubabol.ac.ir)

تاریخ دریافت: ۱۵ فروردین ۱۴۰۱؛ تاریخ دریافت اصلاحات: ۲۴ اردیبهشت ۱۴۰۱؛ تاریخ پذیرش: ۳ خرداد ۱۴۰۱

doi: 10.52547/jmp.21.82.111

© 2020. Open access. This article is distributed under the terms of the Creative Commons Attribution-NonCommercial 4.0 International License (<https://creativecommons.org/licenses/by-nc/4.0/>)