



Institute of
Medicinal Plants

Journal of Medicinal Plants

Journal homepage: www.jmp.ir



Research Article

Evaluation of wound healing and anti-inflammatory activities of a herbal ointment consisting of *Althaea officinalis*, *Lavandula angustifolia*, and *Rosa x damascena* in animal excision wound model

Saeideh Momtaz^{1,*}, Amir Hossein Abdolghaffari², Eghbal Jasemi¹, Bahman Yaqoobvand¹, Saeed Esmaeilzadeh¹, Alireza Abdollahi³, Mohammad Abdollahi⁴

¹ Medicinal Plants Research Center, Institute of Medicinal Plants, ACECR, Karaj, Iran

² Department of Toxicology and Pharmacology, School of Pharmacy, Tehran Medical Sciences, Islamic Azad University, Tehran, Iran

³ Department of Pathology, Imam Hospital Complex, Tehran University of Medical Sciences, Tehran, Iran

⁴ Department of Toxicology and Pharmacology, Faculty of Pharmacy, Tehran University of Medical Sciences, Tehran, Iran

ARTICLE INFO

Keywords:

Althaea officinalis
Lavandula angustifolia
Rosa x damascena
Excision wound healing
Inflammation

ABSTRACT

Background: *Althaea officinalis* L., *Lavandula angustifolia* Mill. and *Rosa x damascena* Herrm. are used to treat excision or burn lesions in traditional medicine. **Objective:** To evaluate the healing effect of a polyherbal ointment containing *L. angustifolia*, *R. x damascena*, and *A. officinalis* combination on wounds caused by third grade skin cut. **Methods:** To evaluate the wound healing effect of this polyherbal formulation, an ointment containing the extract of *A. officinalis*, the essential oil of *R. x damascena* (2 % essence) and the essential oil of *L. officinalis* (2 % essence) in an eucerin base (20:20:10:50) was prepared. The formulation was examined using excision wound test for 14 days and the percentage of healing effect in each group was calculated. Formalin induced rat hind paw edema method was used for determination of anti-inflammatory activities of the same formulation. **Results:** The percentage of recovery in the polyherbal formulation group was significantly higher than the other groups. Histological studies also confirmed these results. Herbal formulation treated group showed significant improvement in terms of re-epithelialization, angiogenesis, collagen deposition, and reducing inflammation. The percentage of wound healing was 99.07 ± 0.34 , 99.22 ± 0.35 , 98.45 ± 0.733 , 98.75 ± 0.88 and 63.72 ± 5.64 , for the polyherbal formulation, *L. angustifolia*, *R. damascena*, *A. officinalis* extracts, and the placebo group, respectively. **Conclusion:** This polyherbal formulation could act as a wound healing agent, possibly due to the suppression of inflammatory mediators. The presence of phenolic compounds might be a reason behind the therapeutic effect of these plants.

Abbreviations: NSAIDs, Nonsteroidal Anti-inflammatory Drugs; IgE, Immunoglobulin E; COX, Cyclooxygenase

* Corresponding author: momtaz@imp.ac.ir

doi: 10.29252/jmp.20.77.37

Received 7 March 2020; Received in revised form 27 September 2020; Accepted 9 November 2020

© 2020. Open access. This article is distributed under the terms of the Creative Commons Attribution-NonCommercial 4.0 International License (<https://creativecommons.org/licenses/by-nc/4.0/>)

1. Introduction

Wound healing is one of the major problems and costly events with a huge global market for wound care products. It was reported that this market exceeded US\$ 15 billion for wound care products and US\$ 12 billion for treating wound scarring [1]. The process of wound healing is an innate physiological process that ultimately leads to the reconstruction of damaged skin. However, the acceleration of recovery with the goal of preventing wound complications is an essential and inevitable necessity [2-4]. One of these consequences is inflammation, which, if continued, can lead to a weakening of the immune system. Therefore, another therapeutic goal in wound healing is to reduce inflammation and its respective complications [5, 6]. Drugs used to treat inflammation, such as nonsteroidal anti-inflammatory drugs (NSAIDs), often have known side effects, which can include problems in digestive, renal and respiratory system, and also drug dependence [7-9]. Today, it has been proven that natural-derived drugs improve wound healing and reduce inflammation, but instead, show fewer side effects. Plant species such as *Althaea officinalis* L., *Lavandula angustifolia* Mill. and *Rosa x damascena* Herrm. have been of great importance in Iranian traditional medicine since ancient times and have antibacterial and anti-inflammatory properties [10-12].

L. angustifolia (lavender) is well known in traditional medicine in the treatment of digestive disorders, neurological diseases, and rheumatism (13-15). Phytochemical studies revealed that linalool, linalyl acetate and some other mono and sesquiterpenes, flavonoids (i.e. luteolin), triterpenoids (i.e. ursolic acid), as well as coumarins such as umbelliferone and coumarin were the main components of the aerial parts and flowers of the plant [13, 15, 16]. The lavender oil

was shown to have anti-inflammatory effects and significantly reduced the levels of immunoglobulin E (IgE) and histamine in rats [17]. The biological studies of this plant revealed a dose-dependent anti-inflammatory activity for the ethanolic extract, while the aqueous type showed less effectiveness [18]. Lavender significantly diminished heat-induced pain. Furthermore, in a dose dependent manner, the extract of lavender reduced cyclooxygenase (COX)-2 enzyme activity, where the inhibitory effect on COX-1 was 33 % and for COX-2 was 45 % [19]. Consequently, these data confirm that lavender is a potential treatment for wound healing; in the initial phase by creating tissue granules, recovering damaged tissues by replacing collagen and wound reduction through activating of TGF- β signaling pathway.

A. officinalis is being considered for many years in traditional medicine for treating inflammation, coughing, bronchitis, gastritis, kidney stones, bladder diseases, and skin diseases such as eczema [20-22]. Regarding wound healing, the main constituents responsible for pain reduction and the inflammation suppression are known to be polyphenols, flavonoids, anthocyanins, dioxybutyric acid and terpenoids [23, 24], while, pectins in this plant has an immune stimulating effect and is able to accelerate the process of wound healing. The aqueous extract of this plant stimulates phagocytosis, production of oxygen radicals and release of leukotriene from neutrophils. Besides, by stimulating monocytes, it secretes cytokines, IL-6 and tumor necrosis factor from these cells [25].

R. x damascena contains many compounds such as kaempferol and quercetin, as well as their glycoside derivatives, carboxylic acid, myrcene, terpene and tannins [26-28]. The essential oil of this plant consists of β -citronellol, nonadecane,

geraniol and docosane [29]. It has been reported that *R. x damascena* have a broad range of pharmacological functions such as cardiogenic, anti-constipation, anti-inflammatory, antioxidant cough suppressant, analgesic and attenuation of digestive problems [30-32]. Studies conducted over the last few years showed that the plant also has anti-HIV, antibacterial, antitussive, respiratory smooth muscle relaxant properties, and skin wound healing activities [26, 33-36].

Given the importance of wound healing and lack of efficient drugs in this regard, exploration on novel drugs especially with natural origin seems requisite. In the present study, the healing effect of a polyherbal ointment, consisting of *L. angustifolia*, *A. officinalis* and *R. x damascena* extracts has been evaluated in third grade excision wound in rats. Moreover, their anti-inflammatory properties were assessed to declare the probable wound healing mechanism of LAR.

2. Material and Methods

2.1. Chemicals

All reagents and solvents were of analytical grade or pure quality which was purchased from Merck Company (Germany). Phenytoin sodium 1% was purchased from Medipharma Company (Iran).

2.2. Extracts

Herbal extracts were purchased commercially from the following companies: essential oil of *R. x damascena* (2 ml) and *L. angustifolia* (2 ml) of Narin Gol Co., and the extract of *A. officinalis* from Zardband Co.

2.3. Animals

In this study, 72 male Wistar rats weighing between 180 and 200 grams, were divided into 6 groups of 6 (36 rats for each experiment; wound healing and anti-inflammatory tests) and

maintained under controlled conditions of light (12 hours light/dark cycles), room temperature (23 ± 1 °C) and relative humidity ($50 \% \pm 10 \%$) with free access to food and water ad libitum. This study was undertaken according to the suggested international ethical guidelines for care of laboratory animals under the audit of the commission of animal ethics, Tehran University of Medical Sciences (IR.TUMS. VCR.REC. 1398.446). All the ethical concerns were cautiously adhered.

2.4. Wound creation method

This assay was performed according to Karami et al. with slight modifications [37]. The dorsal region of the rats from the scapular to the ileum were shaved under anesthesia by intraperitoneal injection of 100/10 mg/kg Ketamine/Xylazine, a shear wound of 20×20 mm was created. Male Wistar rats were divided into 6 groups of 5. The first group received a topical ointment containing essential oil of *R. x damascena* (2 % essence) in eucerin. The second group received an ointment containing the extract of *A. officinalis* in eucerin. The third group received an ointment of essential oil of *L. angustifolia* (2 % essence) in eucerin. The fourth group treated with a blend of an ointment containing the extract of *A. officinalis*, the essential oil of *R. x damascena* (2 % essence) and the essential oil of *L. officinalis* (2 % essence) in an eucerin base (20:20:10:50), respectively. One group was considered as positive control (Phenytoin 1 % ointment), and a group treated with eucerin. The study was performed for 14 days and the percentage of healing effect in each group was calculated. The concentrations of sample extracts have been selected based on some pilot studies in our lab (data are not included). Treatment was started on the first day after wound induction; samples were applied

topically and the wounds were dressed up once a day for 14 days. The wounds in all groups were examined and photographed on a daily schedule until the 14th day. Finally, the wound area was measured using ImageJ software.

$$\text{Wound reduction (\%)} = \frac{(\text{zero day wound size} - \text{specific day wound size})}{\text{zero day wound size}} \times 100$$

The diameter of the wound and crust characteristics were monitored during the 14 days of the experiment and photos of the lesions were taken at daily intervals. 13-megapixel digital capture camera with fixed focus was used, with a spacer tube coupled to the lens. In order to reference and measure the diameter of the wound, a millimeter ruler was positioned. The wound diameter on each photo was analyzed with ImageJ software (version 1.44 p). The Ferret diameter of the ellipse formed by the wound's margin lineament was measured. The data obtained from the measurement of wound area were analyzed by one-way ANOVA test.

$$\text{Inhibition (\%)} = \frac{\text{Mean paw diameter (control)} - \text{Mean paw diameter (treated)}}{\text{Mean paw diameter (control)}} \times 100$$

2.6. Histopathological evaluation

At day 14, granulated tissues were collected from dorsal parts of rats and preserved in 10 % buffered formalin. Series of 3-4 μm thickness sections were prepared and stained with hematoxylin-eosin and photographed under 400 \times magnification. The rate of re-epithelialization, collagenation, neovascularization (angiogenesis) and inflammatory cells were evaluated by an expert histopathologist [40].

2.7. Statistical analysis

All data were expressed in SPSS software (version 22) as the mean \pm SEM (standard error of the mean). Statistical differences between

2.5. Anti-inflammatory experiments

Animals were set as, 1) *R. x damascena* (2 % essences); 2) *A. officinalis*; 3) *L. angustifolia* (2 % essences); 4) polyherbal formulation consisted of *R. x damascena*, *A. officinalis*, *L. angustifolia*) in an eucerin base (20:20:10:50), respectively; 5) Dexamethasone (15 mg/kg/BW); 6) formalin (2.5 %); 7) normal saline; and 8) control. One hour before the injection of formalin (inflammation induction), the extracts were injected intraperitoneally. Later, in order to evaluate the anti-inflammatory activity of the samples, all the groups were administered 50 μl of a 2.5 % solution of formalin, subcutaneously under the plantar surface of the left hind-paw by injection subcutaneously under the plantar surface of the left hind-paw. Then, every 45 minutes, the diameter of the palm of foot is measured by a Vernier caliper (measurement accuracy 0.1 mm). After the injection, the measurements were repeated for four times. The difference between the readings at time 45 min and different time interval was taken as the level of inflammation [38, 39].

treated and control groups were examined one-way ANOVA, followed by Tukey's post hoc test (Stats-Direct version 3.1.18). Differences in means were considered to be significant when $P < 0.05$.

3. Results

3.1. Wound healing activity

Topical application of the extracts in the four groups compared with the control group significantly ($P < 0.005$) led to decrease in the area of the ulcer from the 7th day, by which the polyherbal formulation exhibited the highest reduction of wound size as followed by the extract of *R. damascena*.

Thereby, the percentage of wound closure at the final day of the experiment was 99.07 ± 0.34 , 99.22 ± 0.35 , 98.45 ± 0.733 and 98.75 ± 0.88 respectively, for the polyherbal formulation, *R. damascena*, *L. angustifolia*, and *A. officinalis* extracts. These results were achieved when the percentage of wound healing in the placebo group was 63.72 ± 5.64 and for phenytoin treated rats was 73.00 ± 4.80 (Table 1, Fig. 1).

3.2. Histopathological study

The polyherbal formulation-treated group showed significant improvement in wound healing process in comparison with the control group. The microscopic views have been shown in Fig. 2. Microscopic examination showed that in the control group the collagen fibers were unorganized and re-epithelialization was not complete. Severe inflammation, low angiogenesis, and low collagen deposition were identified. The dermis layer was infiltrated with many inflammatory cells, and congestion of capillaries. In phenytoin treated group, near complete re-epithelialization, limited inflammatory cell infiltrations, moderate inflammation, more collagenation and neovascularization were observed. In case of *R. damascena*, adequate re-epithelialization and granulation tissue of epidermis appeared near complete, obvious neovascularization was monitored, while mild inflammation, moderate angiogenesis and severe fibroplasia were recorded. For *L. angustifolia*, the blood vessel formation and epidermal regeneration were found significant, also the collagen deposition, fibroplasia were moderate. *A. officinalis* made

nearly full re-epithelialization in all samples; whereas moderate inflammation, angiogenesis and collagen deposition were detected. The microscopic results for the polyherbal formulation were found similar to that of *R. damascena*. Adequate epithelialization and reduced inflammatory cells infiltration, well-formed granulation tissue of epidermis, increased number of new capillaries (neovascularization) and irregular myofibroblast distributions, collagen fibers and many fibroblasts were present. Of note, the extent of the scar reduced in order of the polyherbal formulation-treated animals, followed by *R. x damascena*, *A. officinalis* and *L. angustifolia*. All the experimental samples exhibited better wound healing effects than the control group, in terms of re-epithelialization, inflammation, angiogenesis and collagen deposition.

Table 1. Percentage reduction of wound size in control and treated rats

Groups	14 th day	P value
Negative Control ^a	63.72 ± 5.64	
Positive Control ^b	73.00 ± 4.80	
<i>A. officinalis</i>	98.75 ± 0.88	***
<i>L. angustifolia</i>	98.45 ± 0.733	***
<i>R. damascena</i>	99.22 ± 0.35	***
Polyherbal formulation ^c	99.07 ± 0.34	***

^a Positive Control: Phenytoin

^b Negative Control: Eucerin-treated rats

^c Polyherbal formulation: A blend of an ointment containing the extract of *A. officinalis*, the essential oil of *R. x damascena* (2 % essence) and the essential oil of *L. officinalis* (2 % essence) in an eucerin base (20:20:10:50)

*** Significantly different from negative control (P < 0.001)

[Downloaded from jmp.ir on 2025-08-31]
[DOR: 20.1001.1.2717204.2021.20.77.5.6]
[DOI: 10.52547/jmp.20.77.37]
















Phenytoin	Control	<i>Althaea officinalis</i>	<i>Rosa damascene</i>	<i>Levandula angustifolia</i>	Polyherbal formulation	Wound Day
						1
						7
						14

Fig. 1. The wound healing process of the experimental samples

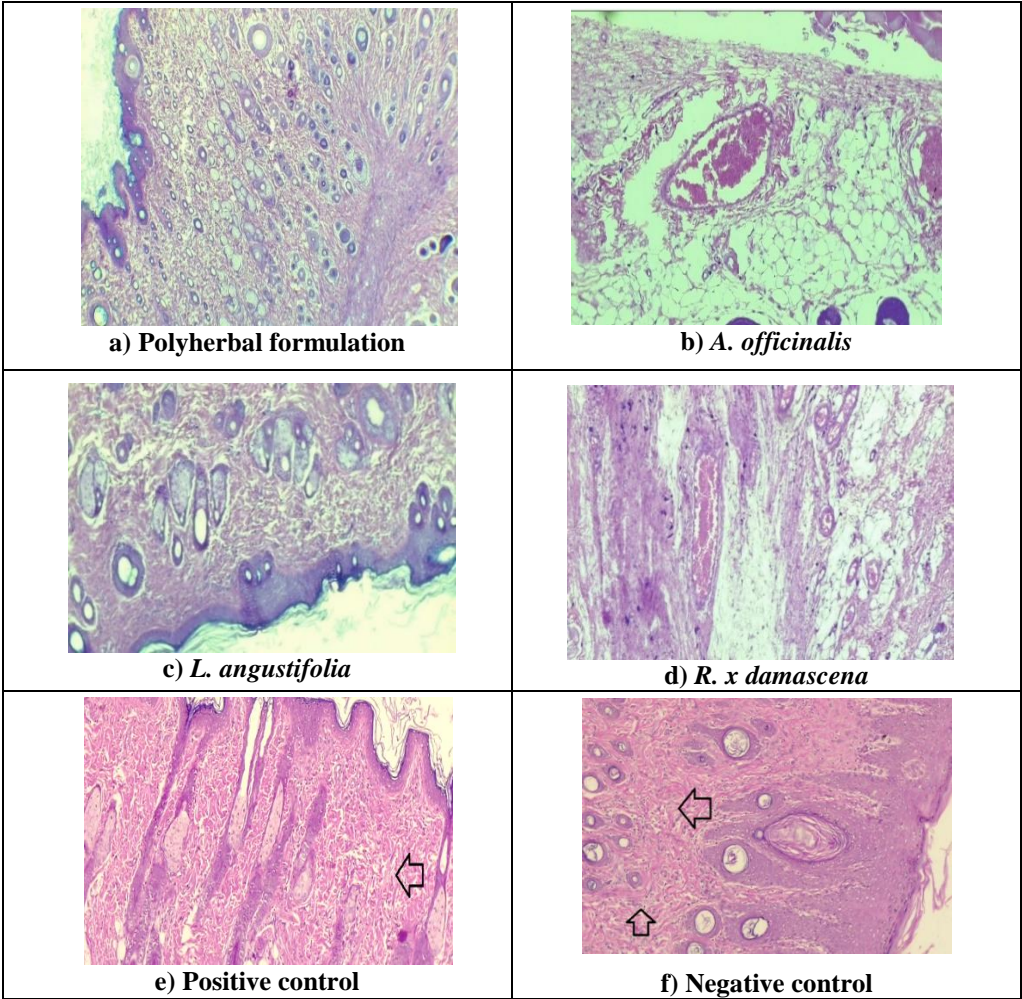


Fig. 2. Microscopic panel of wound on the 14th day of treatment in rats. a) Polyherbal formulation treated wound, b) *A. officinalis* treated wound, c) *L. angustifolia* treated wound, d) *R. x damascena*, e) phenytoin treated wound, and f) non-treated wounds. 400× magnification. Skin sections show the hematoxylin and eosin stained epidermis and dermis.

3.3. Anti-inflammation activity

Fig. 3 depicts the effect of three plant extracts alone or their combination on suppression of the paw edema induced by formalin in rats as shown in. The highest anti inhibitory activity was

obtained by the polyherbal formulation, almost similar to that one of Dexamethasone. However, Dexamethasone showed a stronger effect on the reduction of inflammation caused by formalin than each of the herbal extract (Table 2).

Table 2. Anti-inflammatory effects of the experimental formalin-induced paw edema in rats

Samples	Diameter of the foot (mm ²) 45 min	P value	Diameter of the foot (mm ²) 90 min	P value	Diameter of the foot (mm ²) 135 min	P value	Diameter of the foot (mm ²) 180 min	P value
Control ^a	3.485 ± 0.637	-	4.185 ± 0.349	-	4.288 ± 0.637	-	4.225 ± 0.636	-
Formalin	3.355 ± 0.355	-	4.105 ± 0.514	-	4.5 ± 0.103	-	4.475 ± 0.154	-
Saline	3.230 ± 0.046		3.375 ± 0.339		3.18 ± 0.305		3.18 ± 0.304	
Dexamethasone	2.25 ± 0.058	***	2.263 ± 0.522	***	2.503 ± 0.314	***	2.35 ± 0.258	***
Polyherbal formulation ^b	2.385 ± 0.382	**	2.52 ± 0.397	***	2.88 ± 0.169	***	2.58 ± 0.348	***
<i>L. angustifolia</i>	3.944 ± 0.289	-	3.58 ± 0.555	-	3.42 ± 0.391	**	3.42 ± 0.391	**
<i>R. x damascena</i>	2.936 ± 0.458	-	3.164 ± 0.164	-	3.18 ± 0.301	***	3.02 ± 0.139	***
<i>A. officinalis</i>	3.664 ± 0.279	-	3.18 ± 0.308	-	3.162 ± 0.294	***	3.022 ± 0.204	***

^a Control: non-treated rats, ^b Polyherbal formulation: a blend of an ointment containing the extract of *A. officinalis*, the essential oil of *R. x damascena* (2 % essence) and the essential oil of *L. officinalis* (2 % essence) in an eucerin base (20:20:10:50). Results are expressed as means ± SEM; (n = 5 rats/group). *** significantly different from control (P < 0.001); ** significantly different from control (P < 0.01). The statistical analysis was carried out by one-way analysis of variance (ANOVA) followed by Tukey's post hoc test.

4. Discussion

Wound healing is a normal and complicated process of recovering the cellular structures in damaged tissues, to repair the injury and return it back to its natural condition. Generally, wound reduction and the healing procedure begin in the fibroblastic stage, where the wound starts to wrinkle. Wound healing is consisted of three phases, inflammatory, proliferative and maturational stages, which strictly depends on the type and the extent of damage, and the host's health conditions. Following the inflammatory phase, the proliferative phase including epithelialization, angiogenesis, and collagen deposition takes place. Eventually, the wound starts contraction, this is the maturational phase. Individuality, indigenoussness and availability of plants, as well as being innovative in sanitary application, making them great choices in market presence and can be important contributors for

threatening different kind of injuries, particularly skin wound healing.

As mentioned earlier, chemical composition of selected plants through various mechanisms might provide a basis for acceleration of wound healing process. Our results indicated that the selected plant extracts alone or their combination were significantly effective on wound healing and reduced the duration of wound healing compared with the control, besides the formulation did not show any harmful effect. The percentage of wound healing was 99.07 ± 0.34, 99.22 ± 0.35, 98.45 ± 0.733, 98.75 ± 0.88 and 63.72 ± 5.64, for the polyherbal formulation, *L. angustifolia*, *R. damascena*, *A. officinalis* extracts, and the placebo group, respectively. The percentage of recovery in the polyherbal formulation group was significantly higher than the other groups.

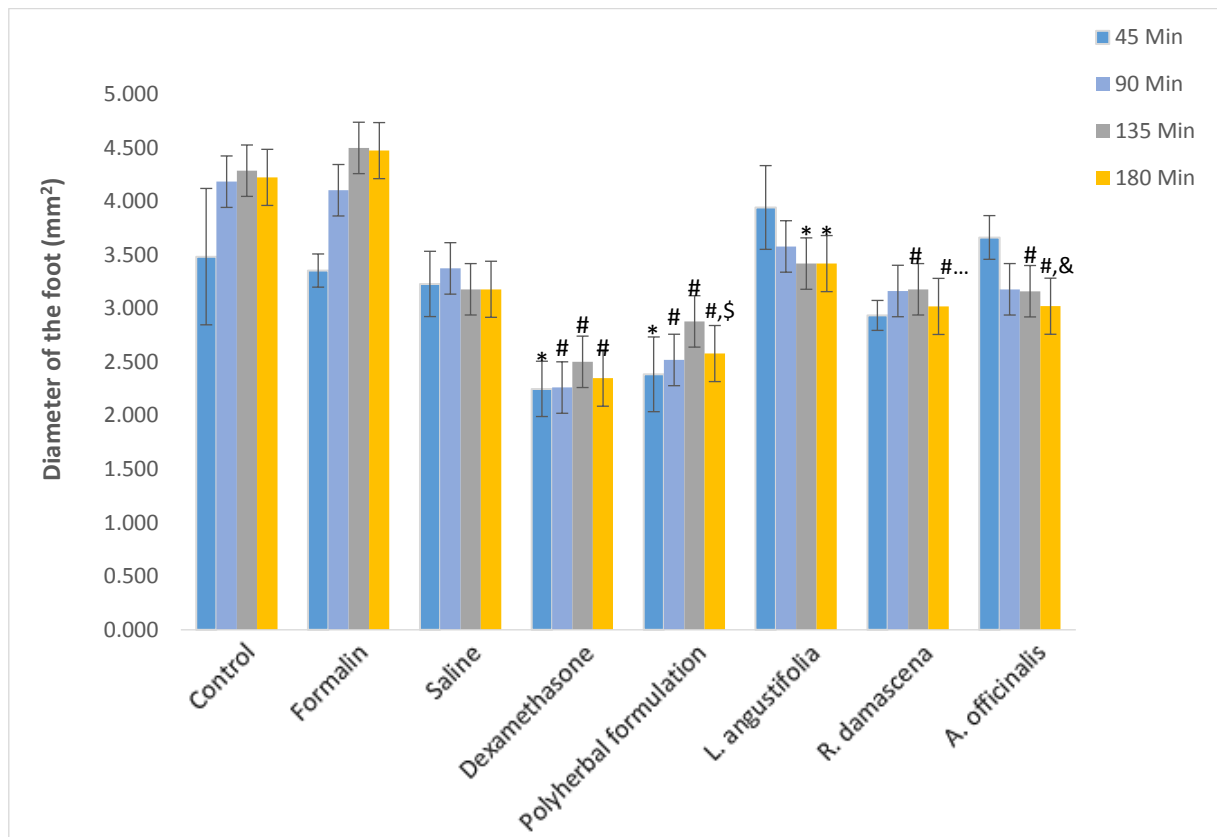


Fig. 3. Anti-inflammation effect of herbal extracts and polyherbal formulation therapy on formalin-induced paw edema in rats. Data represent the diameter of the foot (mm^2) in the control group, formalin, saline, dexamethasone, and herbal extracts groups. Results are expressed as means \pm SEM; ($n = 5$ rats/group). The statistical analysis was carried out by one-way analysis of variance (ANOVA) followed by Tukey's post hoc test.

* Significantly different from formalin ($P < 0.01$)

Significantly different from formalin ($P < 0.001$)

\$ Significantly different from control ($P < 0.01$)

* Significantly different from formalin ($P < 0.001$)

Significantly different from formalin ($P < 0.001$)

\$ Significantly different from control ($P < 0.001$)

A practicing model of inflammation in the research for new anti-inflammatory drug was formalin-induced rat paw edema (41, 42), based on the release of substance P, prostanoids, 5-hydroxytryptamine and histamine (42). Despite the slower rate of wound healing of *L. angustifolia* and *A. officinalis* in 7th early days of the treatment, they demonstrated significant potential for healing process at the end of the treatment period. However, both *R. x damascena* and the polyherbal formulation effectively improved the wound recovery by time until day 14. Interestingly, all the experimental samples appeared more effective than the positive control. Since, inflammation is a known factor that delays

the healing period and enhances scarring, therefore, the anti-inflammatory agents are supposed favorable for wound healing. Our polyherbal formulation significantly reduced the inflammation at 90, 135 and 180 min, following the induction of formalin edema ($P < 0.001$), comparing to the control and formalin groups. Other plant extracts showed similar anti-inflammatory effects, less than the polyherbal formulation. Further, histopathological assessment confirmed the potential of the polyherbal formulation in wound healing, showing complete re-epithelialization, well-formed granulation tissue, reduced scar extent, with neovascularization.

Previously, it was proven that a polyherbal product consisting of the aqueous extracts of *Malva sylvestris* and *Solanum nigrum* leaves and oily extract of *R. x damascena* was effective on second-degree burn wounds. The authors claimed that such effect was mainly attributed to their antioxidant, anti-inflammatory and antimicrobial of their phytochemical constituents, causing significant improvement of re-epithelialization and neovascularization, scavenging of destructive free radicals and inflammation reduction [43]. The essential oil of lavender was found beneficial for episiotomy wound care in a randomized control trial conducted on 120 primiparous women with singleton pregnancy [44]. In another study, topical application of lavender oil increased the expression of transforming growth factor- β (TGF- β), collagen synthesis, and the differentiation of skin fibroblasts [45]. The hydroalcoholic extract of the leaves of *A. officinalis* was shown wound healing potency in rat model of excision wound [46]. Such results are in accordance with our findings, as we found all 3 extracts were effective on wound healing process, yet their combination was significantly more efficacious. Besides, the combination of these plant species conquered the inflammation state caused by formalin, suggesting that the mechanism behind the healing properties of this topical formulation is related to the anti-inflammatory potential of its active ingredients, at least in part. Moreover, there are clinical evidence on the presence of bioadhesive and mucilaginous polysaccharides in different parts of *A. officinalis*, stimulating the cell physiology of epithelial cell and physical formation of mucin-like on top of the irritated tissues, leading

to the treatment of irritated mucous membranes within tissue regeneration [47]. Another way, it has been documented that a moist environment can facilitate the wound healing procedure, thereby, the high mucilage content of *A. officinalis* can provide a proper moist condition for injured skin cells. This results in a faster re-epithelialization, autolytic debridement, angiogenesis, better migration of keratinocytes, and the production of endogenous wound healing stimulants, providing an ideal wound healing condition [48, 49].

5. Conclusion

In conclusion, based on the pharmacological potential and phytochemical content of the selected plant species, their combination application and concurrent use is suggested during the early and late stages of wound treatment. In addition, the anti-inflammatory effect of selected species suggests to evaluate the probable inflammatory mediators and pathways that might be involved. Considering the angiogenic and anti-inflammatory effects of the cream, diabetic ulcers and bed sore are recommended for future studies.

Author contributions

Conceptualization: S. M., AH. A. and S. E.; Data analysis: S. M. and AH. A.; Formal analysis: E. J. and B. Y.; Investigation: AR. A., E. J. and B. Y.; Project administration: AH. A. and S. M.; Supervision: M. A. and S. M.; Writing original draft: E. J.; Editing: S. M. and AH. A.

Conflict of interest

All authors declare that there is no conflict of interest.

References


1. Sen CK, Gordillo GM, Roy S, Kirsner R, Lambert L, Hunt TK, Gottrup F, Gurtner GC and Longaker MT. Human skin wounds: a major and snowballing threat to public health and the economy. *Wound Repair. Regen.* 2009; 17(6): 763-71. doi: 10.1111/j.1524-475X.2009.00543.x.
2. Singer AJ and Clark RA. Cutaneous wound healing. *New England J. Med.* 1999; 341(10): 738-46. doi: 10.1056/NEJM199909023411006.
3. Janis J and Attinger C. The basic science of wound healing. *Plast. Reconstr. Surg.* 2006; 117: 12S-34S. doi: 10.1097/01.prs.0000225430.42531.c2.
4. Martin P. Wound healing-aiming for perfect skin regeneration. *Sci* 1997; 276(5309): 75-81. doi: 10.1126/science.276.5309.75.
5. Anderson JM. Inflammation, wound healing, and the foreign-body response. In: Ratner B, Hoffman A, Schoen F and Lemons J. *Biomaterials Science: An Introduction to Materials*. Third ed., Elsevier Inc.; 2013.
6. Eming SA, Krieg T and Davidson JM. Inflammation in wound repair: molecular and cellular mechanisms. *J. Investigative Dermatol.* 2007; 127(3): 514-25. doi: 10.1038/sj.jid.5700701.
7. Rainsford K. Profile and mechanisms of gastrointestinal and other side effects of nonsteroidal anti-inflammatory drugs (NSAIDs). *The American J. Med.* 1999; 107(6): 27-35. doi: 10.1016/s0002-9343(99)00365-4.
8. Bjarnason I and Hayllar J. Side effects of nonsteroidal anti-inflammatory drugs on the small and large intestine in humans. *Gastroenterol.* 1993; 104(6): 1832-47. doi: 10.1016/0016-5085(93)90667-2.
9. Lawson A and Walton, B. Monitoring side effects of long-term NSAID use in dogs with chronic osteoarthritis. *Br. Med. J.* 2019; 41(4): 148-54. doi: 10.1136/inp.11506.
10. Giovannini D, Gismondi A, Basso A, Canuti L, Braglia R, Canini A, Mariani F and Cappeli G. *Lavandula angustifolia* Mill. essential oil exerts antibacterial and anti-inflammatory effect in macrophage mediated immune response to *Staphylococcus aureus*. *Immunol. Invest.* 2016; 45(1): 11-28. doi: 10.3109/08820139.2015.1085392.
11. Shohayeb M, Abdel-Hameed E-SS, Bazaid SA and Maghrabi I. Antibacterial and antifungal activity of *Rosa damascena* Mill. essential oil, different extracts of rose petals. *Glob. J. Pharmacol.* 2014; 8(1): 1-7. doi: 10.5829/idosi.gjp.2014.8.1.81275.
12. Shah SA, Akhtar N, Akram M, Shah PA, Saeed T, Ahmed K and Asif HM. Pharmacological activity of *Althaea officinalis* L. *J. Med. Plants Res.* 2011; 5(24): 5662-6. doi: 10.5897/JMPR.9000968.
13. Duke JA. *Handbook of Medicinal Herbs*. Second ed., New York: CRC Press; 2002.
14. Trease GE. Trease and Evans' *Pharmacognosy*. Thirteenth ed., London: Bailliere Tindall; 1989.
15. Leung AY and Foster, S. *Encyclopedia of Common Natural Ingredients Used in Food, Drugs and Cosmetics*. Second ed., New York: Wiley; 1996.
16. Omidbaigi R. *Production and Processing of Medicinal Plants*. Fourth ed., Mashhad: Astane-e-Ghods-e-Razavi. Press s; 2007: 256-267.
17. Kim HM and Cho SH. Lavender oil inhibits immediate-type allergic reaction in mice and rats. *J. Pharm. Pharmacol.* 1999; 51(2): 221-6. doi: 10.1211/0022357991772178.
18. Sosa S, Altinier G, Politi M, Braca A, Morelli I and Della Loggia R. Extracts and constituents of *Lavandula multifida* with topical anti-inflammatory activity. *Phytomed.* 2005; 12(4): 271-7. doi: 10.1016/j.phymed.2004.02.007.

19. Hussein Y, Sahraei H, Meftahi GH, Dargahian M, Mohammadi A, Hatef B, Zardooz H, Ranjbaran M, Hosseini SB, Alibeig H, and Behzadnia M. Analgesic and anti-inflammatory activities of hydro-alcoholic extract of *Lavandula officinalis* in mice: possible involvement of the cyclooxygenase type 1 and 2 enzymes. *Rev. Bras. Farmacogn.* 2016; 26(1): 102-8. doi: 10.1016/j.bjp.2015.10.003.
20. Mosihuzzaman M and Choudhary I. Protocols on safety, efficacy, standardization, and documentation of herbal medicine (IUPAC Technical Report). *Pure Appl. Chem.* 2008; 80(10): 2195-2230. doi: 10.1351/pac200880102195.
21. Sutovska M, Nosalova G, Sutovsky J, Franova S, Prisenznakova L and Capek P. Possible mechanisms of dose-dependent cough suppressive effect of *Althaea officinalis* rhamnolacturonan in guinea pigs test system. *Int. J. Biol. Macromol.* 2009; 45(1): 27-32. doi: 10.1016/j.ijbiomac.2009.03.008.
22. Prade RA, Zhan D, Ayoubi P and Mort AJ. Pectins, pectinases and plant-microbe interactions. *Biotechnol. Genet. Eng. Rev.* 1999; 16(1): 361-92. doi: 10.1080/02648725.1999.10647984.
23. Miguel MG. Anthocyanins: antioxidant and/or anti-inflammatory activities. *J. Appl. Pharm. Sci.* 2011; 1(6): 7-15.
24. Muthiah NS, Viswanathan S, Thirugnansambantham P, Reddy MK and Vijayasekaran V. Anti-inflammatory activity of flavone and its methoxy derivatives: a structure activity study. *Ind. J. Pharmac. Sci.* 1993; 55(5): 83-180. doi: 10.1016/s0378-8741(98)00109-3.
25. Scheffer J, Wagner H and Proksch A. Radix althaeae und Flores chamomillae Extrakte auf Entzündungsreaktionen humaner neutrophiler Granulozyten, Monozyten und Rattenmastzellen. Third Phytotherapy Congress Lübeck-Travemünde. 1991.
26. Mahmood N, Piacente S, Pizza C, Burke A, Khan AI and Hay AJ. The anti-HIV activity and mechanisms of action of pure compounds isolated from *Rosa damascena*. *Biochem. Biophys. Res. Commun.* 1996; 229(1): 73-9. doi: 10.1006/bbrc.1996.1759.
27. Schiber A, Mihalev K, Berardini N, Mollov P and Carle R. Flavonol glycosides from distilled petals of *Rosa damascena* Mill. *Z Naturforsch. C* 2005; 60(5-6): 379-84. doi: 10.1515/znc-2005-5-602.
28. Buckle J, RGN M, BPhil CE and Mispa M. Clinical Aromatherapy in Nursing. First ed., London: CRC Press Arnold; 1997.
29. Loghmani-Khozani H, Sabzi Fini O and Safari J. Essential oil composition of *Rosa damascena* Mill. cultivated in central Iran. *Sci. Iran* 2007; 14(4): 316-9.
30. Yassa N, Masoomi F, Rohani Rankouhi SE and Hadjiakhoondi A. Chemical composition and antioxidant activity of the extract and essential oil of *Rosa damascena* from Iran, population of Guilan. *Daru J. Pharm. Sci.* 2009; 17: 175-80.
31. Zargari A. Medicinal Plants. Fifth ed., Iran: Tehran TehranUniversity Publications; 1992. 281-284.
32. Akram M, Riaz M, Munir N, Akhter N, Zafar S, Jabeen F, Ali Shariati M, Akhtar N, Riaz Z, Altaf SH and Daniyal M. Chemical constituents, experimental and clinical pharmacology of *Rosa damascena*: a literature review. *J. Pharm. Pharmacol.* 2020;72(2):161-74. doi: 10.1111/jphp.13185.
33. Umezu T. Anticonflict effects of plant-derived essential oils. *Pharmacol. Biochem. Behav.* 1999; 64(1): 35-40. doi: 10.1016/s0091-3057(99)00115-x.

34. Basim E and Basim H. Antibacterial activity of *Rosa damascena* essential oil. *Fitoterapia* 2003; 74(4): 394-6. doi: 10.1016/s0367-326x(03)00044-3.
35. Shafei MN, Rakhshandah H and Boskabady MH. Antitussive effect of *Rosa damascena* in guinea pigs. *Iranian J. Pharm. Res.* 2003; 2: 4-231. doi: 10.22037/ijpr.2010.61.
36. Boskabady MH, Kiani S and Rakhshandah H. Relaxant effects of *Rosa damascena* on guinea pig tracheal chains and its possible mechanism(s). *J. Ethnopharmacol.* 2006; 106(3): 377-82. doi: 10.1016/j.jep.2006.01.013.
37. Karami Z, Rezaeian I, Zahedi P and Abdollahi M. Preparation and performance evaluations of electrospun poly (ϵ -caprolactone), poly (lactic acid), and their hybrid (50/50) nanofibrous mats containing thymol as an herbal drug for effective wound healing. *J. Appl. Polym. Sci* 2013; 129(2): 756-66. doi: 10.1002/app.38683.
38. Tanko Y, Mohammed A, Okasha MA, Umar AH and Magaji RA. Anti-nociceptive and anti-inflammatory activities of ethanol extract of syzygium aromaticum flower bud in Wistar rats and mice. *Afr. J. Tradit. Complement. Altern. Med.* 2008; 5(2): 209-12. doi: 10.4314/ajtcam.v5i2.31275.
39. Fu KY, Light AR and Maixner W. Long-lasting inflammation and long-term hyperalgesia after subcutaneous formalin injection into the rat hindpaw. *J. Pain.* 2001; 2(1): 2-11. doi: 10.1054/jpai.2001.9804.
40. Akhtar MS and Aslam M. Anticestodal principles of *Nigella sativa*, Linn.(Kalonji) seeds. *Pak. J. Pharmacol.* 1997; 14(2): 7-14.
41. Doak GJ and Sawynok J. Formalin-induced nociceptive behavior and edema: involvement of multiple peripheral 5-hydroxytryptamine receptor subtypes. *Neuroscience* 1997; 80(3): 939-49. doi: 10.1016/s0306-4522(97)00066-3.
42. Damas J and Liegeois JF. The inflammatory reaction induced by formalin in the rat paw. *Naunyn. Schmiedeberg's. Arch. Pharmacol.* 1999; 359(3): 220-7. doi: 10.1007/pl00005345.
43. Fahimi S, Abdollahi M, Mortazavi SA, Hajimehdipour H, Abdolghaffari AH and Rezvanfar MA. Wound healing activity of a traditionally used poly herbal product in a burn wound model in rats. *Iran. Red Crescent Med. J.* 2015; 17(9): e19960-e. doi: 10.5812/ircmj.19960.
44. Vakilian K, Atarha M, Bekhradi R and Chaman R. Healing advantages of lavender essential oil during episiotomy recovery: A clinical trial. *Complement. Ther. Clin. Pract.* 2011; 17(1): 50-3. doi: 10.1016/j.ctcp.2010.05.006.
45. Mori HM, Kawanami H, Kawahata H and Aoki M. Wound healing potential of lavender oil by acceleration of granulation and wound contraction through induction of TGF-beta in a rat model. *BMC Complement. Altern. Med.* 2016; 16: 144. doi: 10.1186/s12906-016-1128-7.
46. Rezaei M, Dadgar Z, Noori-Zadeh A, Mesbah-Namin SA, Pakzad I and Davodian E. Evaluation of the antibacterial activity of the *Althaea officinalis* L. leaf extract and its wound healing potency in the rat model of excision wound creation. *Avicenna J. Phytomed.* 2015; 5(2): 105-12.
47. Deters A, Zippel J, Hellenbrand N, Pappai D, Possemeyer C and Hensel A. Aqueous extracts and polysaccharides from marshmallow roots (*Althaea officinalis* L.): cellular internalisation and stimulation of cell physiology of human epithelial cells *in vitro*. *J. Ethnopharmacol.* 2010; 127(1): 62-9. doi: 10.1016/j.jep.2009.09.050.
48. Broussard KC and Powers JG. Wound dressings: selecting the most appropriate type. *Am. J. Clin. Dermatol.* 2013; 14(6): 449-59. doi: 10.1007/s40257-013-0046-4.

49. Bahramsoltani R, Farzaei MH, Abdolghaffari AH, Rahimi R, Samadi N, Heidari M, Esfandyari M, Baeri M, Hassanzadeh G, Abdollahi M and Soltani S. Evaluation of phytochemicals, antioxidant and burn wound healing activities of *Cucurbita moschata* Duchesne fruit peel. *Iran J. Basic Med. Sci.* 2017; 20(7): 798. doi: 10.22038/IJBMS.2017.9015.

How to cite this article: Momtaz S, Abdolghaffari AH, Jasemi E, Yaqoobvand B, Esmailzadeh S, Abdollahi A, Abdollahi M. Evaluation of wound healing and anti-inflammatory activities of a herbal ointment consisting of *Althaea officinalis*, *Lavandula angustifolia*, and *Rosa x damascena* in animal excision wound model. ***Journal of Medicinal Plants*** 2021; 20(77): 37-49. doi: 10.29252/jmp.20.77.37



فصلنامه گیاهان دارویی

Journal homepage: www.jmp.irپژوهشکده گیاهان دارویی
جهاد دانشگاهی

مقاله تحقیقاتی

ارزیابی اثر التیام زخم و فعالیت ضدالتهابی پماد گیاهی حاوی اسطوخودوس، ختمی و گل محمدی در مدل حیوانی زخم برشی

سعیده ممتاز^{۱*}، امیرحسین عبدالغفاری^۲، اقبال جاسمی^۱، بهمن یعقوب‌وند^۱، سعید اسماعیل‌زاده^۱، علیرضا عبدالمهی^۳، محمد عبدالمهی^۴^۱ مرکز تحقیقات گیاهان دارویی، پژوهشکده گیاهان دارویی جهاد دانشگاهی، کرج، ایران^۲ گروه سم‌شناسی و فارماکولوژی، دانشکده داروسازی، علوم پزشکی تهران، دانشگاه آزاد اسلامی، تهران، ایران^۳ گروه پاتولوژی، بیمارستان امام، دانشگاه علوم پزشکی تهران، تهران، ایران^۴ گروه سم‌شناسی و فارماکولوژی، دانشکده داروسازی، دانشگاه علوم پزشکی تهران، تهران، ایران

چکیده

اطلاعات مقاله

گل‌واژگان:

ختمی

اسطوخودوس

گل محمدی

التیام زخم برشی

التهاب

مقدمه: ختمی، اسطوخودوس و گل محمدی برای درمان انواع ضایعات پوستی مانند زخم‌های برشی یا سوختگی در طب سنتی استفاده می‌شوند. **هدف:** بررسی اثر ترمیم‌کنندگی یک پماد چند گیاهی شامل اسانس گل محمدی و اسطوخودوس و عصاره گل ختمی در بهبود زخم ناشی از برش درجه ۳ است. **روش بررسی:** برای ارزیابی اثر ترمیم زخم، فرمولاسیون ترکیبی از اسانس گل محمدی: عصاره گل ختمی: اسانس اسطوخودوس: اوسرین به نسبت ۵۰:۱۰:۲۰:۲۰ تهیه شد. فرمولاسیون با استفاده از آزمون زخم برشی به مدت ۱۴ روز مورد بررسی قرار گرفت و درصد بهبودی در هر گروه محاسبه شد. برای تعیین فعالیت‌های ضد التهابی این فرمولاسیون از روش التهاب القا شده با فرمالین (کف پای موش‌ها) استفاده شد. **نتایج:** اختلاف معنی‌داری بین گروه‌های فرمولاسیون و دارونما در ترمیم زخم وجود داشت. ترمیم اپیتلیال، کاهش التهاب، آنژیوژنز و رسوب کلاژن پیشرفت قابل توجهی داشتند. درصد ترمیم زخم برای گروه‌های فرمولاسیون، اسطوخودوس، گل محمدی، ختمی و سالین $99/07 \pm 0/34$ ، $98/54 \pm 0/733$ ، $99/22 \pm 0/35$ ، $98/54 \pm 0/733$ و $98/54 \pm 0/733$ محاسبه شد. فرمولاسیون در تست التهابی فرمالین نیز نسبت به سایر گروه‌ها خاصیت ضد التهابی بهتری نشان داد. **نتیجه‌گیری:** این فرمولاسیون می‌تواند در بهبود زخم برشی احتمالاً به دلیل سرکوب واسطه‌های التهابی، اثر درمانی داشته باشد. وجود ترکیبات فنلی ممکن است دلیلی برای تأثیر درمانی این گیاهان باشد.

مخفف‌ها: NSAIDs، داروهای ضدالتهاب غیراستروئیدی؛ IgE، ایمونوگلوبولین E؛ COX، سیکلواکسیژناز

* نویسنده مسئول: momtaz@imp.ac.ir

تاریخ دریافت: ۱۷ اسفند ۱۳۹۸؛ تاریخ دریافت اصلاحات: ۶ مهر ۱۳۹۹؛ تاریخ پذیرش: ۱۹ آبان ۱۳۹۹

doi: 10.29252/jmp.20.77.37

© 2020. Open access. This article is distributed under the terms of the Creative Commons Attribution-NonCommercial 4.0 International License (<https://creativecommons.org/licenses/by-nc/4.0/>)