

Study the Effects of Oral Administration of Silymarin in Preventing Consequences of Ethanol on Liver during Pregnancy

Ahmadi-Ashtiani HR (Ph.D. Student)^{1,2,3}, Rezazadeh Sh (Ph.D.)³, Safipourian K* (D.V.M)⁴, Afraz K (M.Sc. Student)⁵, Khaki A (D.V.M, Ph.D.)⁶, Rastegar H (Ph.D.)⁷

1- Department of Clinical Biochemistry, School of Medical Science, Tarbiat Modarres University, Tehran, Iran

2- Biochemistry & Nutrition Department of Zanjan Medical University, Zanjan, Iran

3- Institute of Medicinal Plants, ACECR, Karaj, Iran

4- Young Researcher Club- Islamic Azad University, Karaj Branch, Karaj, Iran

5- Islamic Azad University, Science and Research Branch, Tehran, Iran

6- Department of Veterinary Pathology, Islamic Azad University Tabriz Branch, Tabriz, Iran

7- Ministry of Health and Medical Education, Food & Drug Laboratory Research Center, Tehran, Iran

* Corresponding author: Food & Drug Laboratory Research Center, Imam Khomeini Street, Tehran, Iran

Tel: +982166406174, Fax: +982166404330

Email:mhrastegar@yahoo.com

Receive: 28 Jul. 2010

Acceptance: 20 Sep. 2010

Abstract

Background: Alcoholic mothers who consume ethanol give birth to infants with high percentage of hepatic diseases. Alcohol can cause cellular damage in different tissues, including liver. Finding a drug which is effective and efficient in reducing ethanol misuse consequences during pregnancy can assist the decrease of harmful effects of this habit.

Objective: This research aims to study the effects of oral administration of silymarin in preventing consequences of ethanol on liver during pregnancy.

Methods: 45 female rats were randomly divided into 3 groups, each including 15 ones. After the first day of pregnancy, the study was performed as follows. The first group was given distilled water. The second group received ethanol equivalent to 35% of the total required calorie. Furthermore, the third group received the same amount of ethanol plus 200 mg/kg silymarin. At day 21, biopsy of liver tissue of the born infants was carried out for light microscopy studies.

Results: Findings of the present study indicate that, in the group which received ethanol, this extract can have a considerable effect on decreasing the hepatic cellular death as well as reducing hepatic hyperemia.

Conclusion: Oral consumption of silymarin extract can reduce the damage and inflammation in liver tissue of infants born from alcoholic mothers.

Keywords: Ethanol, Liver tissue, Silymarin, Pregnancy, Rat

Introduction

Alcoholism has assigned the tenth rank of diseases prevalence in Europe [1]. Pregnancy period is one of the most significant and critical periods in a mother's life and the infant to be born. Many mothers who drink alcohol are not aware of consequences of this habit, including hepatic fibrosis and cirrhosis of alcoholic origin, Fetal Alcohol Syndrome (FAS), and intensification of pregnancy celestas [2,3], on themselves and their fetus during pregnancy. Furthermore, not giving information concerning this habit to specialist or hygienic centers before and during pregnancy, due to cultural and social issues or lack of access to facilities, leads to increase of risks caused by alcohol consumption during pregnancy. In this regard, finding an effective drug for decreasing ethanol misuse effects, which can be used reliably during pregnancy even without specialist's prescription and be at the same time inexpensive and available, helps to decrease hygienic, therapeutic, social, and economical problems caused by this habit in societies with different cultures. Additionally, specialists can mention the properties of such compounds in pre-pregnancy consultations. One of the organs with most vulnerability against ethanol consumption is liver. In addition, during pregnancy period even in normal conditions liver is vulnerable due to biochemical and physiological changes [4]; so if this organ is damaged during pregnancy period, health of both mother and fetus will be endangered. Acute or chronic hepatic toxicity caused by alcohol is mainly resulted from production of free radicals [5, 6]. On the other hand, antioxidant [6] and liver protection properties of silymarin against ethanol misuse effects are established and its use during pregnancy period has no risk for mother and fetus [7, 8]. Also, silymarin is capable of

passing placenta and can prevent weight loss of fetus caused by drinking alcohol during pregnancy [9]. Hence in this study we have investigated on animal's model the effect of silymarin on reducing hepatic damage caused by ethanol consumption during pregnancy period.

Materials and Methods

For this study, 45 female rats were purchased from Pasteur Institute, Iran, with almost the same age and weight of 140-160 g [10]. They were randomly divided into 3 groups each including 15 ones, and each 3 rats were put in a cage. To be adopted with the new environment, cages were put for 14 days in the same environmental (22-26°C, relative humidity of 40-60%, and 12 / 12 h light-cycle) and nutrition conditions [10 - 16]. After this period, sibling male rat was kept in the same cage with female rats. After observation of vaginal plug in female rats, the male rat was taken out from the cage and it was considered as embryonic day 0 (E0). This day was the beginning of study on groups as follows. Every day at one time, the first group as control received distilled water by gavages. The second group daily received ethanol (Merck) by gavages equivalent to 35% of their total required calorie. Finally, the third group daily received ethanol (Merck) equivalent to 35% of their total required calorie as well as 200 mg/kg silymarin (Darupakhsh Company). In order to assure that they have received the total prescribed silymarin dose, initially the pallets containing silymarin were made available to rats and after its consumption, their normal ration was given to them [17]. To evaluate the hepatic damages in each group, biopsy of infants' liver tissue was performed at day 21 of pregnancy [18].

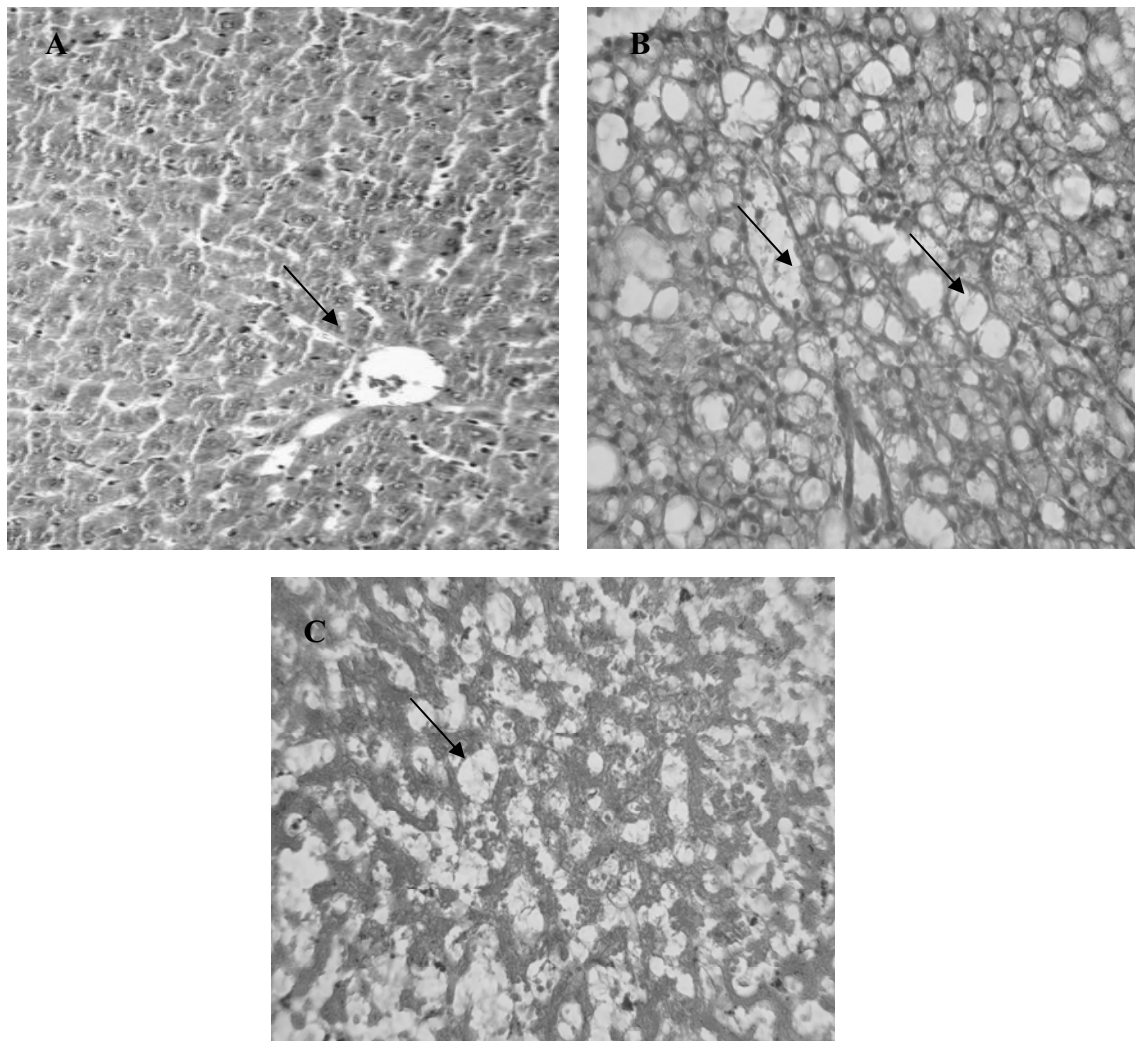


Tissue Preparation Steps for Light Microscopy Study

At day 21 of pregnancy, samples of infants' liver tissue were fixed in formalin 10% buffer solution and after preparation of slices with thickness of 5 μm ; they were stained with hematoxylin and eosin. To prepare images, ASA 400 Kodak Ultra film and light microscope (model: Olympus/ 3H – Z, Japan) were used [10].

Results

The created damages lead to hyperemia of hepatic lobule veins, increase of dilative cells around liver sinusoids, hyperemia of hepatic tissue, stretch of disse space, and death of hepatic cells in all groups which received alcohol (Photomicrograph A). Consumption of the extract had no positive effect on decrease of hyperemia and stretch of disse space in liver tissues of the animals born from alcoholic mothers (Photomicrographs B and C).



Photomicrograph A - Liver tissue, disse space, and normal hepatic cells (arrow) in control group which received distilled water; X160 (H&E)

Photomicrographs B and C- Degeneration of liver tissue, replacement of lipid tissue, and death of hepatic cells (arrow) in the group which received alcohol; X160 (H&E)

Discussion

By regulating blood sugar through glycogenesis and glycogenolysis, liver plays a significant role in metabolism of carbohydrates, such that by disturbance in liver's function the Glucose metabolic homeostasis is disturbed [2, 3]. Hepatic damages and diseases include interference in metabolism of lipids, carbohydrates, and proteins, and result in an increase in risk of vascular diseases [3]. Increase of oxidative stress and change in dose of antioxidants plays an essential role in pathogenesis of hepatic diseases [4-6]. In the absence of efficient chemical drugs, medicinal herbs have an important position [12] since they cause less side-effects especially during pregnancy besides being available and inexpensive. Studies have indicated that damages to liver tissue and programmed death are caused by reactive oxygen species (ROS). As an antioxidant factor, flavonoids are found in foods such as fruits, vegetables, tea, and black grapes [20].

Drinking alcohol is among causes of hepatic failure [21]. Alcoholic liver disease which is among the problems for general health [22] is the result of long-term alcohol consumption in great amounts and is accompanied by changes in liver enzymes such as AST, ALT, and ALP, as well as Bilirubin, protein, albumin, and triglyceride [23]. On the other hand, pregnancy period is one of the most significant and critical periods in the lives of both mother and fetus. Ethanol consumption during pregnancy intensifies hepatic diseases [2]. Considering the harmfulness of alcohol consumption and its resultant hepatic diseases, high costs imposed to society by such diseases, and the point that some alcohol drinkers insist on their alcohol consumption even during pregnancy, it is of high significance to find a drug for prevention,

treatment, or decreasing the resulting damages [26]. Silymarin is a flavonoid derived from milk thistle [23] which has been used for treatment of different types of hepatic diseases [24] including the one caused by alcohol [17, 25]. Silymarin has no serious negative effect for fetus and mother during pregnancy [7]. Silymarin is also well tolerated at high doses by pregnant mother. For instance, it has been used by mothers suffering from intrahepatic cholestasis with a dose of 560 mg/day for 16 days and no toxicity has been reported for mother and fetus [27]. In spite of its ability to pass placenta [9], silymarin has no toxic effect on fetus [8] and can prevent weight loss of fetus caused by alcohol consumption during pregnancy period [9]. Considering the significance of liver's health during pregnancy as well as the raised risk for this organ in mother who drink alcohol, in the present study the effect of silymarin was therefore evaluated on the consequences of alcohol consumption in liver during pregnancy on rat.

In this research, the goal was to study the effects of silymarin on consequences caused by ethanol consumption during pregnancy period on born infants. Hence, study was initiated immediately after end of pregnancy, and considering the day 21st of pregnancy in rats to be the day infants are born, damage to infant's liver was determined at this day. Alcohol consumption is one of the reasons of liver failure. Alcoholic liver disease is caused by long-term alcohol consumption in great amounts. This disease includes alcoholic fatty liver, alcoholic hepatitis, and hepatic cirrhosis which has remained among problems of general health. Studies show that short-term and long-term alcohol consumption lead to a change in status of oxidation and reduction, damage to mitochondria, membrane damage, hypoxia caused by ethanol, increase in level of



endotoxin, and activation of Kupfer cells. Chronic use of cassia in human has been reported to cause cholestatic hepatitis. Also, it has been reported that chronic use of medical herbs including cassia results in veno-occlusive hepatitis and cholestatic hepatitis. Indeed, long-term alcohol consumption can lead to pathologic changes in liver, including causing alcoholic fatty liver. Accumulation of macrovesicular and triglyceride lipids in liver of wild-type Syrian mice observed after 4 weeks of alcohol consumption is evidence of this phenomenon. Studies have indicated that long-term alcohol consumption increases hepatitis which is characterized by infiltration of neutrophil cells (polymorphonuclear cells), enhancement of the hepatic keratin chemo-attractant, and increase in level of monocyte protein-1 chemo-attractant, which is in accordance with the present research. Furthermore, apoptosis of hepatic cells has been observed in alcoholic liver disease both in clinical and experimental studies. There have been reports stating that long-term alcohol consumption causes inflammation. This phenomenon results in more serious damages called hepatic fibrosis and cirrhosis. Employing neutrophil and activation of Kupfer cells is an intermediate for observation of inflammatory response, which is in agreement

with our study (Photomicrographs B and C). Another issue to be noted is that most drugs must be administered in a long-term manner in order for their useful effects to be reached; the present study nonetheless indicated that protective effects of silymarin appear from the first day of its use. This is of much importance in alcohol's effect on fetus, since many mothers are unaware of their pregnancy during the initial weeks of their pregnancy; so if the appearance of drug's therapeutic effects requires long time, useful effects of drug will not be expressed at initial months of pregnancy which are very critical for growth and development of fetus [32 - 37]. According to obtained results, better results can be reached using higher doses of silymarin which have been proved to have no risk for mother and fetus. Also in further experiments the minimum effective dose can be studied for maximum protective effect, as well as the maximum dose which has no risk for mother and fetus. Despite the acquired results, due to fetus sensitivity and serious effects of drugs on physical and behavioral development of children in future, further in-depth studies on all organs and prospective studies on born infants are necessary to confirm that this drug has no risk for pregnancy.

References

1. Saller R, Meier R, Brignoli R. The Use of Silymarin in the Treatment of Liver Diseases. *Drugs* 2001; 61 (14): 2035 - 63.
2. Trauner M, Boyer JL. Cholestatic syndromes. *Current Opinion in Gastroenterol.* 2002; 18 (3): 314 – 29.
3. Perez MJ, Castano B, Gonzalez- Buitrago JM, Marin Jose JG. Multiple protective effects of melatonin against maternal cholestasis-induced oxidative stress and apoptosis in the rat fetal liver-placenta-maternal liver trio. *J. Pineal Res.* 2007; 43 (2): 130 - 9.
4. Khaki A, Nouri M, Fathiazad F, Ahmadi-Ashtiani HR, Rastgar H, Rezazadeh Sh. Protective Effects of Quercetin on Spermatogenesis in Streptozotocin-induced Diabetic Rat. *J. Medicinal Plants* 2009; (8) 4: 57 – 64.

5. Khaki AA, Khaki A, Nouri M, Ahmadi-Ashtiani HR, Rastegar H, Rezazadeh Sh, Fathiazad F, Ghanbari M. Evaluation Effects of Quercetin on Liver Apoptosis in Streptozotocin-induced Diabetic Rat. *Iranian journal of medical plants*. 2009; (8) 4: 70 - 8.
6. Nouri M, Khaki A, Fathi Azad F, Rashidi MR. The Protective Effects of Carrot Seed Extract on Spermatogenesis and Cauda Epididymal Sperm Reserves in Gentamicin Treated Rats. *Yakhteh Medical J*. 2009; 11 (3): 327 - 33.
7. Fraschini F, Demartini G, Esposti D. Pharmacology of silymarin. *Clin Drug Invest* 2002; 22: 51 - 65.
8. Hernández R, Nazar E. Effect of silymarin in intrahepatic cholestasis of pregnancy (preliminary communication). *Rev. Chil. Obstet Ginecol*. 1982; 47 (1): 22 - 9.
9. LaGrange L, Wang M, Watkins R, Ortiz D, Sanchez ME, Konst J, Lee C, Reyes E. Protective effects of the flavanoid mixture, silymarin, on fetal rat brain and liver. *J. Ethno. Pharmacol*. 1988; 65 (1): 53 - 61.
10. Saravanan R, Viswanathan P, Viswanathan Pugalandi K. Protective effect of ursolic acid on ethanol-mediated experimental liver damage in rats. *Life Sci*. 2006; 78 (7): 713 - 8.
11. Pramyothin P, Samosorn P, Pongshompoo S, Chaichantipyuth C. The protective effects of *Phyllanthus emblica* Linn. Extract on ethanol induced rat hepatic injury. *J. Ethnopharmacol*. 2006; 107 (3): 361 - 4.
12. Lu Z, Tao W, Zou X, Fu H, Ao Z. Protective effects of mycelia of *Antrodia camphorate* and *Amilleriella tabescens* in submerged culture against ethanol-induced hepatic toxicity in rats. *J. Ethnopharmacol*. 2007; 11 (1); 160 - 4.
13. Mitchell JA, Van Kainen BR. Effect of alcohol on intra uterine oxygen tension in the rat. *Alcoholism: Clinical and Experimental Res*. 1992; 16 (2): 308 - 10.
14. Ledig M, Holownia A, Copin J, Tholey G, Anokhina I. Development of glial cells cultured from prenatally alcohol treated rat brain: effect of supplementation of the maternal alcohol diet with a grape extract. *Neurochemical Res*. 1996; 21 (3): 313 - 17.
15. Ertem K, Kekilli E, Elmali N, Celan F. The effects of alcohol exposure during intrauterine and postnatal period on bone mineral density and bone growth and body weight in rat's virgin offspring. *Eur. J. Gen. Med*. 3 (2): 54 - 7.
16. Vengeliene V, Seimund Soren, Singer MV, Sinclair JD, Li T, Spanagel R. A comparative study on alcohol-preferring rat lines: Effects of deprivation and stress phases on voluntary alcohol intake. *Alcoholism: Clinical and Experimental Res*. 2003; 27 (7): 1048 - 54.
17. Song Z, Deaciuc I, Song M, YW. Lee D, Liu Y, Ji X, McClain C. Silymarin Protects Against Acute Ethanol-Induced Hepatotoxicity in Mice. *Alcoholism: Clinical and Experimental Res*. 2006; 30 (3): 407 - 13.
18. Kelly J, Meehan SH, Colvin RB, Williams JR, Bonventre J. Protection from toxicant-mediated renal injury in the rat with anti-CD54 antibody. *Kidney International* 1999; 56: 922 - 931.
19. Murillo-Fuentes L, Artillo R, Carreras O, Murillo L. Effects of maternal chronic alcohol administration in the rat: lactation performance

- and pup's growth. *Eur. J. Nutr.* 2001; 40 (4): 147 - 54.
- 20.** Khaki A. Protective effect of quercetin against necrosis and apoptosis induced by experimental ischemia and reperfusion in rat liver. *AJPP.* 2010, 4 (1):022 - 026.
- 21.** Matthews GV, Nelson MR. The management of chronic hepatitis B infection. *Int. J. STD AIDS* 2001; 1 (2): 353 - 7.
- 22.** Diehl AM. Liver disease in alcohol abusers: clinical perspective. *Alcohol* 2002; 27 (1): 7 - 11.
- 23.** Conti M, Malandrino S, Magistretti MJ. Protective activity of silipide on liver damage in rodents. *Japan. J. Pharmacol.* 1992; 315 - 21.
- 24.** Salmi HA, Sarna S. Effect of silymarin on chemical, functional, and morphological alterations of the liver. *Scand J. Gastroenterol.* 1982; 17 (4): 517 - 21.
- 25.** Das SK, Vasudevan DM. Protective effects of silymarin, a milk thistle (*Silybium marianum*) derivative on ethanol-induced oxidative stress in liver. *Indian J. Biochem. Biophys.* 2006; 43 (5): 306 - 11.
- 26.** Burd L, Martsolf JT, Juelson T. Fetal alcohol spectrum disorder in the corrections system: potential screening strategies. *J. FAS. Int.* 2004; 2.
- 27.** Giannola C, Buogo F, Forestiere G, Scaffidi L, Ferrigno V, Scaffidi A. A two-center study on the effects of silymarin in pregnant women and adult patients with so-called minor hepatic insufficiency. *Clin Ter.* 1985; 114: 129 - 35.
- 28.** Lieber CS. Biochemical factors in alcoholic liver disease. *Semin Liver Dis.* 1993; 1 (3): 136 - 53.
- 29.** Apte MV, Phillips PA, Fahmy RG, et al. Does alcohol directly stimulate pancreatic fibrogenesis? Studies with rat pancreatic stellate cells. *Gastroenterol.* 2000; 11 (8): 780 - 94.
- 30.** Arteel GE. Oxidants and antioxidants in alcohol-induced liver disease. *Gastroenterol.* 2003; 12 (4): 778 - 90.
- 31.** Masini A, Ceccarelli D, Galléis D, Giovannini D, Trenti. Lipid hydroperoxide induced mitochondrial dysfunction following acute ethanol intoxication in rats. The critical role for mitochondrial reduced glutathione. *Biochem. Pharmacol.* 1994; 4 (7): 217 - 24.
- 32.** Song Z, Zhou Z, Chen T, Hill D, Kang J, Barve S, McClain C. S-adenosylmethionine (SAME) protects against acute alcohol induced hepatotoxicity in mice small star, filled. *J. Nutr. Biochem.* 2003; 1 (4): 591 - 7.
- 33.** Jos F. Van Pelt, Chris Verslype, Tina Crabbé, Zahur Zaman, Johan Fevery. Primary human hepatocytes are protected against prolonged and repeated exposure to ethanol Silibin-Dihemisuccinate. *Alcohol and Alcoholism* 2003; 38 (5): 411 - 4.
- 34.** Song Z, Deaciuc I, Song M, Lee DY, Liu Y, Ji X, McClain C. Silymarin protects against acute ethanol-induced hepatotoxicity in mice. *Alcohol Clin. Exp. Res.* 2006; 30 (3): 407 - 13.
- 35.** Muzes G, Deak G, Lang I, et al. Silymarin (Legalon) kezeles hatasa idult alkoholos majbetegek antioxidans vedorendszerere es a lipid peroxidacióra (kettos vak protokoll). *Orv Hetil.* 1990; 13 (1): 863 - 6.
- 36.** Kasper L, Braunwald J, Fauci H. Icter. Disorders of gastrointestinal system. Harrison's principles of Internal medicine. 16th edition. 2005.

37. Andreoli, Griges, Carpenter, Loscalzo. Essentials on Medicine. 6th Edition. 2007
Laboratory tests in liver disease, Icter. Cecil

