

Study the Effect of Silymarin and Vitamin C in Skin Aging Induced by UVB Rays on the Mice Skin Redox System

Ahmadi Ashtiani HR (Ph.D.)^{1,2*}, Rastegar H (Ph.D.)^{2,3,4}, Salarian AA (Ph.D.)⁵, Rahmani F (Pharm.D.)¹, Rezazadeh Sh (Ph.D.)⁶, Sedghi Zadeh H (Ph.D.)⁷

1- Department of Basic Sciences, Faculty of Pharmacy, Tehran Medical Sciences, Islamic Azad University, Tehran, Iran

2- Cosmetic, Hygienic and Detergent Sciences and Technology Research Center, Tehran Medical Sciences, Islamic Azad University, Tehran, Iran

3- Cosmetic Products Research Center, Tehran, Iran

4- Department of Basic Sciences, Faculty of Pharmacy, Tehran Medical Sciences, Islamic Azad University, Tehran, Iran

5- Assistant Professor of Toxin Research Center, AJA University of Medical Science, Tehran, Iran

6- Medicinal Plants Research Center, Institute of Medicinal Plants, ACECR, Karaj, Iran

7- Professor of Pharmacy Department of Life Sciences and Biotechnologies, University of Ferrara, Italy

* Corresponding author: Department of Basic Sciences, Faculty of Pharmacy, Tehran Medical Sciences, Islamic Azad University, Tehran, Iran.

Cosmetic, Hygienic and Detergent Sciences and Technology Research Center, Tehran Medical Sciences, Islamic Azad University, Tehran, Iran.

Tel: +98-9128055497, Fax: +98-21-22954828

Email: ahmadi@iaups.ac.ir

Received: 30 Jan. 2019

Accepted: 24 July 2019

doi: 10.29252/jmp.3.71.130

Abstract

Background: Exposure of the skin against occupational hazards is growing every day. Many scientists are trying to identify aspects about the mechanisms of damages done to the skin by them. The skin is the second metabolism organ of the body where redox-dependent metabolic pathways overcome. By considering the UV index, Iranians are at high risk of UVB damage by generation of reactive oxygen species (ROS) that leads to skin aging.

Objective: In this study, we discuss the effects of the UVB rays on redox system; evaluate and compare the protective role of Silymarin and Vitamin C against UVB-induced skin aging.

Method: Male Balb/C mice were divided into 6 groups of 6 mices: Silymarin, Vitamin C, Control, UVB exposed, UVB exposed treated with Silymarin and UVB exposed treated with Vitamin C. The inhibitory effect of Silymarin and Vitamin C for skin aging were determined by wrinkle formation, epidermal thickness and dermal inflammation. The anti-photo aging effects of Silymarin and Vitamin C have been assessed by SOD, GSH, GSH_PX and TAC kits.

Results: The flake in UVB irradiated groups was significantly different ($P < 0.05$). The mean length of the wrinkle in UVB irradiated group very significantly increased ($P < 0.01$) and the collagen reduction, increased in very high significant different in aged control group ($P < 0.001$). The mean TAC in VitaminC group increased very significantly high. ($P < 0.0001$)

Conclusion: The results indicate that the Silymarin and Vitamin C have anti-photo aging effects suggested to use in anti-wrinkle, anti erythematosus, anti-inflammatory topical cosmetics products.

Keywords: Redox, Silymarin, Skin aging, Ultraviolet B (UVB), Vitamin C

Abbreviations: ROS (reactive oxygen species), GSH (glutathione), TAC (total antioxidant capacity), SOD (super oxide dismutase), GSH_PX (glutathione peroxidase), UV (ultraviolet ray)



Introduction

One of the major signs of aging is skin aging [1]. The demonstration of aging appears in skin aging by increasing in wrinkling, sagging, and increased laxity of the skin [2]. Aging is a complex process influenced by both extrinsic and intrinsic factors [23] where they lead to the structural integrity and loss of physiological function [4]. Two major extrinsic factors are smoking and UV radiation [5]. As we know in chemical terminology every compound accepting electrons is an accident or oxidizing agent, like oxygen and in contrast a substance donating electrons is a reduction or reducing [6, 7]. The oxygen free radicals are known to scientists long ago. They can do different things from physiological regulatory functions to damaging the tissues [8]. Oxidative stress is the reason of the redox imbalance where it harms several tissues like skin. The ROS species are mostly production of mitochondrial electron transport chain. They are very reactive molecules that also can be the byproduct of some other chemical reactions like NAD (P) H oxidase and nitric oxide synthase [8, 9]. About 1.5 - 5 % of the consumed oxygen is converted into ROS by intrinsic procedures [10]. Reactive oxygen species generated as side products in the electron transport chain of the aerobic metabolism in the mitochondria known as a main intrinsic aging factor. Due to the nature of ROS species microorganisms must have Hemostasis under regulation by anti-oxidants system which contains glutathione (GSH), glutathione peroxidase (GSH_PX), super oxide dismutase (SOD), total antioxidant capacity (TAC) and low molecular weight anti-oxidants [11, 12]. The chronic redox imbalance is the

result of alterations in antioxidant mediator's activities which are existing in cell membranes and organelles and environment, it can lead to many diseases.

Like cancer, inflammation, neurodegenerative diseases, ischemia, natural aging, and many other conditions. Another example of redox imbalance is increasing in antioxidant in chronic wound fluid among to Edina [13]. Exposure to UV radiation is the primary factor of extrinsic skin aging also referred as to photo aging. The degeneration of the skin from UV radiation is a cumulative process and the rate of degeneration depends on the frequency, duration and intensity of solar exposure and the natural protection by skin pigmentation [14]. The melanin produced by melanocytes mostly accumulates in keratinocytes an acting as a natural sunscreen which protects the skin from UV rays, the melanin also has other functions either as regulatory effects on epidermal homeostasis and radical scavenging against oxidative stress [1, 15-21]. Sunlight induces photo aged skin that is recognized by rough wrinkles, depigmentation and telangiectasias [22, 23]. Sunlight is consisting of the persistent spectrum of electromagnetic waves that is divided into three main wavelengths; ultraviolet, visible and infrared. The range of UV radiation includes 200 to 400 NM wavelengths and for the visible light it Contains 400-700 nm. The additional divide of UV classifies the radiation into three sections which has different biological effects; UVA (320-400 nm) UVB (280-320 nm), and UVC (200-280 nm). The ozone layer obstacle the UVC from reaching the earth's surface, however accidental exposure can happen, like

germicidal lamps. UVA & UVB radiation reach in adequate amounts and have significant biological outcomes to the skin and the eyes. Absorbance of UVB by the skin appears as erythema and burn and will lead to skin cancer [24, 25]. UVA is efficient at production of reactive oxygen species which can do damage to DNA via indirect photosensitizing reactions. Molecular reformation which causes by absorption of UVB in DNA produces specific photo products such as cyclobutane dimers and 6–4 photoproducts [26]. Silymarin as a good antioxidant is a flavonoid that is a production of fruits and seeds of the milk thistle (*Silybum marianum* L. Gaertn.) Extraction [27, 28]. This flavonolignan is a mixture of three flavonoids: silybin (silibinin- major and active component), silydianin and silychristin [29–31]. Silymarin is a safe plant for treatment of diseases that isn't toxic even at higher physiological doses [32]. It also decreases the level of COX-2 that relates to carcinogenesis [33]. minimum effective dose of this plant can be used for maximum protective effect [34]. Oral administration of Silymarin inhibits inflammation and apoptosis of epidermis that leads to skin aging against UVB radiation; so it has a protective role in skin aging [35]. Vitamin C (Ascorbic acid) is a potent antioxidant that is derived from glucose via the uronic acid pathway. As a supplement it improves protection of the skin against sun damage [36]. The aim of the present study was to evaluate the protective role of Silymarin and Vitamin C against UVB induced skin aging in hairless mice.

Materials and Methods

Materials and reagents

Silymarin was purchased from EPO Istituto Farmochimico Fitoterapico S.r.l (Stadera 19 - 20141 Milano). Water soluble Vitamin C was purchased from Merck Bio-Chem Technology. Redox kits including ROS, SOD, TAC, GSH and GSH-PX kits were purchased from ZellBio GmbH (Germany). PHILIPS ULTRAVIOLET_B (UVB) lamps (220V_20W) were purchased from PHILIPS Company.

Animals and Treatment:

Six-week-old, male, Balb/c mice, weighed about 30 ± 2 g, were obtained and housed in a controlled room ($25 \pm 2^\circ\text{C}$, 60% relative humidity, 12h light/dark cycle) with free access to water and standard laboratory diet without antibiotic. After an adaptation period (2 weeks) and any detection of abnormality, mice were randomly divided into 5 groups of 6 animals:

1. Silymarin control: gavage of 100 mg/kg. day for 4 weeks according to the previous study [37].
2. Vitamin C (Vit C) control: gavage of 40 mg/kg. day for 4 weeks according to previous study [38].
3. UVB exposed: exposed to UVB lamp $180\text{mj-}45\text{min}/\text{cm}^2$. day in a special dark room for 30 days according to previous study [39].
4. UVB exposed treated with Silymarin: exposed to UVB lamp $180\text{mj-}45\text{min}/\text{cm}^2$. day in a special dark room for 30 days followed by 100 mg/kg. day Silymarin gavage every day.



5. UVB exposed treated with Vit C: exposed to UVB lamp 180mj-45min/cm². day for 30 days in the special dark room, followed by 40 mg/kg. day Vit C gavage every day.

6. Control: Aged 18-month old mice.

According to a study on the dosage of UVB; it didn't cause any skin carcinogen up to 300mj/cm².

After the 4 weeks and hair removal (no inflammation) all animals euthanized by overdosing of xylazine-ketamine in a ratio of 3/1. Dorsal skin cultures and blood samples were purchased immediately

H&E and Masson stain

The Skins were fixed in 10% formalin 48h at room temperature and paraffin embedded afterwards. With H&E staining, skins were sliced into 4µm, dehydration of gradient ethanol and stained with hematoxylin and eosin.

Measurement of oxidative stress level

Serum samples were prepared after the centrifuge at 2000-3000 rpm. The levels of ROS, TAC, GSH, SOD and GSH-PX (GPx) in serum were detected with relative kits as reference. Serum TAC was measured using a commercial kit following the manufacturer's protocol (ZellBio GmbH, Germany) on the basis of the oxidation. Measurement of serum GSH level was done with commercial chemical colorimetric assay kits (ZellBio GmbH, Ulm, Germany) using calorimetrically method at 412 nm. reduction colorimetric assay at a wavelength of 490 nm [40]. The kit method was based on the fact that SOD enzyme uses superoxide anion as substrate for conversion to hydrogen peroxide and oxygen; which is

measured at 420 nm. Glutathione peroxidase (GPx) activity was assayed by using a commercial kit (ZellBio GmbH, Germany) based on the oxidation reaction of glutathione (GSH) [41].

Statistical analysis

All values are represented as means \pm standard error (SE). Analysis of data was made by Shapiro-Wilk, Kolmogorov Smirnova, and ANOVA. Variance using the Tukey test was used to analyze the differences in the results; a $P < 0.05$ was considered significant.

Results

Clinical observation

Silymarin and Vitamin C decreased flake, wrinkle, erythema, edema and darkness levels.

Histopathological observation

Pearl creatinine, visiclean epidermis, per folliculitis, epidermal necrosis and intra filtrating lymphocytes sebaceous gland have not seen in groups. The wrinkle has not seen in Silymarin, Vitamin C and UVB-treated with Vitamin C groups.

Serological observation

The maximum mean of SOD level has been detected in UVB exposed group.

The maximum mean of GSH level has been detected in Vitamin C treatment group that proves the antioxidant effect of this Vitamin.

The maximum mean of GSH_PX level has been detected in Silymarin treatment group that proves the antioxidant effect of this plant.

The maximum mean of TAC level has been detected in Vitamin C treatment group that proves the high antioxidant effect of this Vitamin.

Discussion

One of the most effects of UVB exposure is skin aging [42]. Food supplements have an important role in protection of skin against UVB damage [43]. Increase of ROS that induced by UVB can be induced oxidative stress in cells balanced by cellular antioxidant reactions such as GSH detoxification [43-45]. No effective drug has been discovered to reduce the speed of human aging. Abnormal body metabolism in the elderly produces free radicals that can be reduced by antioxidant components in plants and vitamins [46, 47]. Iran with an ancient civilization has deep experience to use plants in cosmetic science. It's correct that regional condition in Iran pushed them to use the plant which grows in the mountains, desert or near the seas. Silymarin can grow there easily to use in skin protecting products. The photo aging and reduce wrinkles, dryness; it can also stimulate the proliferation of human keratinocytes, induce skin moisture [33-35]. Silymarin has a protective effect on cells against H₂O₂ as an antiaging effect [48] and increases total antioxidant capacity of cell extract [49]. Topical usage of Silymarin has protective effects against the ultraviolet ray on the skin [37]. In this study, we used male mice to assess the therapeutic effect of Silymarin extract and Vitamin C on photo aging, without considering factors such as hormone induced wrinkling of skin. The activity of antioxidant enzymes such as SOD, TAC, GSH, and GSH_PX against of free radicals decreases in aging [49]. Enhance of antioxidant activity is an effective way to delay skin aging [50]. As the nutrition plays a fundamental role, protecting the body from oxidative species in the body, we

suggest that using of plants as beneficial nutritional approach.

Clinical observation

Evaluation of observation divided in 2 parts; personal observation & photography analyzing. Clinical Observations demonstrated that in the control group which treated with UV radiation wrinkle were increased, in comparison with normal group.

In continuing the UVB groups were treated with Silymarin and Vit C wrinkle was decreased. Also about the erythema we demonstrated the increase in UVB control group and decrease in UVB groups that have treated with Silymarin or Vit C in comparison to normal group.

All the dates were demonstrated in Figure 1d

Silymarin and Vitamin C wrinkle as compared to control group:

Evaluation with photography analyzing was done. The macroscopic wrinkle formation was observed in the dorsal skin of vehicle-treated UVB-irradiated mice in comparison to normal group; however, the oral administration of Silymarin extract or Vit C to UVB irradiated groups reduced wrinkle formation. To further evaluate the inhibitory activity of Silymarin extract and Vit C on wrinkles, replicas of the dorsal skin of the mice (Fig. 1b) were analyzed using an image J analysis system to quantify the rippling surface of the skin. The wrinkles in the UVB-treated vehicle group was significantly increased, as compared to the unexposed control group (Fig. 1a, b, c).

Comparison of personal clinical observations:

The personal observation demonstrates that Silymarine and Vit C reduced level of

erythema, wrinkle, flake, edema and darkness in comparison to control group (Fig e-i).

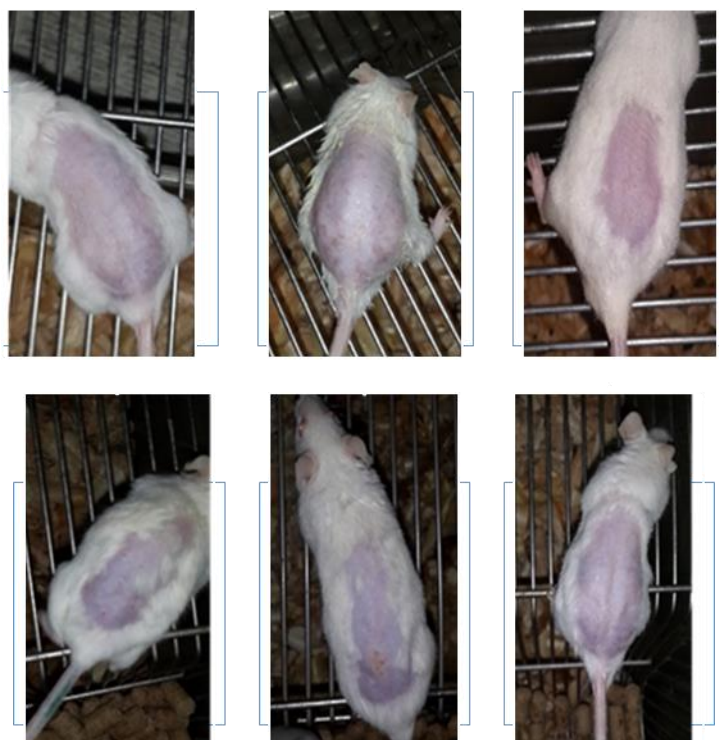


Figure 1a




Figure 1b

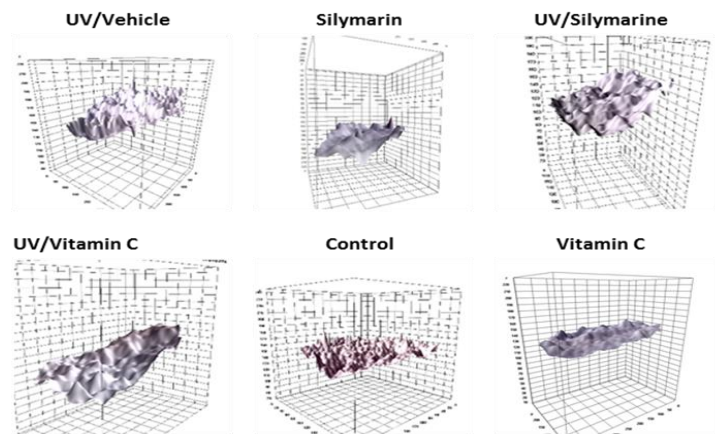


Figure 1c

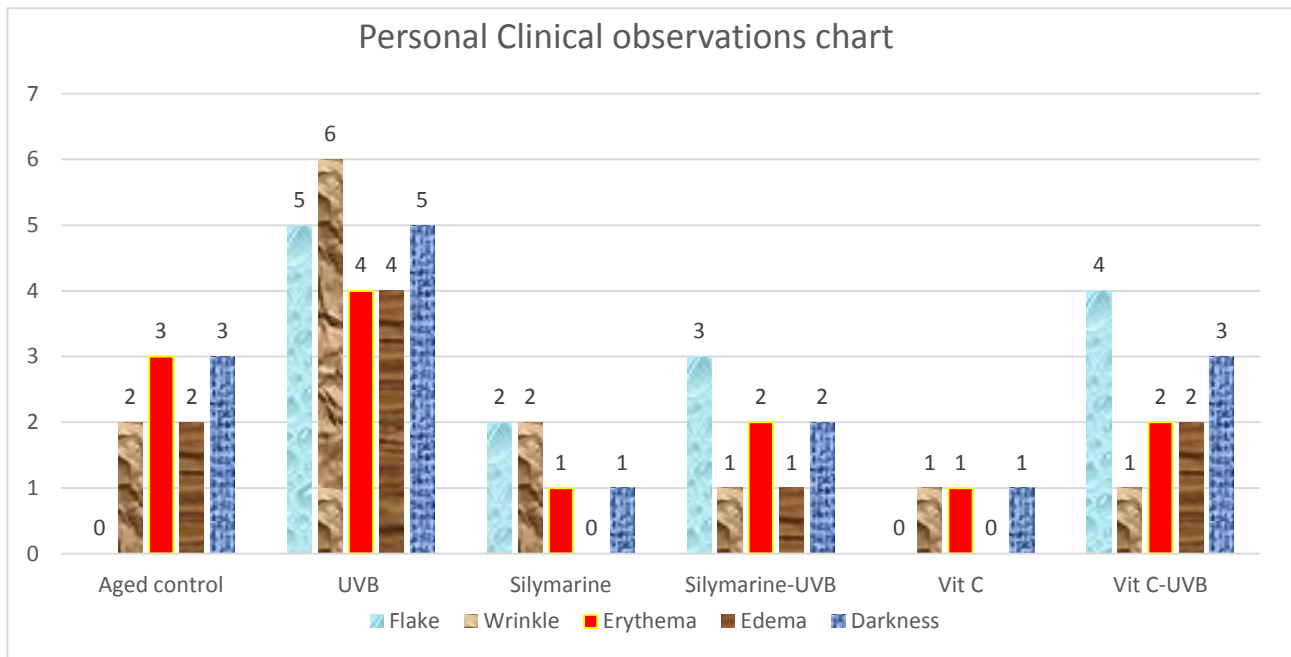


Figure 1d

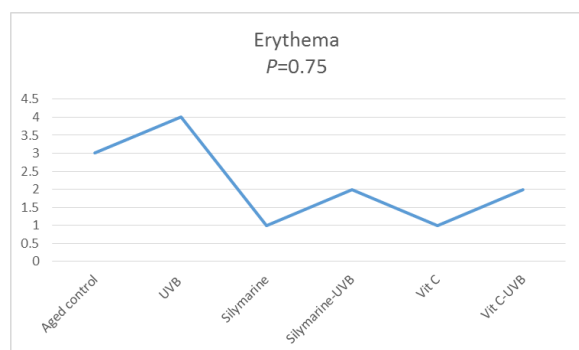


Figure 1e

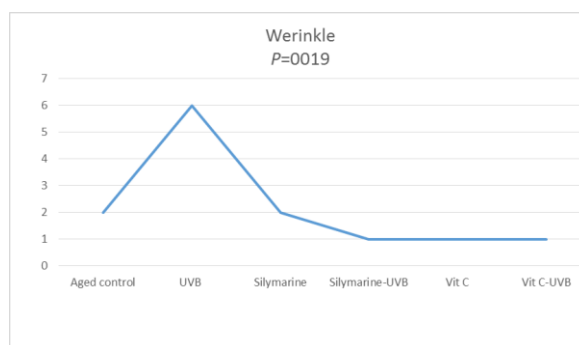


Figure 1f

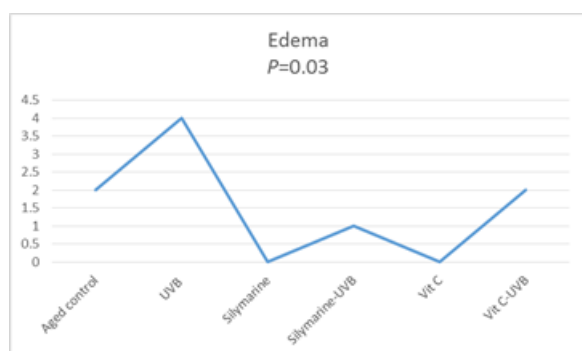


Figure 1h

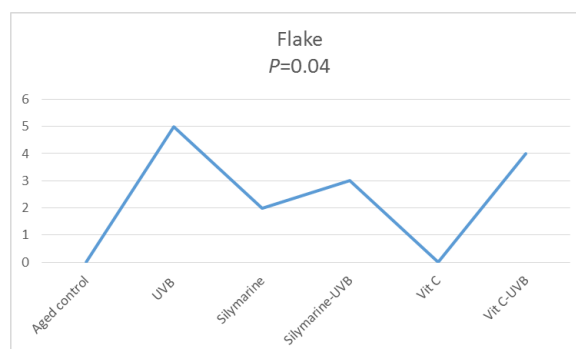


Figure 1g

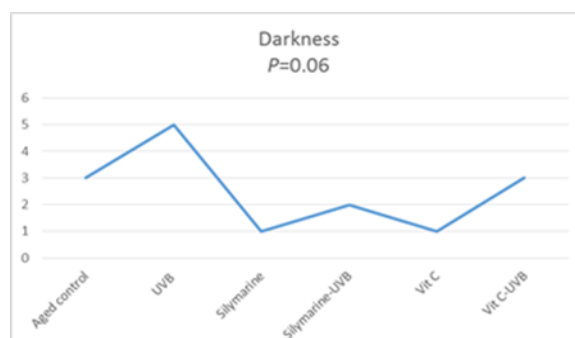


Figure 1i

Figure 1- Effects of Silymarin extract on UVB-induced wrinkle formation in hairless mice (a). Features of the dorsal skin of hairless mice were recorded and images of the backs of the mice. Replica images were taken from the dorsal skin of hairless mice after UVB-irradiation and treatments. (b & c) Analysis of the replicas for the effects of Silymarin extract and Vitamin C on UVB-induced rippling surface of the skin compared to control and vehicle groups. Comparison of personal clinical observation among the six groups (d). The separate comparison of personal clinical observations among groups is showed among (e-i).

Histopathological observation

Silymarin and Vitamin C inhibited the Increase in epidermal thickness and dermal inflammation

One of the most features in skin aging and inflammation is epidermal thickness. Therefore, we measured the effect of Silymarin extract and Vitamin C on changes in UVB-irradiated hairless mice. The epidermal thickness of the dorsal skin significantly increased after UVB irradiation group in comparison to normal group; however, Silymarin extract or Vitamin C gavage to UVB irradiated group inhibited the increase in epidermal thickness. (Fig. 2a) Also the wrinkle in UVB irradiated group increased in comparison to the normal group, but it decreased in UVB groups that have treated with Silymarin or Vit C in comparison to normal group. Collagen reduction decreased in Silymarine and Vit C treated group in comparison to control group. All the other data were demonstrated in figure (Fig. 2b&c).

Serological observation

As we mentioned to the role of UVB ray ROS increase induction; it can cause cellular damage by apoptosis. UVB. NF-kB as a redox-regulated transcription factor has some biological effects such as regulation of gene expression leading to the role of ROS as second-messenger molecules in signaling pathways [37]. So SOD, GSH, GSH-PX get into action in intramembrane space of cell into this pathway; SOD catalysis $O_2^{\circ-}$ into H_2O_2 and GPX catalysis the H_2O_2 into H_2O or non-harmful alcohols. GSH-PX is consist of GSH-GSH that can give two hydrogens to H_2O_2 ;

therefore, we have two H_2O molecules and GSSG which gets into GSH-PX by glutathione reductase. Total anti-oxidant capacity (TAC) increases by anti-oxidants such as Silymarin and Vitamin C and scavenges the free radicals hence the level of TAC will decrease (Figure 3).

- After calculating the mean activity of the enzyme in groups for doing parametric tests the Shapiro Wilk test was done. The results showed normal distribution of SOD & GSH-PX enzymes; but the $P < 0.0001$ was considered for TAC in treating with Silymarin. So that the Kolmogorov-Smirnova test was assessed and the significant difference observed. The ANOVA test assessed for SOD, GSH and GSH-PX enzymes followed by Tukey's test for TAC enzyme that resulted there was a significant difference between UV irradiated and treated by Silymarin group. I.e. Vitamin c increases the anti - oxidant level more than Silymarin. The significant difference in vitamin c anti-oxidant activity level among tested enzymes is TAC. In combination conditions the presence of vitamin c decreased the anti-oxidant activity level more than Silymarin that could be a proof of the scavenging and anti-oxidant activity of vitamin c defused the ROS spices produced by UV. Hence the difference between vitamin c and Silymarin in combination activity may not be the result of the more potency of vitamin c, so more investigations, compare these two anti-oxidants should be done harvesting the more potent anti-aging nutrition. It can be suggested that the comparison of different dosing of Silymarin and alteration in formulations to change the observance may become. (Figure 4 a,b,c,d).

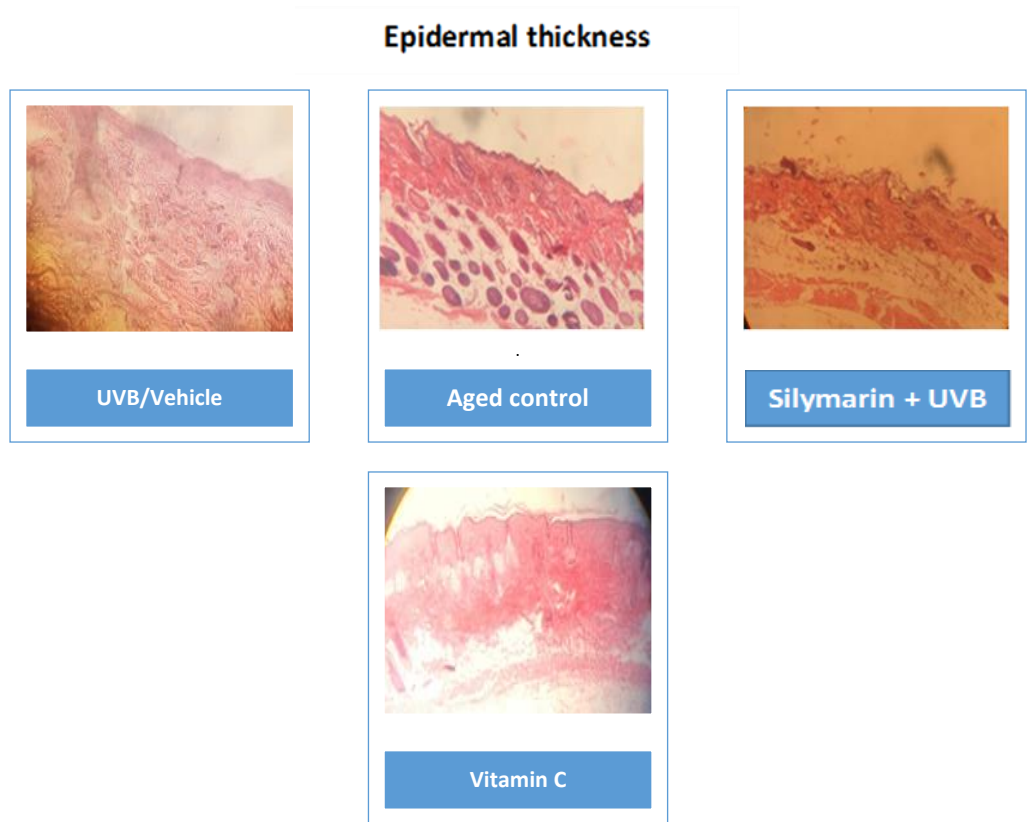

Figure 2a- Skin samples were purchased and stained with H&E as described in Material and methods

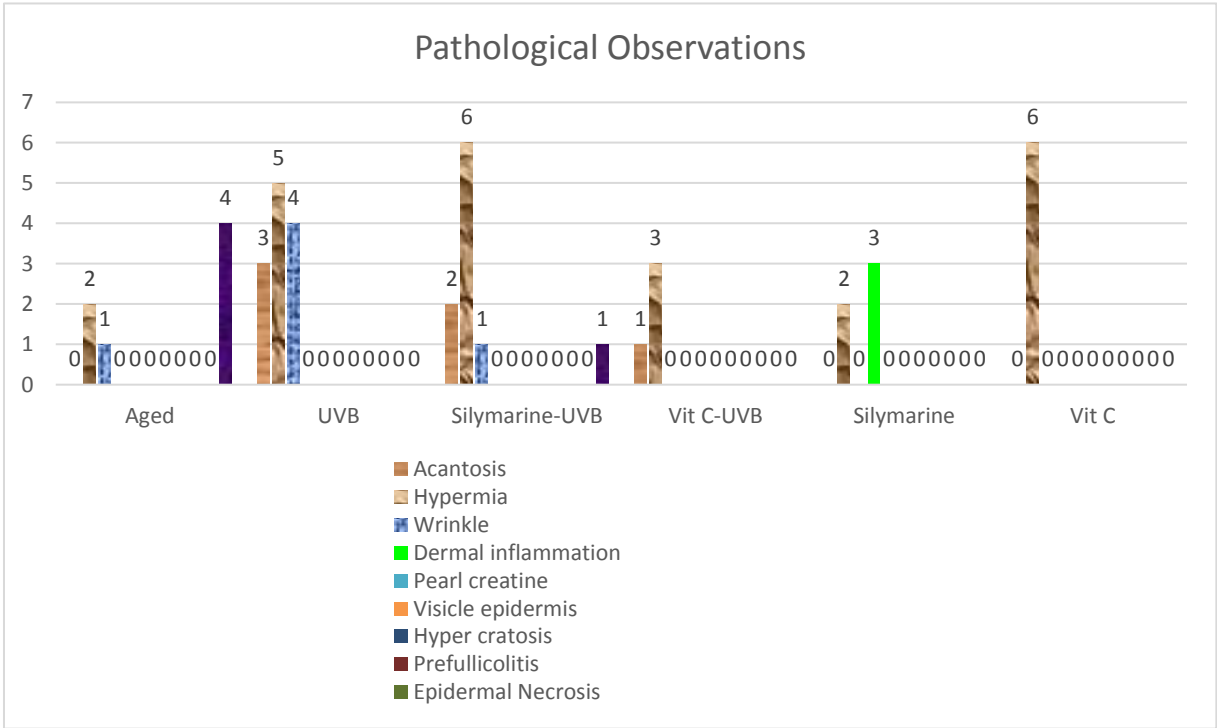


Figure 2b- All the data's of histopathological observations of skin after H&E stain

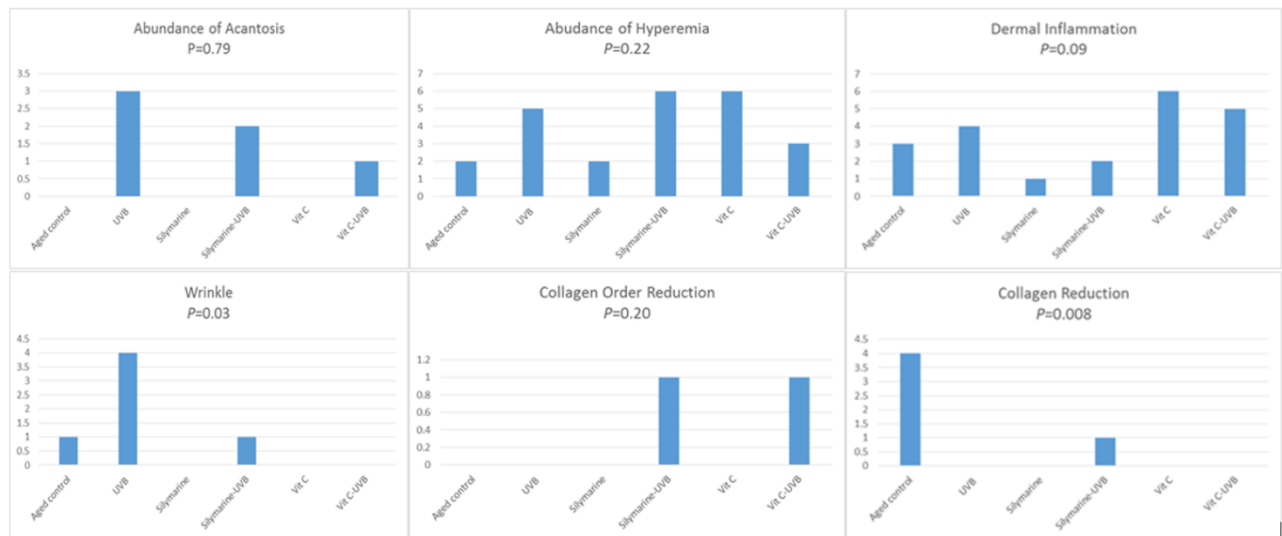


Figure 2c- Comparison of pathological observations demonstrate the significant difference ($P<0.05$) between groups as the effects of UVB radiation in skin aging.

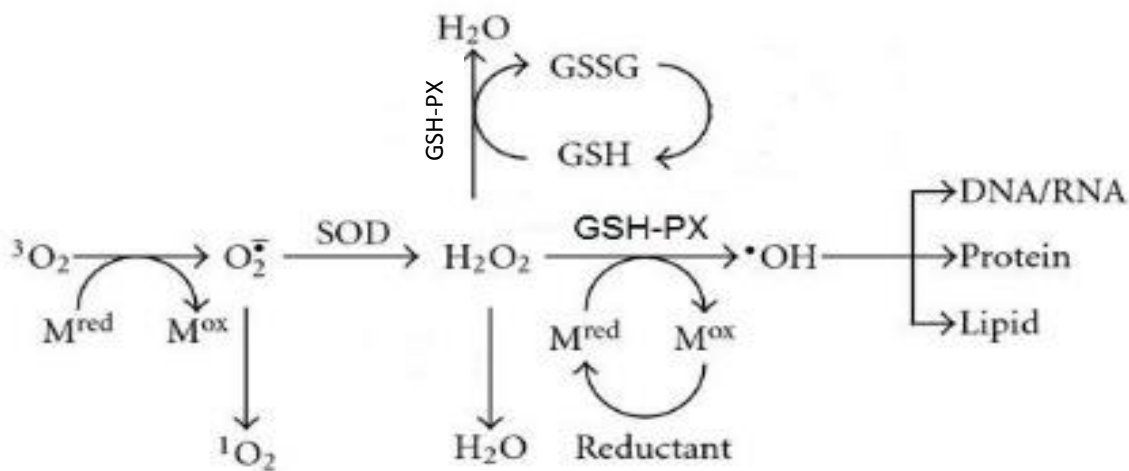


Figure 3- Activation of anti-oxidant enzymes, After induction of ROS by UVB irradiation. M^{ox} : Oxidative materials such as D-galactose, M^{red} : Reductive materials such as Silymarin & Vitamin c

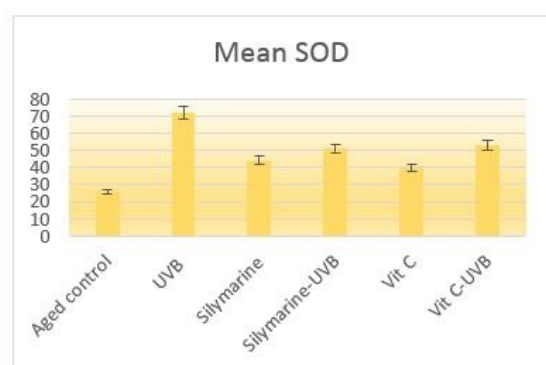


Figure 4a P<0.080

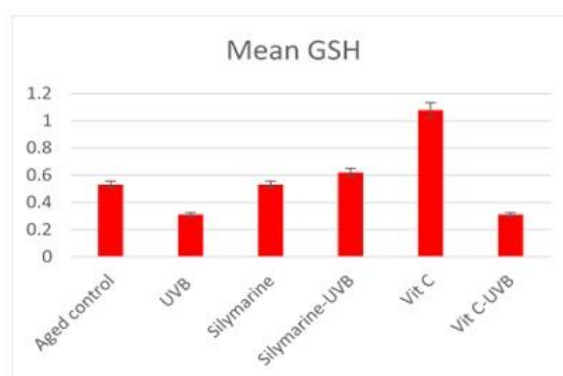


Figure 4b P<0.266

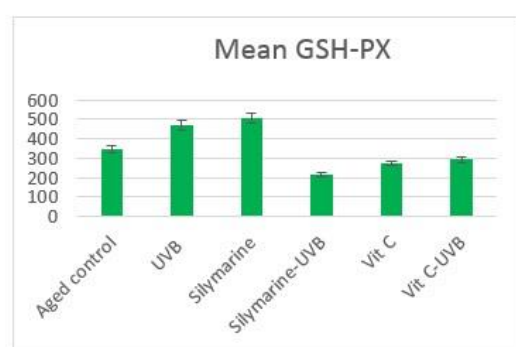


Figure 4c P<0.483

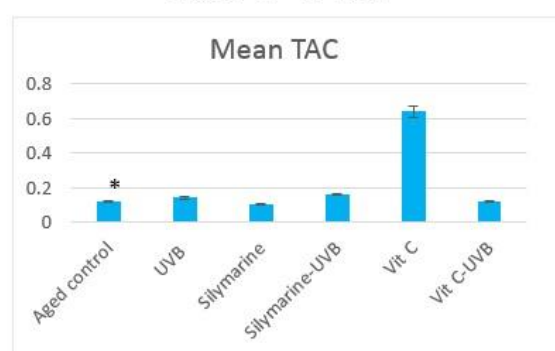


Figure 4d P<0.000

Figure 4- Measurement of mice blood serum Redox index.

Blood serums were detected by reagent kits a: The effects of Silymarin and Vit C on the changes of SOD activity b: The effects of Silymarin and Vit C on the changes of GSH activity c: The effects of Silymarin and Vit C on the changes of GSH-PX activity d: The effects of Silymarin and Vit C on the changes of TAC activity.

TAC values are presented as the mean \pm standard deviation ($n \geq 3$) *P<0.05

In this assay, GPX activity unit was considered as the amount of the sample that will catalyze decomposition of 1 μ mol of GSH to GSSG in one minute.

SOD activity unit was considered as the amount of the sample that will catalyze decomposition 1 μ mol of O_2^- to H_2O_2 and O_2 in one minute.

References

1. Doble K, Ben-Shachar D, Youdim M, Zecca L, Riederer P, Gerlach M. Influence of neuromelanin on oxidative pathways within the human substantia nigra. *Neurotoxicol Teratol.* 2002; 24 (5): 621-8.
2. Jenkins G. Molecular mechanisms of skin ageing. *Mech. Ageing Dev.* 2002; 123 (7): 801-10.
3. Farage MA, Miller KW, Elsner P and Maibach HI. Structural characteristics of the aging skin: a review. *Cutan. Ocul. Toxicol.* 2007; 26 (4): 343-57.
4. Landau M. Exogenous factors in skin aging. *Environmental Factors in Skin Diseases.* 35: Karger Publishers; 2007, p: 1-13.
5. Bernhard D and Wang XJ. Smoking, oxidative stress and cardiovascular diseases-do

- anti-oxidative therapies fail? *CMC*. 2007; 14 (16): 1703-12.
6. Prior RL and Cao G. Medicine. In vivo total antioxidant capacity: comparison of different analytical methods1. *Free Radic. Biol. Med.* 1999; 27 (11-12): 1173-81.
 7. Cao G and Prior RL. Comparison of different analytical methods for assessing total antioxidant capacity of human serum. *Clin Chem.* 1998; 44 (6): 1309-15.
 8. Alfadda AA and Sallam RM. Reactive oxygen species in health and disease. *J. Biomed. Biotechnol.* 2012; 2012.
 9. Meyskens Jr FL and Liu-Smith FJ. Redox-Redux and NADPH Oxidase (NOX): Even More Complicated than We Thought it Might Be. *J. Invest. Dermatol.* 2017; 137 (6): 1208-10.
 10. Poljsak B and Milisav I. The neglected significance of "antioxidative stress". *Oxidative Medicine and Cellular Longevity* 2012; 2012.
 11. Tsantes AE, Bonovas S, Travlou A and Sitaras NM. Redox imbalance, macrocytosis, and RBC homeostasis. *Antioxid Redox Signal.* 2006; 8 (7-8): 1205-16.
 12. Nickel C, Rahlfs S, Deponte M, Koncarevic S and Becker K. Thioredoxin networks in the malarial parasite *Plasmodium falciparum*. *Antioxid. Redox Signal.* 2006; 8 (7-8): 1227-39.
 13. Bodnár E, Bakondi E, Kovács K, Hegedűs C, Lakatos P, Robaszkiewicz A and et al. Redox Profiling Reveals Clear Differences between Molecular Patterns of Wound Fluids from Acute and Chronic Wounds. *Oxidative Medicine and Cellular Longevity* 2018; 2018.
 14. Duteil I, Queille-Roussel C, Rougier A, Richard A and Ortonne JP. Chronic UVA exposure: protective effect on skin induced pigmentation by a daily use of a day care cream containing broad band sunscreen. *Eur. J. Dermatol.* 2002; 12 (4): XVII-XVIII.
 15. Slominski A, Tobin DJ, Shibahara S and Wortsman J. Melanin pigmentation in mammalian skin and its hormonal regulation. *Physiol. Rev.* 2004; 84 (4): 1155-228.
 16. Slominski A, Paus R and Schadendorf D. Melanocytes as "sensory" and regulatory cells in the epidermis. *J. Theor. Biol.* 1993; 164 (1): 103-20.
 17. Meyskens Jr FL, Farmer P and Fruehauf JP. Redox regulation in human melanocytes and melanoma. *Pigment Cell Res.* 2001; 14 (3): 148-54.
 18. Wang A, Marino AR, Gasyna Z, Gasyna E and Norris Jr. Photoprotection by porcine eumelanin against singlet oxygen production. *Photochem. Photobiol.* 2008; 84 (3): 679-82.
 19. Kalka K, Mukhtar H, Turowski-Wanke A and Merk H. Physiology. Biomelanin antioxidants in cosmetics: assessment based on inhibition of lipid peroxidation. *Skin Pharmacol. Appl. Skin Physiol.* 2000; 13 (3-4): 143-9.
 20. Herrling T, Jung K and Fuchs J. Spectroscopy B. The role of melanin as protector against free radicals in skin and its role as free radical indicator in hair. *Spectrochim. Acta A Mol Biomol Spectrosc* 2008; 69 (5): 1429-35.
 21. Mackintosh JA. The antimicrobial properties of melanocytes, melanosomes and melanin and the evolution of black skin. *J. Theor. Biol.* 2001; 211 (2): 101-13.
 22. Fisher GJ, Kang S, Varani J, Bata-Csorgo Z, Wan Y, Datta S and et al. Mechanisms of photoaging and chronological skin aging. *Arch Dermatol.* 2002; 138 (11): 1462-70.
 23. Gilchrest BA. Skin aging and photoaging: an overview. *J. Am. Acad. Dermatol.* 1989; 21 (3): 610-3.

24. Matsumura Y and Ananthaswamy HN. Toxic effects of ultraviolet radiation on the skin. *Toxicol. Appl. Pharmacol.* 2004; 195 (3): 298-308.
25. Elwood JM and Jopson J. Melanoma and sun exposure: an overview of published studies. *Int. J. Cancer* 1997; 73 (2): 198-203.
26. D'Orazio J, Jarrett S, Amaro-Ortiz A and Scott T. UV radiation and the skin. *Int. J. Mol. Sci.* 2013; 14 (6): 12222-48.
27. Mereish KA, Bunner DL, Ragland DR and Creasia DA. Protection against microcystin-LR-induced hepatotoxicity by Silymarin: biochemistry, histopathology, and lethality. *Pharm. Res.* 1991; 8 (2): 273-7.
28. Ahmadi-Ashtiani H, Allameh A, Rastegar H, Soleimani M and Barkhordari E. Inhibition of cyclooxygenase-2 and inducible nitric oxide synthase by silymarin in proliferating mesenchymal stem cells: comparison with glutathione modifiers. *J. Natural Medicines* 2012; 66 (1): 85-94.
29. Wagner H, Diesel P and Seitz M. The chemistry and analysis of silymarin from *Silybum marianum* Gaertn. *Arzneimittelforschung* 1974; 24 (4): 466-71.
30. Wagner H, Horhammer L and Munster R. [On the chemistry of silymarin (silybin), the active principle of the fruits from *Silybum marianum* (L.) Gaertn. (*Carduus marianus* L.)]. *Arzneimittelforschung* 1968; 18 (6): 688-96.
31. Katiyar SK. Silymarin and skin cancer prevention: anti-inflammatory, antioxidant and immunomodulatory effects (Review). *Int. J. Oncol.* 2005; 26 (1): 169-76.
32. Ferenci P, Dragosics B, Dittrich H, Frank H, Benda L, Lochs H and et al. Randomized controlled trial of silymarin treatment in patients with cirrhosis of the liver. *J. Hepatol.* 1989; 9 (1): 105-13.
33. Ahmadi-Ashtiani H, Allameh A, Rastegar H, Soleimani M and Barkhordari E. Inhibition of cyclooxygenase-2 and inducible nitric oxide synthase by silymarin in proliferating mesenchymal stem cells: comparison with glutathione modifiers. *J. Nat. Med.* 2012; 66 (1): 85-94.
34. Ahmadi-Ashtiani H, Rezazadeh Sh, Safipourian K, Afraz K, Khaki A and Rastegar H. Study the effects of oral administration of silymarin in preventing consequences of ethanol on liver during pregnancy. *J. Med. Plants.* 2010; 3 (35): 143-50.
35. Gu M, Dhanalakshmi S, Singh RP and Agarwal R. Dietary feeding of silibinin prevents early biomarkers of UVB radiation-induced carcinogenesis in SKH-1 hairless mouse epidermis. *Cancer Epidemiol. Biomarkers Prev.* 2005; 14 (5): 1344-9.
36. Sies H and Stahl W. Nutritional protection against skin damage from sunlight. *Annu. Rev. Nutr.* 2004; 24: 173-200.
37. Jamshidi AH, Ahmadi-Ashtiani H, Naderi M, Bokaei S and Gholamhouseyni B. Study on effects of topical use of *Silybum marianum* extract (Silymarin) on UV irradiated guinea pig skin. *J. Med. Plants* 2007; 3 (23): 89-96.
38. Chen J, Li Y, Zhu Q, Li T, Lu H, Wei N and et al. Anti-skin-aging effect of epigallocatechin gallate by regulating epidermal growth factor receptor pathway on aging mouse model induced by d-Galactose. *Mech. Ageing. Dev.* 2017; 164: 1-7.
39. Ahmadi-Ashtiani H, Rezazadeh Sh, Barkhordari E, Hekmat-Nazemi N, Baghaei M, Bokaie S and et al. Evaluation of protective

effects of nano-formulated silymarin against UV radiation on guinea pig skin. *J. Med. Plants* 2010; 1 (33): 86-96.

40. Hosseini-Zijoud S-M, Ebadi SA, Goodarzi MT, Hedayati M, Abbasalipourkabir R, Mahjoob MP and et al. Lipid peroxidation and antioxidant status in patients with medullary thyroid carcinoma: A case-control study. *JCDR*. 2016; 10 (2): BC04.

41. Ashrafi M, Karimi B, Sabahi M and Shomali T. Hepatoprotective effect of simvastatin in mice with DMBA-induced breast cancer: Histopathological, biochemical and antioxidant status evaluation. *Biomedical Research and Therapy* 2018; 5 (3): 2064-77.

42. Song JH, Bae EY, Choi G, Hyun JW, Lee MY, Lee HW and et al. Protective effect of mango (*Mangifera indica* L.) against UVB-induced skin aging in hairless mice. *Photodermatol. Photoimmunol. Photomed*. 2013; 29 (2): 84-9.

43. Heck DE, Gerecke DR, Vetrano AM and Laskin JD. Solar ultraviolet radiation as a trigger of cell signal transduction. *Toxicol. Appl. Pharmacol*. 2004; 195 (3): 288-97.

44. Gruhne B, Sompallae R, Marescotti D, Kamranvar SA, Gastaldello S and Masucci MG. The Epstein-Barr virus nuclear antigen-1 promotes genomic instability via induction of reactive oxygen species. *Proc. Natl. Acad. Sci. U.*

S. A. 2009; 106 (7): 2313-8.

45. Kim J-K, Kim Y, Na K-M, Surh Y-J and Kim T-Y. [6]-Gingerol prevents UVB-induced ROS production and COX-2 expression in vitro and in vivo. *Free Radical Res*. 2007; 41 (5): 603-14.

46. Zhen YZ, Lin YJ, Li KJ, Zhang GL, Zhao YF, Wang MM and et al. Effects of rhein lysinate on D-galactose-induced aging mice. *Exp. Ther. Med*. 2016; 11 (1): 303-8.

47. Kim SY, Kim SJ, Lee JY, Kim WG, Park WS, Sim YC and et al. Protective effects of dietary soy isoflavones against UV-induced skin-aging in hairless mouse model. *J. Am. Coll. Nutr*. 2004; 23 (2): 157-62.

48. Sharifi R, Pasalar P, Kamalinejad M, Dehpour AR, Tavangar SM, Paknejad M and et al. The effect of silymarin (*Silybum marianum*) on human skin fibroblasts in an in vitro wound healing model. *Pharm. Biol*. 2013; 51 (3): 298-303.

49. Jin SL and Yin YG. In vivo antioxidant activity of total flavonoids from indocalamus leaves in aging mice caused by D-galactose. *Food Chem. Toxicol*. 2012; 50 (10): 3814-8.

50. Chen J, Li Y, Zhu Q, Li T, Lu H, Wei N and et al. Anti-skin-aging effect of epigallocatechin gallate by regulating epidermal growth factor receptor pathway on aging mouse model induced by d-Galactose. *Mechanisms of Ageing and Development*. 2017; 164: 1-7.