

Antioxidant Properties of *Pistacia khinjuk* Accelerate Healing of the Experimental Achilles Tendon Injury in Rabbits

Fazel H (D.V.M.)¹, Moslemi HR (Ph.D.)^{2*}

1- Fazel Veterinary Clinic, Qom, Iran

2- Department of Clinical Sciences, Faculty of Veterinary Medicine, Semnan University, Semnan, Iran

* Corresponding author: Department of Clinical Sciences, Faculty of Veterinary Medicine, Semnan University, Semnan, Iran

Tel: +98-23-33654214, Fax: +98-23-33654215

E-mail: h.moslemi@semnan.ac.ir

Received: 26 Feb. 2017

Accepted: 25 July 2017

Abstract

Background: Delayed tendon healing and tendon adhesions are still found to be among the complications that occur most often after tendon repair. *Pistacia khinjuk* is one of the three species of *Pistacia* growing in Iran.

Objective: In this study, the role of local injection of ethanolic extract of *P. khinjuk* was evaluated in healing of the experimental Achilles tendon injury in rabbits.

Methods: Nine adult male white New Zealand rabbits were anesthetized and a partial thickness tenotomy was created on both hindlimbs. *P. khinjuk* extract and normal saline were injected daily to the treatment and control groups, respectively for three days post-operatively.

Results: Based on the findings, on days 14, 28 and 42 after the injury, the healing rate in *P. khinjuk* treated groups were higher than control groups in tendon sections significantly ($P \leq 0.05$). In summary, results of this study showed that the application of *P. khinjuk* extract can improve the healing process of damaged Achilles tendon in rabbits.

Conclusion: Significant differences between the treatment and control groups in the current study suggest that the application of *P. khinjuk* extract can improve the healing process of damaged Achilles tendon.

Keywords: *Pistacia khinjuk*, Achilles tendon, Antioxidant, Rabbit

Introduction

Tendons are anatomic structures placed between the muscles and bones, which transmit the created force in the muscles to the bones and make joint movements possible. Damages to these structures affect the natural balance between the stability and mobility, thus altering joint kinematics and ultimately lead to the destruction of the joint [1]. Tendon injuries such as lacerations, ruptures, or tendon inflammation are encountered in both occupational and athletic settings causing disability in millions of people worldwide and cost billions of dollars in health care each year in the United States. Delayed tendon healing and tendon adhesions are still found to be among the complications that occur most often after tendon repair. Following tendon injury, the process of healing or tissue repair starts, which can be largely divided into 3 overlapping phases, inflammatory, repairing and remodeling phases [2-4]. Antioxidants play a key role in the healing process of each phase [5].

The process of inflammation normally leads to the release of biologically active mediators to attract neutrophils, leucocytes and monocytes to the wound area to attack foreign debris and microorganisms through phagocytosis. This process leads to the production of oxygen-free radicals such as hydrogen peroxide, superoxide anion, and hydroxyl anion, which excess of them, causes tissue damage in humans or animals if they overwhelm the natural antioxidant enzymes of the host such as catalase, superoxide dismutase, and glutathione peroxidase. Therefore, antioxidants prevent the activity of the free radicals and thereby prevent

the damage of cells and tissues, provide protection to human and animal subjects, and also enhance healing of infected and non-infected wounds [5, 6].

The genus *Pistacia* belongs to the family Anacardiaceae. Among 15 known species of pistachios, only 3 species grow in Iran, including *P. vera*, *P. khinjuk* and *P. atlantica*. The resin of *P. khinjuk* has been used to treat indigestion, and toothache and as a tonic and astringent in Bakhtiari folk medicine. In addition, fruits of *P. khinjuk* are used as edible wild fruits. This plant is known as Khenjuk or Kelkhong in Persian [7].

Ancient Greek physicians, such as Hippocrates, Dioscorides, Theophrastos and Galenos have recommended the usage of the mastic gum obtained from genus *Pistacia* for gastrointestinal disorders like gastralgia, dyspepsia and peptic ulcer [8, 9]. Some species of *Pistacia* have been used in folk medicine as anti-inflammatory, antipyretic, antibacterial, antiviral and in treatment of diarrhea and throat infections [10-12]. Many studies were carried out on the antioxidant and free radical scavenging activities of the phenolic compounds in genus *Pistacia* [13-17]. This study investigates the healing effects of the local injection of *P. khinjuk* extract on the experimental Achilles tendon injury in rabbits.

Materials and methods

Experiment design

Nine adult male white New Zealand rabbits weighing 2 ± 0.2 Kg were used in this study. Before the beginning of the experiment, rabbits were housed for two weeks at the facility for



acclimatization. The animals were supplied with standard pellet diet and tap water *ad libitum* throughout the experiment. All animals received sufficient care according to “Guide for the Care and Use of Laboratory Animals” published by the National Institute of Health (NIH).

Plant materials and extract preparation

Aerial parts of the plant *P. khinjuk* were purchased from an official herbal drug center. Voucher specimens have been deposited at the Herbarium of the faculty of agricultural science, Islamic Azad University, Garmsar branch, with herbarium number 156. The aerial parts of the plant were dried and grounded into fine powder using an electric blender. The extract was prepared by cold maceration with distilled water for 24 h. Plant powder (50 gr) was suspended at 100 ml ethanol for 24 h at room temperature. The mixture was then filtered using a fine muslin cloth followed by Whatman’s No. 1 filter paper. The extract was concentrated using vacuum distillation [18].

Surgical procedure

Animals were anesthetized through the intramuscular injection of 5% ketamine hydrochloride (35 mg/kg) and 2% xylazine (5 mg/kg). The anesthesia was maintained with inhalation isoflurane. Surgery was performed on both hindlimbs; with left one served as control. A longitudinal skin incision was made over the Achilles tendon, and the paratenon was identified and incised longitudinally as a separate layer. The three bundles of Achilles tendon were identified, and the central bundle

was separated bluntly from the medial and lateral bundles (Fig. 1A). A partial-thickness tenotomy (approximately 50% of tendon bundle width and 1 cm length) was created, beginning at the medial aspect of the bundle and 2 cm proximal to the calcaneus (Fig. 1B). This partial tenotomy allowed the rest of the tendon to act as an internal splint for the non-immobilized repair [19]. 1 ml of *P. khinjuk* extract and normal saline were injected daily to the treatment and control groups respectively for three days post-operatively. After the surgery, rabbits were recovered from the anesthesia in a heated recovery chamber under continuous observation. Following recovery, animals were returned to the individual cages for the rest of the experiment. Flunixin (Razak Co. Iran) as an analgesic (2.5 mg/kg IM) and enrofloxacin as an antibiotic (5 mg/kg, IM) was administrated to the rabbits one hour pre-operatin and continued for three days.

Histopathological studies

On days 14, 28 and 42 post surgery, three rabbits of each group were euthanized using sodium thiopental and Achilles tendon specimens were collected. Specimens were fixed in 10% buffered formalin and transferred to pathology laboratory. The formalin solution was changed after 24 hours and then after 10 days, tissue samples were sectioned, stained with H&E method, and observed with light microscopy. Histopathological samples were scored qualitatively and semi-quantitatively based on Oryan et al scoring system [20].

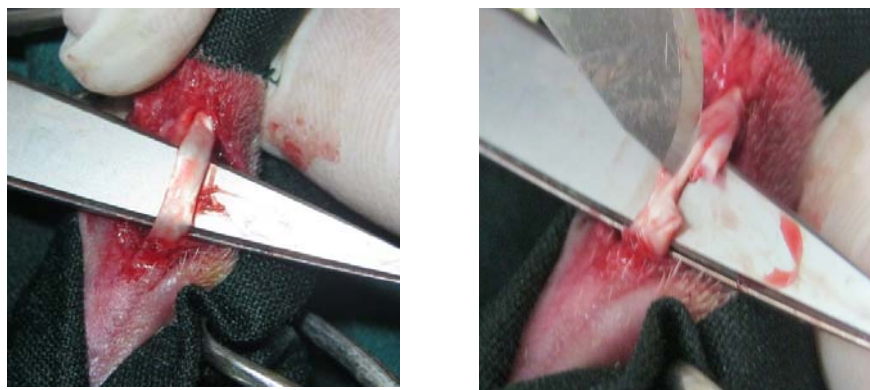

Figure 1- A) Intact Achilles tendon, B) A partial-thickness tenotomy (approx. 50% of tendon bundle width and 1 cm length) was created, beginning at the medial aspect of the bundle and 2 cm proximal to the calcaneus

Statistical analysis

Statistical analysis was performed using SPSS software v16.0 (SPSS Inc, USA) and Mann-Whitney U test. Data were expressed as mean \pm standard deviation (SD). Differences were considered significant when $P < 0.05$.

Results

The average score of the histopathological changes in two groups are shown in Table 1. The histological analysis at days 14, 28 and 42 post-rupture indicated a higher regenerating activity and capacity in the treated groups, than the control group. This was illustrated by fewer inflammatory cells, a larger amount of blood vessels, more fibroblasts, and an increased structural organization with more longitudinally oriented collagen fibers in the treated groups. Injured tendons in both treatment and control groups at 14 days post operation showed the structural organization of the new collagen fibers aligning along with the functional loading axis in a more pronounced

manner in the *P. khinjuk* treated group, which exhibited hypocellular areas of more disorganized collagen, i.e., collagen fibers diverging from the functional axis (Fig. 2A, B). Average healing score in the treatment group was 2; despite 1.33 in control group. The difference was significant ($P \leq 0.05$).

At 28 days, the differences in the structural organization between two groups were even more evident, with an increasing area of highly disorganized collagen, lacking longitudinal orientation in the control group (Fig. 3A), while the *P. khinjuk* treated group exhibited an increasing collagen organization (Fig. 3B).

At day 42, histopathological results showed thick collagen fibers in parallel arrangement in the treatment group. However, the control group showed deposition of thin collagen fibers, high blood vessels and hypercellularity characterized with increased fibroblasts (Fig. 4A, B). Based on the findings at days 28 and 42, the mean healing rate in the treated groups was higher than control groups. The difference was significant statistically ($P \leq 0.05$).

Table 1- The average score of the histopathological changes in the two groups

Day	<i>P. khinjuk</i> extract	Control
14	2	1.33 ±0.57
28	2.33 ±0.57	1.33 ±0.57
42	3	2

Difference was significant ($P \leq 0.05$)

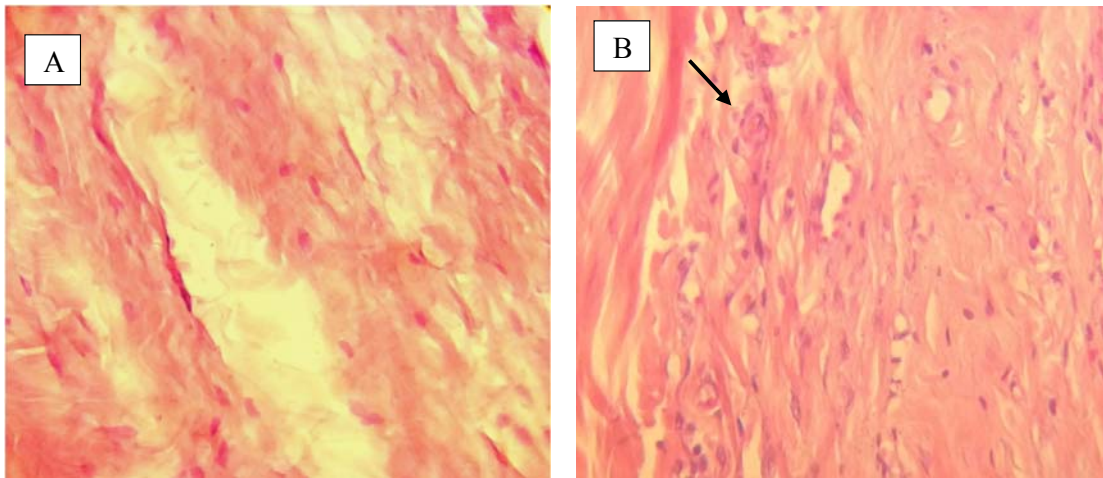


Figure 2- Photomicrograph of the injured tendon in control group (A), and *P. khinjuk* treated group (B) at day 14 post operation. Note less hypercellularity, fewer new blood vessels and better healing process in treated group, (H&E, ×200)

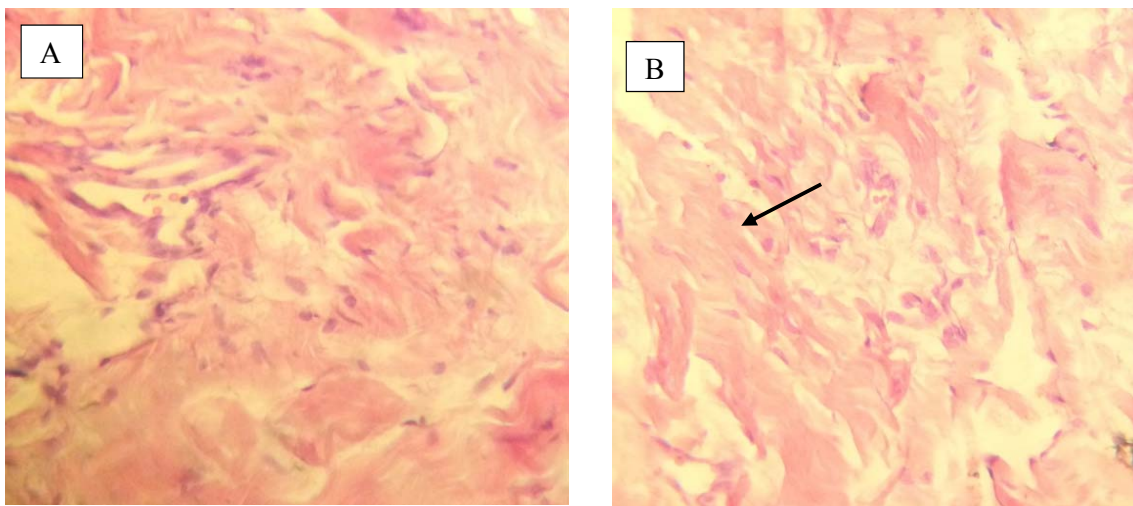


Figure 3- Photomicrograph of the injured tendon in control group (A), and *P. khinjuk* treated group (B) at day 28 post operation. Note less hypercellularity and more mature fibrous connective tissue and better healing process in *P. khinjuk* treated group, (H&E, ×200)

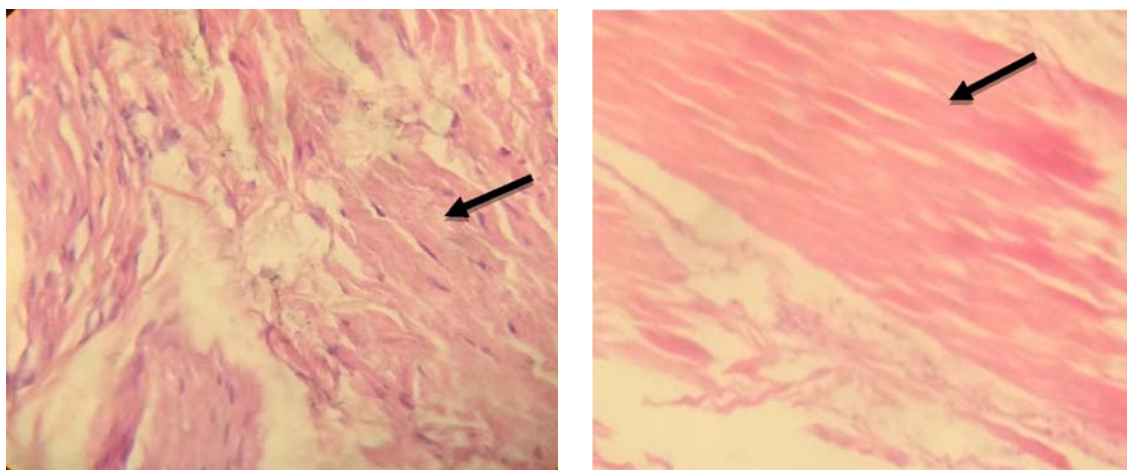


Figure 4- Photomicrograph of the injured tendon in control group (A), and *P. khinjuk* treated group (B) at day 42 post operation. Note thick collagen fibers in parallel arrangement in treatment group. However, the control group showed deposition of thin collagen fibers with blood vessels and hypercellularity, (H&E, ×200)

Discussion

Injuries and degenerative conditions of tendons represent almost 50% of the musculoskeletal injuries treated in orthopaedic clinics [21]. Like other connective tissue repair processes, tendon repair process has been an attractive subject for the researchers for many years. It is well known that increased blood supply enhances the repair process in all kinds of connective tissues [19, 22]. On day 14 after injury, tendon micrographs showed that healing rate in *P. khinjuk* treated group was higher than that of the control group. Furthermore, at Days 28 and 42 after injury, comparison between the *P. khinjuk* treated group and control demonstrated that treatment with the extract increased the healing rate. The differences were significant ($P \leq 0.05$). Healing procedures usually include suppression of inflammation, cell proliferation, and contraction of the collagen tissue, so these processes can be delayed by reactive oxygen species or

microbial infection [23, 24]. Plant-derived antioxidants, such as phenolic acids, flavonols, and flavones, could postpone or prevent the invasion of degenerative diseases because of their redox properties, which permit them to be active as reducing agents, hydrogen donors, hydroxyl radicals (OH), or superoxide radical (O₂) scavengers [25, 26].

Based on the previous studies, the essential oil of *P. khinjuk* was found to have antioxidant and free-radical scavenging activities [27-29]. In recent years, oxidative stress has been implicated in a variety of degenerative processes and diseases; including acute and chronic inflammatory conditions [30]. Tendon injuries have been shown to benefit from antioxidant therapy [31]. Positive correlation has been demonstrated between antioxidant activity and the phenolic content of plant extracts [32]. It has been shown that the Anacardiaceae family is characterized by the occurrence of phenolic compounds, such as

gallic acid and myricetin derivatives [33]. Phenolic compounds in plants have key roles as primary antioxidants, or free radical scavengers [34]. This effect is probably related to the concentration and chemical structures of the phenolic compounds, particularly flavonoids [35]. The abundance of the flavonoid glycosides also was noted in the aerial parts of *P. khinjuk* [36]. Earlier studies showed that flavonoids have a direct role in scavenging ROS, which can counteract lipid oxidation in vitro and improve the body's antioxidant enzyme activity, and decrease peroxide formation in vivo [37]. In 2011, Pirbalouti and Aghaee analyzed the chemical composition of *P. khinjuk* and indicated that the main constituents were phellandrene and α -pinene [29]. Phenolic compounds in this plant have key roles as antibacterial agents, primary antioxidants, or free radical scavengers [38].

Many studies reported that phenolic compounds display antioxidant activity as a result of their redox properties, which can have an important role in absorbing and neutralizing free radicals, quenching singlet and triplet oxygen, and decomposing peroxides [39-41]. Therefore, it is likely that the phenolic constituents present in *P. khinjuk* are responsible for the antioxidant and free radical-scavenging activities.

Conclusion

Significant differences between the treatment and control groups in the current study suggest that positive effects of *P. khinjuk* extract in antioxidant and free-radical scavenging activity affect the tendon healing. These results showed that the application of *P. khinjuk* extract can improve the healing process of damaged Achilles tendon.

References

1. Ferrara N. Role of vascular endothelial growth factor in physiologic and pathologic angiogenesis: therapeutic implications. *Semin. Oncol.* 2002; 29: 10 - 4.
2. Bosch G, Moleman M, Barneveld A, Van Weeren PR and Van Schie HT. The effect of platelet-rich plasma on the neovascularization of surgically created equine superficial digital flexor tendon lesions. *Scand. J. Med. Sci. Sports* 2011; 21: 554 - 61.
3. Kuo YR, Kuo MH, Chou WC, Liu YT, Lutz BS and Jeng SF. One-stage reconstruction of soft tissue and Achilles tendon defects using a composite free anterolateral thigh flap with vascularized fascia lata: clinical experience and functional assessment. *Ann. Plast. Surg.* 2003; 50: 149.
4. Tohidnezhad M, Varoga D, Wruck CJ, Brandenburg LO, Seekamp A, Shakibaei M, sonmez TT, Pufe T and Lippross S. Platelet-released growth factors can accelerate tenocyte proliferation and activate the anti-oxidant response element. *Histochem. Cell. Biol.* 2011; 135: 453 - 60.
5. Martin A. The use of antioxidants in healing. *Dermatol. Surg.* 1996; 22 (2): 156 - 60.
6. Houghton PJ, Hylands PJ, Mensah AY, Hensel A and Deters AM. In vitro tests and ethnopharmacological investigations: wound healing as an example. *J. Ethnopharmacol.* 2005; 100 (1-2): 100 - 107.

7. Behboodi BS. Ecological distribution study of wild pistachios for selection of rootstock. *Options Mediterraneennes* 2003; 63: 61-7.
8. Al Said M, Ageel AM, Parmar NS and Tariq M. Evaluation of Mastic, a crude drug obtained from *Pistacia lentiscus* for gastric and duodenal anti-ulcer activity. *J. Ethnopharmacol.* 1986; 15: 271-78.
9. Paraschos S, Magiatis P, Mitakou S, Petraki K, Kalliaropoulos A, Maragkoudakis P, Mentis A, Sqouras D and Skaltsounis AL. In Vitro and In Vivo Activities of Chios Mastic Gum Extracts and Constituents against *Helicobacter pylori*. *Antimicrob. Agents. Chemother.* 2007; 51: 551-59.
10. Kordali S, Cakir A, Zengin H and Duru ME. Antifungal activities of the leaves of three *Pistacia* species grown in Turkey. *Fitoterapia* 2003; 74: 164 - 67.
11. Villar A, Sanz MJ and Payo M. Hypotensive effect of *Pistacia lentiscus* L. *International. J. Crude. Drug. Res.* 1987; 25: 1-3.
12. Benhammou N, Bekkara FA and Panovska TK. Antioxidant and antimicrobial activities of the *Pistacia lentiscus* and *Pistacia atlantica* extracts. *African. J. Pharmacol.* 2008; 2: 22-8.
13. Hossein Goli A, Barzegar M and Sahari MA. Antioxidant activity and total phenolic compounds of pistachio (*Pistachia vera*) hull extracts. *Food. Chem.* 2005; 92: 521 - 25.
14. Hatamnia AA, Abbaspour N and Darvishzadeh R. Antioxidant activity and phenolic profile of diferent parts of Bene (*Pistacia atlantica* subsp. *kurdica*) fruits. *Food Chem.* 2014; 145: 306 - 11.
15. Hatamnia AA, Rostamzad A, Hosseini M, Abbaspour N, Darvishzadeh R, Malekzadeh P and Aminzadeh BM. Antioxidant capacity and phenolic composition of leaves from ten Bene (*Pistacia atlantica* subsp. *kurdica*) genotypes. *Nat. Prod. Res.* 2016; 30 (50): 600 - 04.
16. Gourine N, Yousf M, Bombarda I, Nadjemi B, Stocker P and Gaydou EM. Antioxidant activities and chemical composition of essential oil of *Pistacia atlantica* from Algeria. *Ind. Crop. Prod.* 2010; 31: 203 - 8.
17. Tomaino A, Martorana M, Arcoraci T, Monteleone D, Giovinazzo C and Saija A. Antioxidant activity and phenolic profile of pistachio (*Pistacia vera* L., variety Bronte) seeds and skins. *Biochimie.* 2010; 92: 1115 - 22.
18. Ezatpour B, Saedi Dezaki E, Mahmoudvand H, Azadpour M, and Ezzatkah F. In Vitro and In Vivo Antileishmanial Effects of *Pistacia khinjuk* against *Leishmania tropica* and *Leishmania major*. *Evid. Based. Complement. Alternat. Med.* 2015; 2015: 1-6.
19. Jahani S, Moslemi HR, Dehghan MM, Sedaghat R, Mazaheri Nezhad R and Rezaee Moghaddam D. The effect of butyric acid with autogenous omental graft on healing of experimental Achilles tendon injury in rabbits. *Iran. J. Vet. Res.* 2015; 16 (1): 100 - 4.
20. Oryan A, Moshiri A and Meimandiparizi AH. Effects of sodium-hyaluronate and glucosamine-chondroitin sulfate on remodeling stage of tenotomized superficial digital flexor tendon in rabbits: a clinical, histopathological, ultrastructural, and biomechanical study. *Connect. Tissue Res.* 2011; 52: 329-39.
21. Schweitzer R, Zelzer E and Volk T. Connecting muscles to tendons: tendons and musculoskeletal development in flies and vertebrates. *Development* 2010; 137: 2807 -17.
22. Sharma P and Maffulli N. Tendon injury and tendinopathy: healing and repair. *J. Bone.*

- Joint. Surg. Am.* 2005; 87: 187 - 202.
- 23.** Houghton P, Hylands P, Mensah A, Hensel A and Deters A. In vitro tests and ethnopharmacological investigations: wound healing as an example. *J. Ethnopharmacol.* 2005; 100: 100 - 7.
- 24.** Velnar T, Bailey T and Smrkolj V. The Wound Healing Process: an Overview of the Cellular and Molecular Mechanisms. *J. Int. Med. Res.* 2009; 37: 1528 - 42.
- 25.** Geethalakshmi R, Sakravarthi C, Kritika T, Arul KM and Sarada DV. Evaluation of antioxidant and wound healing potentials of *Sphaeranthus amaranthoides* Burm.f. *Bio. Med. Res. Int.* 2013; doi: 10.1155/2013/607109.
- 26.** Govindarajan R, Vijayakumar M and Pushpangadan P. Antioxidant approach to disease management and the role of 'Rasayana' herbs of Ayurveda. *J. Ethnopharmacol.* 2005; 99: 165 - 78.
- 27.** Benhammou N, Bekkara FA and Panovska TK. Antioxidant and antimicrobial activities of the *Pistacia lentiscus* and *Pistacia atlantica* extracts. *Afri. J. Pharm. Pharmacol.* 2008; 2: 22 - 8.
- 28.** Gardeli C, Vassiliki P, Athanasios M, Kibouris T and Komaitis M. Essential oil composition of *Pistacia lentiscus* L. and *Myrtus communis* L.: evaluation of antioxidant capacity of methanolic extracts. *Food Chem.* 2008; 107: 1120 - 30.
- 29.** Pirbalouti AG and Aghaee K. Chemical composition of essential oil of *Pistacia khinjuk* stocks grown in Bakhtiari Zagross Mountains, Iran. *Elect. J. Biol.* 2011; 7: 67 - 9.
- 30.** Yusufoglu HS and Alqasoumi SI. Anti-inflammatory and wound healing activities of herbal gel containing an antioxidant *Tamarix aphylla* leaf extract. *Int. J. Pharmacol.* 2011; 7 (8): 829 - 35.
- 31.** Park HB, Hah YS, Yang JW, Nam JB, Cho SH and Jeong ST. Antiapoptotic effects of anthocyanins on rotator cuff tenofibroblasts. *J. Orthop. Res.* 2010; 28: 1162 - 69.
- 32.** Elzaawely AA and Tawata S. Antioxidant activity of phenolic rich fraction obtained from *Convolvulus arvensis* L. leaves grown in Egypt. *Asian. J. Crop. Sci.* 2012; 4 (1): 32 - 40.
- 33.** Umadevi I, Daniel M and Sabnis S. Chemotaxonomic studies on some members of Anacardiaceae. Proceedings: *Plant. Sci.* 1988; 98: 205 - 8.
- 34.** Rahnema M, Najimi M and Ali S. Antibacterial effects of *Myristica fragrans*, *Zataria multiflora* Boiss, *Syzygium aromaticum*, and *Zingiber officinale* Rosci essential oils, alone and in combination with nisin on *Listeria monocytogenes*. *Comp. Clin. Path.* 2012; 21 (6): 1313 - 16.
- 35.** Pietta PG. Flavonoids as antioxidants. *J. Nat. Prod.* 2000; 63: 1035 - 42.
- 36.** Kawashty S, Mosharrafa S, El-Gibali M and Saleh N. The flavonoids of four *Pistacia* species in Egypt. *Biochem. Sys. Eco.* 2000; 28: 915 - 7.
- 37.** Nakao K, Murata K, Itoh K, Hanamoto Y, Masuda M, Moriyama K, Shintani T and Matsuda H. Anti-hyperuricemia effects of extracts of immature *Citrus unshiu* fruit. *J. Traditional Medicines* 2011; 28 (1): 10 - 5.
- 38.** Rahnema M, Najimi M and Ali S. Antibacterial effects of *Myristica fragrans*, *Zataria multiflora* Boiss, *Syzygium aromaticum*, and *Zingiber officinale* Rosci essential oils, alone and in combination with

nisin on *Listeria monocytogenes*. *Comp. Clin. Pathol.* 2012; 21 (6): 1313 - 16.

39. Braca A, Fico G, Morelli I, Simone F, Tom F and De Tommasi N. Antioxidant and free radical scavenging activity of flavonol glycosides from different *Aconitum* species. *J. Ethnopharmacol.* 2003; 86 (1): 63 - 7.

40. Seyoum A, Asres K and El-Fiky FK. Structure-radical scavenging activity

relationships of flavonoids. *Phytochem.* 2006; 67: 2058 - 70.

41. Qingming Y, Xianhui P, Weibao K, Hong Y, Yidan S, Li Z, Yanan Z, Yuling Y, Lan D, Guoan L. Antioxidant activities of malt extract from barley (*Hordeum vulgare* L.) toward various oxidative stress in vitro and in vivo. *Food. Chem.* 2010; 118: 84 - 9.